

高雄榮民總醫院

甲狀腺癌臨床診療指引

2018 年第一版

癌症中心甲狀腺癌醫療團隊擬定

2018 年第一版為參考美國癌症聯合委員會於 2017 年 5 月出版之甲狀腺癌臨床指引、2015 年美國甲狀腺協會治療指引及其他參考文獻，於 2016.02.25 由甲狀腺癌團隊相關人員劉絮穎、梁宗榮、余筠瑩、朱志勳、孫群欽、彭南靖、邱宇莉、李恒昇、傅婷瑛、傅瑞勛、許碩修、張國楨、余明生等討論後共同修訂。

注意事項：這個診療準則主要作為醫師和其他保健專家診療癌症病人參考之用。

假如你是一個癌症病人，直接引用這個研究資訊及診療準則並不恰當。

只有你的醫師才能決定給你最恰當的治療。

Summary of the Guidelines Updates (與上一版差異)

1. 術後放射線碘治療:

RAI selectively recommended: 30-100 mCi 修改為 30-150 mCi

2. 文字更正:

p9 Tc99m & Tc 99m 修改為 Tc-99m

p9 Consider (EBRT/IMRT) 修改為 Consider EBRT/IMRT

p10 ATA risk stratification system with Proposed Modifications 修改為 proposed modifications

p10 If 131-I is given 修改為 If 131I is given

3. 增加 Metastasis 第一線治療

4. 使用 *標註與期別相關之主要檢查

目錄

P. 03	<u>甲狀腺結節評估</u>
P. 04-05	<u>甲狀腺細胞病理學報告</u>
P. 06	<u>乳突瘤</u>
P. 07	<u>單葉切除術後發現之乳突瘤</u>
P. 08	<u>濾泡瘤</u>
P. 09	<u>術後評估與治療</u>
P. 10	<u>美國甲狀腺協會危險分層系統</u>
P. 11	<u>促甲狀腺激素抑制原則</u>
P. 12	<u>術後放射線碘治療 (Initial Postoperative RAI therapy)</u>
P. 13	<u>放射線治療</u>
P. 14	<u>追蹤</u>
P. 15	<u>復發</u>
P. 16	<u>髓質癌</u>
P. 17-18	<u>分化不良癌</u>
P. 19	<u>化學治療 & 標靶治療處方</u>
P. 20-21	<u>參考資料</u>

甲狀腺結節評估 - 超音波特徵

<u>Threshold for FNA</u>		
Solid nodule		
• With suspicious sonographic features ¹	≥ 1.0 cm	Yes → FNA
• Without suspicious sonographic features	≥ 1.5 cm	
Mixed cystic-solid nodule		
• With suspicious sonographic features ¹	Solid component >1 cm	No → Observe
• Without suspicious sonographic features	Solid component >1.5 cm	
Spongiform nodule ²	≥ 2.0 cm	
Suspicious cervical lymph node ^{3, 4}	FNA node ± FNA-associated thyroid nodule(s)	

¹Suspicious sonographic features: Hypoechoic, microcalcifications, infiltrative margins, and taller than wide in transverse plane. Sonographic features associated with a low risk of malignancy including spongiform nodules, isoechoic or hyperechoic solid nodules, and mixed solid-cystic nodules without any of the suspicious features listed above.

²Aggregation of multiple microcystic components in more than 50% of the volume of the nodule.

³Tg washout may be helpful in diagnosis of lymph node metastases.

⁴Suspicious lymph node features may include hypoechoic, rounded, absence of fatty hilum, cystic or partially cystic, and/or microcalcifications.

甲狀腺細胞病理學報告

Benign form 良性的格式	
1. Nondiagnostic	
	<i>Specimen processed and examined, but nondiagnostic due to insufficient cellularity.</i>
2. Benign	
	<i>Presence of some benign-appearing follicular cells</i>
3. BENIGN.	
	<i>Consistent with lymphocytic (Hashimoto's) thyroiditis. Numerous polymorphic lymphoid cells and scattered follicular cells. Lymphocytic (Hashimoto's) thyroiditis is considered. Suggest clinical correlation.</i>
Atypia 不確定的格式	
4. Atypia of Undetermined Significance, favor reactive	
	<i>Presence of groups of proliferative benign-looking follicular cells. Suggest follow-up and repeat FNA cytology in the next visit.</i>
5. Atypia of Undetermined Significance, neoplasm cannot be excluded	
	<i>Presence of groups/sheets of proliferating follicular cells with obvious nucleoli/ with focal papillary arrangement, the possibility of malignancy cannot be excluded totally. Suggest further evaluation and either repeat FNA cytology 3 months later or do biopsy if clinically indicated.</i>
Suspicious for a Follicular Neoplasm. 針對濾泡型腫瘤	
6. Suspicious for a Follicular Neoplasm.	
	<i>Cellular aspirate of follicular cells with a predominantly microfollicular architecture, scattered isolated cells, and scant colloid.</i>

Suspicious for malignancy 疑似惡性	
7.	Suspicious for malignancy
	<i>Presence of some sheets of proliferating follicular cells, of which some having intranuclear pseudoinclusions. Suspicious for papillary carcinoma. Presence of some atypical follicular cells with obvious nucleoli and a few pseudo-inclusion nuclei, of which the possibility of papillary carcinoma should be considered. Suggest further evaluation and do biopsy.</i>
8.	Suspicious for malignancy, particularly medullary carcinoma cannot be excluded.
	<i>Presence of some small groups of small hyperchromatic cells, of which the possibility of malignancy, particularly medullary carcinoma cannot be excluded. Suggest do biopsy if clinically indicated.</i>
Malignant 確定惡性	
9.	Positive for malignant cells.
	<i>The sections show groups of atypical follicular cells with obvious pseudo-inclusions, which is consistent with papillary carcinoma.</i>

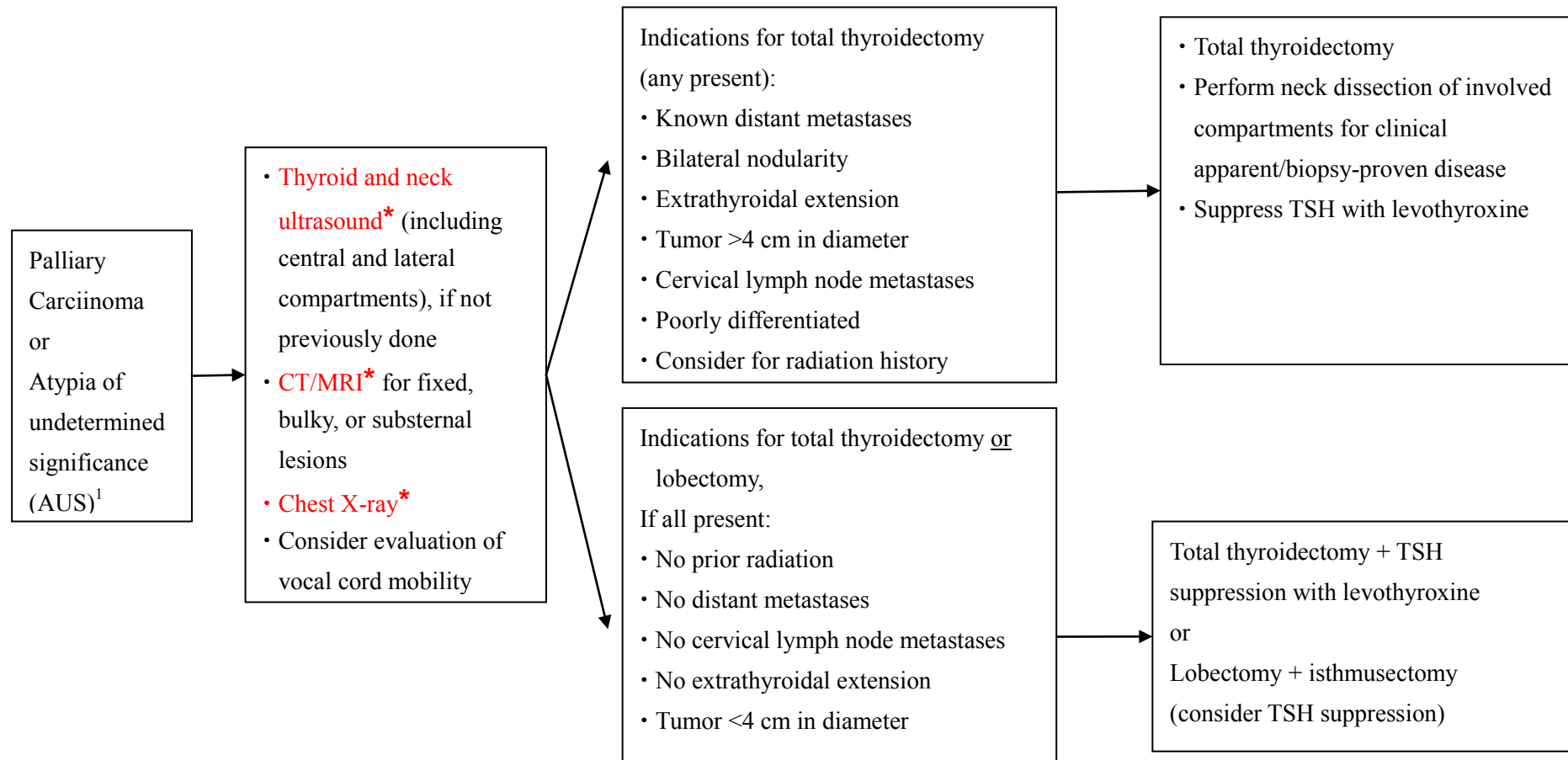
乳突癌 (Papillary Carcinoma)

細針抽吸結果

評估

手術方式考量

治療



¹AUS with high clinical suspicion of malignancy may consider lobectomy or total thyroidectomy for definitive diagnosis/treatment.

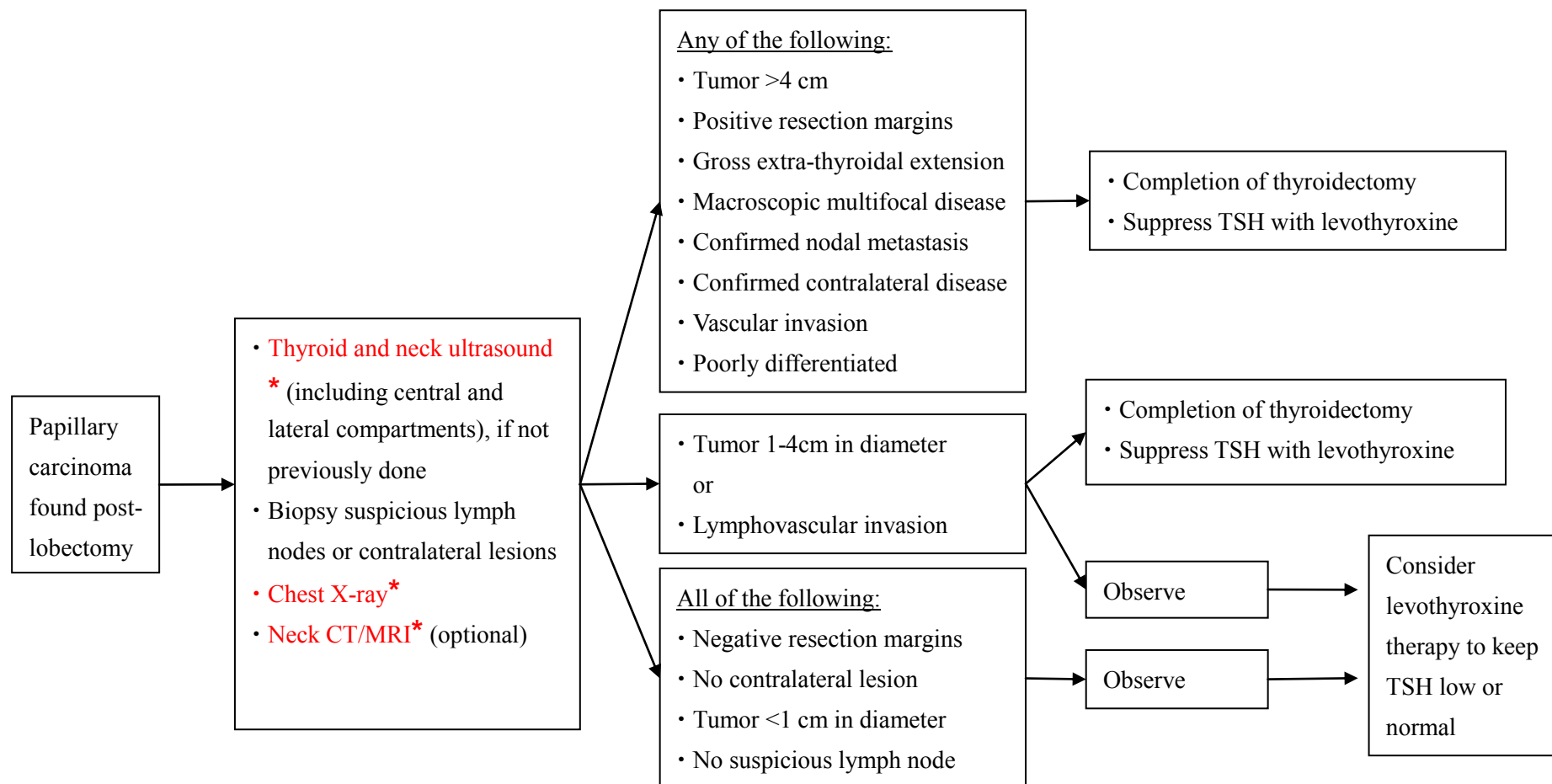
²*與期別相關之主要檢查

單葉切除術後發現之乳突癌(Papillary carcinoma found post-lobectomy)

臨床表現

評估

治療



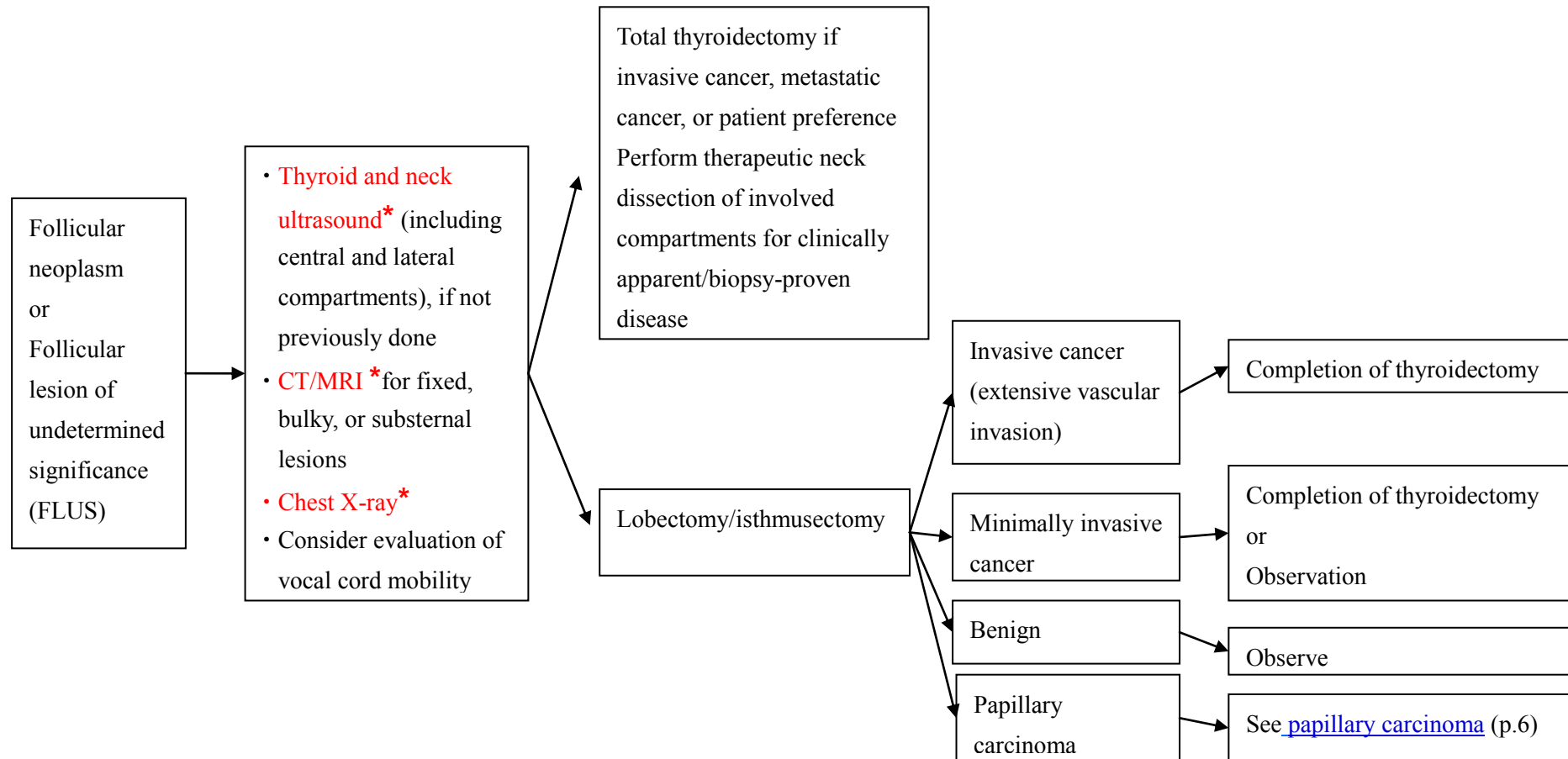
¹*與期別相關之主要檢查

濾泡癌(Follicular Carcinoma)

細針抽吸結果

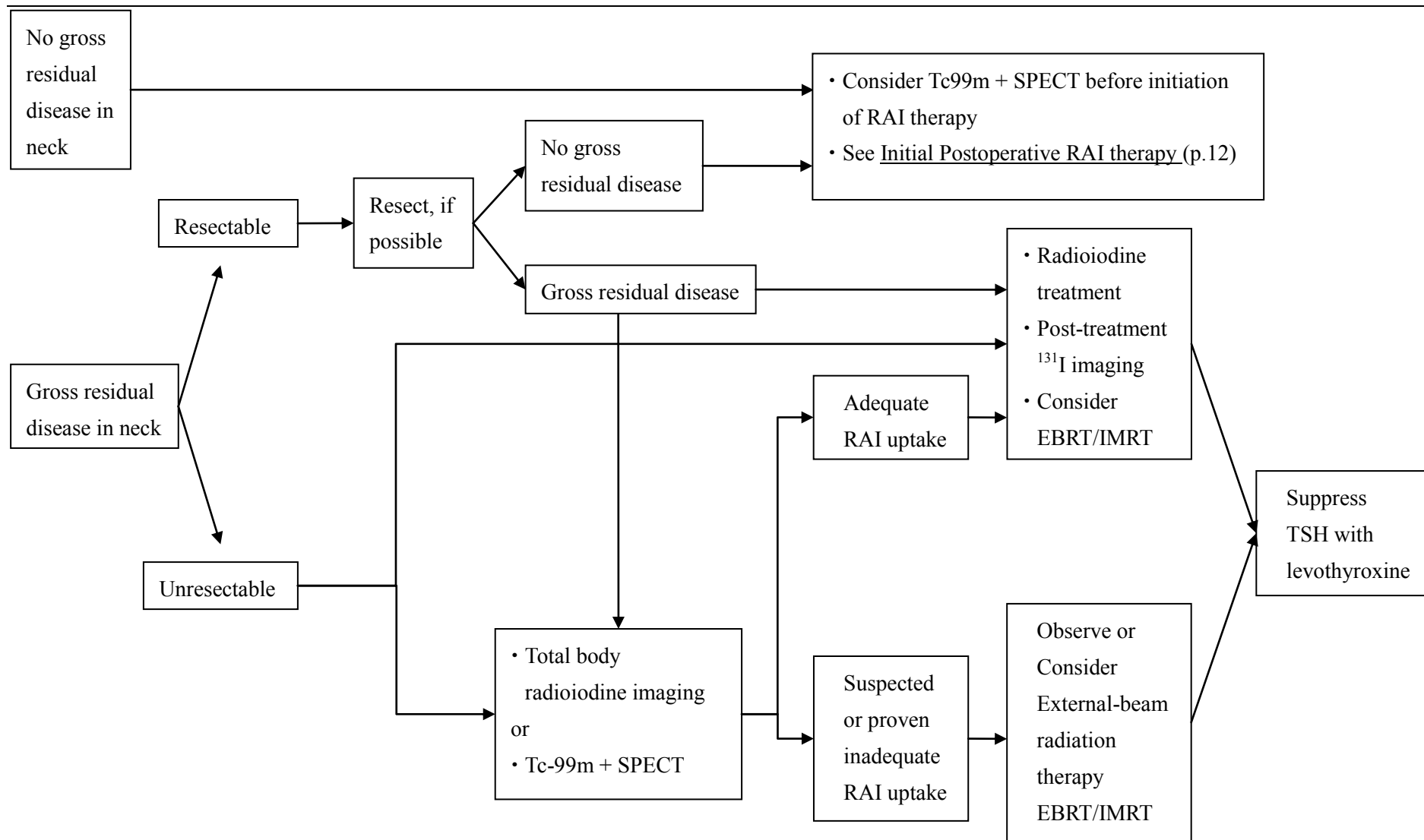
評估

治療



¹*與期別相關之主要檢查

術後評估與治療(Postsurgical Evaluation & Treatment)



美國甲狀腺協會危險分層系統(ATA risk stratification system with proposed modifications)

<p style="text-align: center;">低風險 Low risk</p>	<p>Papillary thyroid cancer (with all of the following):</p> <ul style="list-style-type: none"> • No local or distant metastases; • All macroscopic tumor has been resected • No tumor invasion of loco-regional tissues or structures • The tumor does not have aggressive histology (e.g., tall cell, hobnail variant, columnar cell carcinoma) • If ¹³¹I is given, there are no RAI-avid metastatic foci outside the thyroid bed on the first posttreatment whole-body RAI scan • No vascular invasion • Clinical N0 or ≤5 pathologic N1 micrometastases (<0.2 cm in largest dimension)^a <p>Intrathyroidal, encapsulated follicular variant of papillary thyroid cancer^a</p> <p>Intrathyroidal, well differentiated follicular thyroid cancer with capsular invasion and no or minimal (<4 foci) vascular invasion^a</p> <p>Intrathyroidal, papillary microcarcinoma, unifocal or multifocal, including BRAF^{V600E} mutated (if known)^a</p>
<p style="text-align: center;">中度風險 Intermediate risk</p>	<p>Microscopic invasion of tumor into the perithyroidal soft tissues</p> <p>RAI-avid metastatic foci in the neck on the first posttreatment whole-body RAI scan</p> <p>Aggressive histology (e.g., tall cell, hobnail variant, columnar cell carcinoma)</p> <p>Papillary thyroid cancer with vascular invasion</p> <p>Clinical N1 or >5 pathologic N1 with all involved lymph nodes <3 cm in largest dimension^a</p> <p>Multifocal papillary microcarcinoma with ETE and BRAF^{V600E} mutated (if known)^a</p>
<p style="text-align: center;">高風險 High risk</p>	<p>Macroscopic invasion of tumor into the perithyroidal soft tissues (gross ETE) 腫瘤沒有完整切除</p> <p>Incomplete tumor resection</p> <p>Distant metastases</p> <p>Postoperative serum thyroglobulin suggestive of distant metastases</p> <p>Pathologic N1 with any metastatic lymph node ≥3 cm in largest dimension^a</p> <p>Follicular thyroid cancer with extensive vascular invasion (> 4 foci of vascular invasion)^a</p> <div style="border: 1px solid black; padding: 5px; margin-top: 10px;"> <p>^aProposed modifications, not present in the original 2009 initial risk stratification system</p> </div>

促甲狀腺激素抑制原則[Principles of Thyroid-Stimulating Hormone (TSH) Suppression]

- Because TSH is a trophic hormone that can stimulate the growth of cells derived from thyroid follicular epithelium, the use of levothyroxine to maintain low TSH levels is considered optimal in treatment of patients with papillary, follicular, or Hurthle cell carcinoma. However, data are lacking to permit precise specification of the appropriate serum levels of TSH.
- Given the potential toxicities associated with TSH-suppressive doses of levothyroxine—including cardiac tachyarrhythmias (especially in the elderly) and bone demineralization (particularly in post-menopausal women) as well as frank symptoms of thyrotoxicosis—the risk and benefit of TSH-suppressive therapy must be balanced for each individual patient.
- Patients whose TSH levels are chronically suppressed should be counseled to ensure adequate daily intake of calcium and vitamin D.

術後放射線碘治療 (Initial Postoperative RAI therapy)

Papillary Carcinoma

RAI not typically recommended (if all present) :

- Classic papillary thyroid carcinoma (PTC)
- Primary tumor < 2 cm
- Intrathyroidal
- Unifocal or multifocal

RAI selectively recommended (if any present):

- Primary tumor 2-4cm
- High-risk histology
- Lymphovascular invasion
- Cervical lymph node metastases
- Macroscopic multifocality (one focus >1 cm)

RAI typically recommended (if any present):

- Gross extrathyroidal extension
- Primary tumor >4 cm
- Known or suspected distant metastases at presentation (if amenable to RAI)

Follicular carcinoma

RAI not typically recommended (if all present) :

- Primary tumor <2 cm
- Intrathyroidal
- No vascular invasion
- Clinical N0

RAI selectively recommended (if any present):

- Primary tumor 2-4cm
- Minor vascular invasion
- Cervical lymph node metastases

RAI typically recommended (if any present):

- Gross extrathyroidal extension
- Primary tumor >4 cm
- Extensive vascular invasion
- Known or suspected distant metastases at presentation (if amenable to RAI)

Recommended Dosage :

- RAI not typically recommended: 0-30 mCi
- RAI selectively recommended: 30-150 mCi
- RAI typically recommended: 100-200 mCi

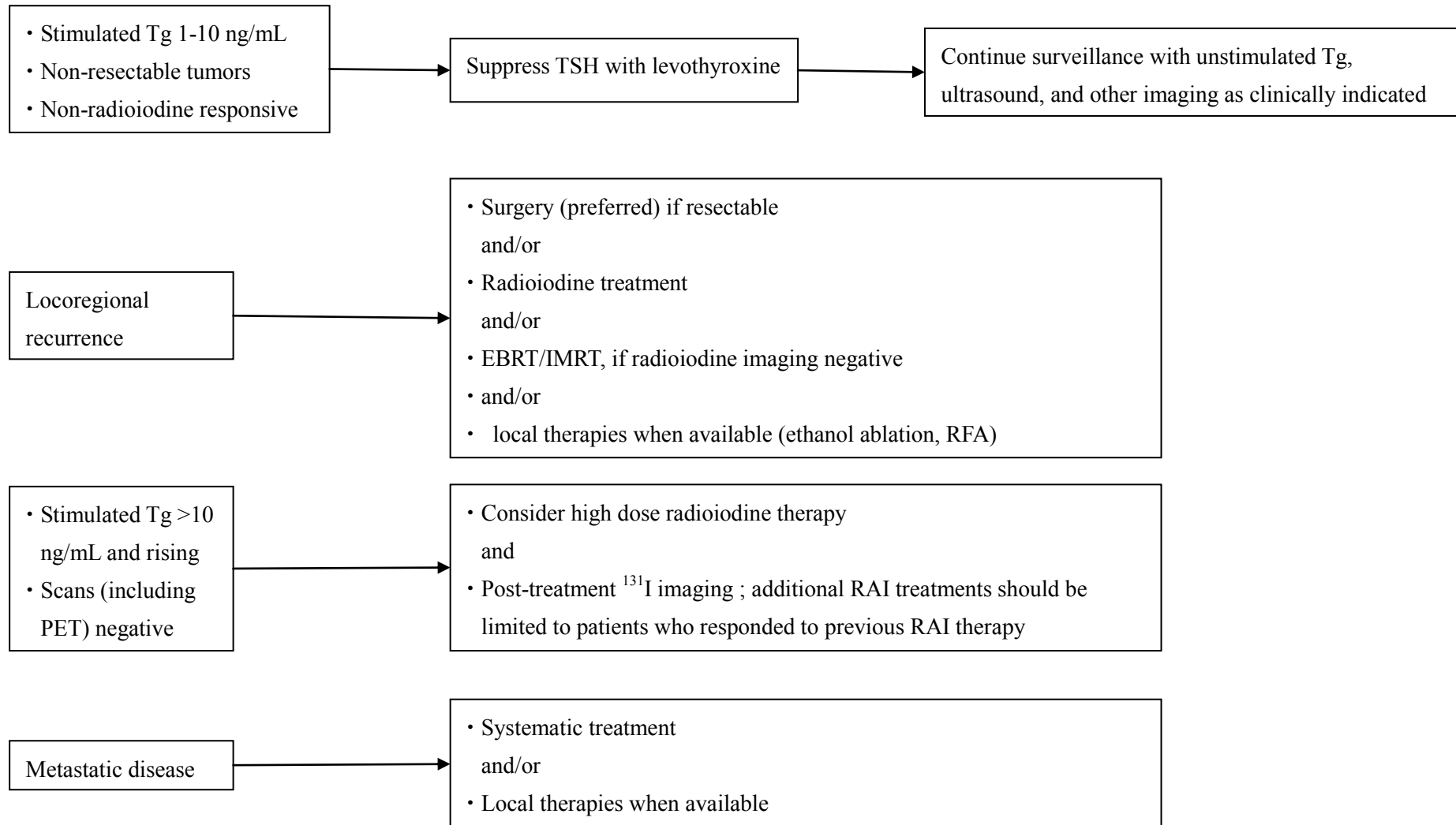
放射線治療 (External Beam Radiation Therapy/Intensity Modulated Radiation Therapy)

- There is no major prospective, randomized trials in external beam radiotherapy but some retrospective studies showed beneficial in local control or cancer-specific survival.
- Indication of considering R/T
 - gross residual tumor/unresectable tumor, esp in no/poor RAI uptake tumor
 - extrathyroidal extension or extranodal extension.
- Dosage:
 - low-risk : 54 Gy,
 - microscopic disease: 59.4–63 Gy,
 - positive margins: 63–66 Gy,
 - macroscopic disease: 66–70 Gy.

追蹤

- Physical examination, TSH and Tg measurement + antithyroglobulin antibodies
- Neck ultrasound every 6-12 months
- Chest X-ray every 6-12 months
- For patients underwent total thyroidectomy and postoperative RAI therapy, consider radioiodine imaging in the first year postoperatively
- Consider TSH-stimulated radioiodine imaging in high-risk patients, patients with previous RAI-avid metastases, or patients with abnormal Tg levels (either TSH-suppressed or TSH-stimulated), rising antithyroglobulin antibodies, or abnormal ultrasound during surveillance.
- Consider FDG-PET/CT for patients with abnormal Tg level but negative ^{131}I imaging.

復發 (Recurrent Disease)

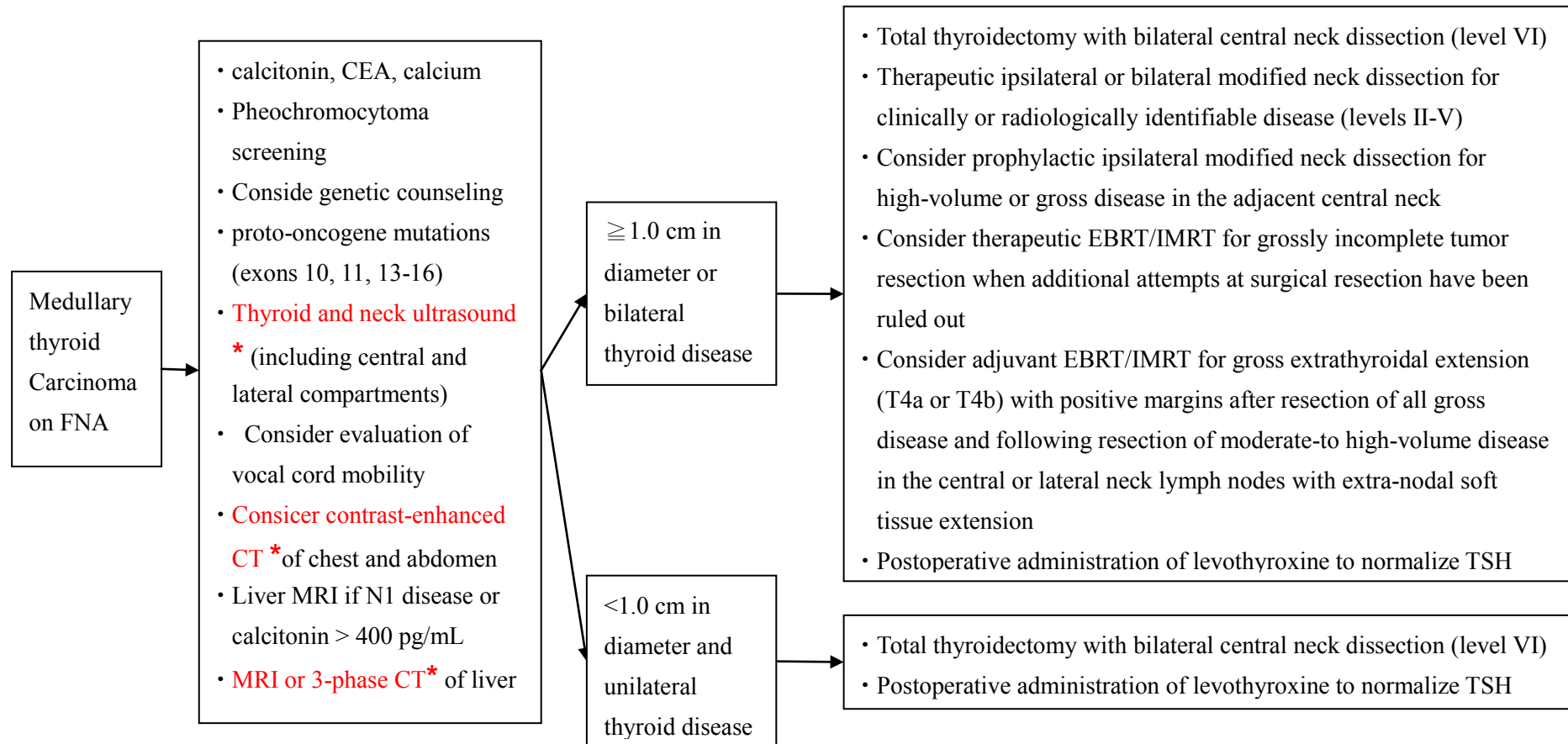


髓質癌 (Medullary Carcinoma)

細針抽吸結果

評估

治療



¹*與期別相關之主要檢查

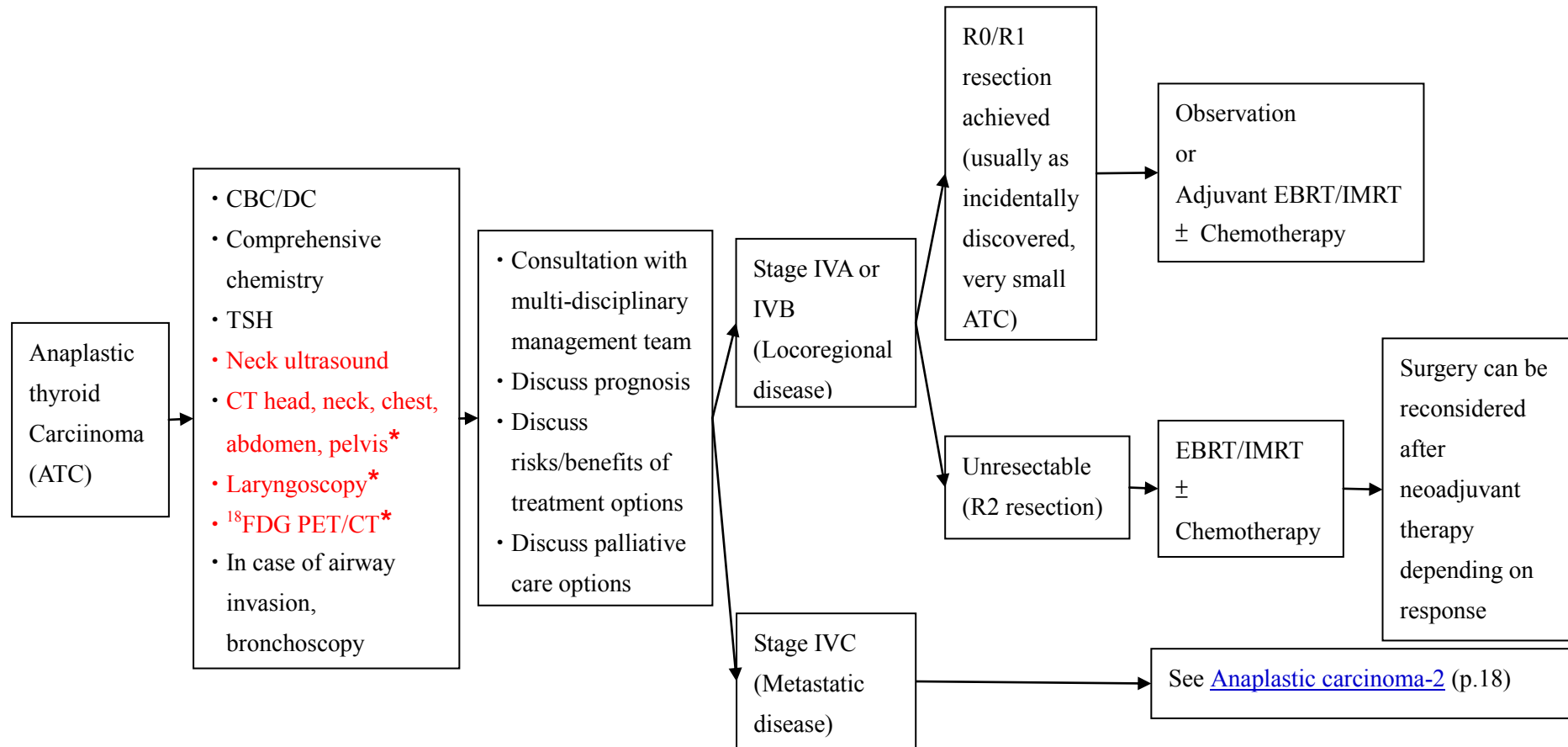
分化不良癌 (Anaplastic Carcinoma) -1

細針抽吸結果

評估

建立治療目標

依期別治療



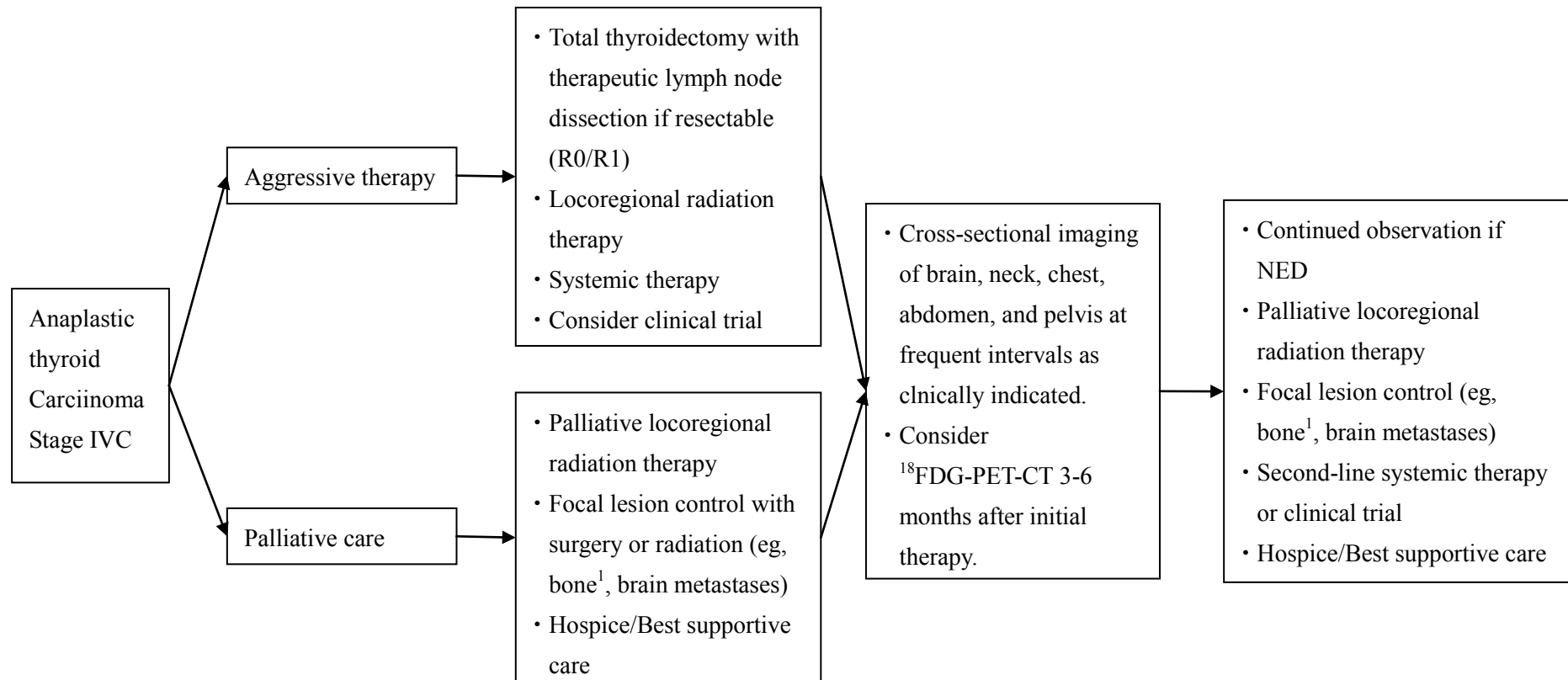
¹*與期別相關之主要檢查

分化不良癌 (Anaplastic Carcinoma) -2

轉移性疾病

治療

追蹤 & 處置



¹Consider use of intravenous bisphosphonates or denosumab. Denosumab and intravenous bisphosphonates can be associated with severe hypocalcemia; patients with hypoparathyroidism and vitamin D deficiency are at increase risk.

Metastasis 第一線治療

1. RAI therapy

2. 標靶治療處方 (Kinase Inhibitor Therapy or metastasis)

Regimen	Agents/Dosages	Frequency
Sorafenib (Nexavar)	400mg Oral	Twice daily (BID)

3. 化學治療處方 (Chemotherapy Regimen or metastasis)

Regimen	Agents/Dosages	Frequency
Paclitaxel (weekly)	60-90 mg/m ² IV	Weekly
Paclitaxel (triweekly)	135-200 mg/m ² IV	Every 3-4 weeks
Doxorubicin (weekly)	20 mg/ m ² IV	Weekly
Doxorubicin (triweekly)	60-75 mg/ m ² IV	Every 3 weeks

參考資料(Reference)

1. NCCN Clinical Practice Guideline in Oncology, Thyroid Carcinoma, Version 5.2017
2. 2015 American Thyroid Association Management Guidelines for Adult Patients with Thyroid Nodules and Differentiated Thyroid Cancer
3. Cibas ES, Ali SZ 2009 The Bethesda System For Reporting Thyroid Cytopathology. *Am J Clin Pathol* 132:658–665.
4. Edge SB, Byrd DR, Compton CC, Fritz AG, Greene FL, Trotti A (eds) *AJCC Cancer Staging Manual*. 7th edition. Springer-Verlag, New York, pp 59–64.
5. Pacini F, Castagna MG, Brilli L, Pentheroudakis G; ESMO Guidelines Working Group. Thyroid cancer: ESMO Clinical Practice Guidelines for diagnosis, treatment and follow-up. *Ann Oncol*. 2012 Oct;23 Suppl 7:vii110-9..
6. Matuszczyk A, Petersenn S, Bockisch A, et al. Chemotherapy with doxorubicin in progressive medullary and thyroid carcinoma of the follicular epithelium. *Horm metab Res*. 2008; 40(3):210
7. Higashiyama T, Ito Y, Hirokawa M, et al. Induction chemotherapy with weekly paclitaxel administration for anaplastic thyroid carcinoma. *Thyroid* 2010;20:7-14.
8. Brose MS, Nutting CM, Jarzab B, et al. Sorafenib in radioactive iodine-refractory, locally advanced or metastatic differentiated thyroid cancer: a randomised, double-blind, phase 3 trial. *Lancet* 2014 Jul 26;384(9940):319-28
9. Brierley J, Tsang R, Panzarella T, et al. Prognostic factors and the effect of treatment with radioactive iodine and external beam radiation on patients with differentiated thyroid cancer seen at a single institution over 40 years. *Clin Endocrinol (Oxf)* 2005;63(4):418-427.
10. Chen J, Tward J, Shrieve DC, et al. Surgery and radiotherapy improves survival in patients with anaplastic thyroid carcinoma: analysis of the surveillance, epidemiology, and end results 1983-2002. *Am J Clin Oncol* 2008: 460-464.
11. Chow SM, Law SCK, Mendenhall WM, et al. Papillary thyroid carcinoma: prognostic factors and the role of radioiodine and external radiotherapy. *IJROBP* 2002;52(3):784-795.
12. Foote RL, Brown PD, Garces YI, et al. Is there a role for radiation therapy in the management of Hurthle cell carcinoma? *Int J Radiat Oncol Biol Phys* 2003;56(4):1067-1072.
13. Hay ID, Hutchinson ME, Gonzalez-Losada T, et al. Papillary thyroid microcarcinoma: a study of 900 cases observed in a 60-year period. *Surgery* 2008;144(6):980-987.
14. Kebebew E, Greenspan FS, Clark OH, et al. Anaplastic thyroid carcinoma. Treatment outcome and prognostic factors. *Cancer* 2005;103(7):1330-1335.

15. Schwartz DL, Rana V, Shaw S, et al. Postoperative radiotherapy for advanced medullary thyroid cancer- local disease control in the modern era. Head Neck 2008;30:883-888.