

# 高雄榮民總醫院

上皮性卵巢癌、輸卵管癌、女性腹膜癌

## 診療指引

2019年01月22日第一版

婦癌醫療團隊擬訂

注意事項：這個診療原則主要作為醫師和其他保健專家診療癌症病人參考之用。假如你是一個癌症病人，直接引用這個診療原則並不恰當，只有你的醫師才能決定給你最恰當的治療。

- 本共識依下列參考資料修改版本
  - NCCN Clinical Practical Guidelines in Oncology (NCCN Guidelines) Ovarian Cancer, including Fallopian Tube Cancer and Primary Peritoneal Cancer, Version 2.2018

# 會議討論

上次會議：2018/12/20

## 本共識與上一版的差異

上一版	新版
<ol style="list-style-type: none"><li>1. 原診療指引有陳列第一線第一、二及第三、四期之【For stage II patient, Paclitaxel 60mg/m<sup>2</sup> IV over 1 hour followed by carboplatin AUC 2 IV over 30 minutes. Weekly for 18 weeks. (category 1), esp. for Elderly patients and those with poor performance status】化療處方。(p. 16)</li><li>2. 線上建置之Paclitaxel 60mg/m<sup>2</sup> (Weekly D1, D8 &amp; D15)+Carboplatin(AUC=5) (3 Weekly), every 21 days 未列陳列於診療指引第一線化療處方。(p. 16)</li><li>3. 原 Lipodoxorubicin 30mg/m<sup>2</sup>+ Gemcitabine 650mg/m<sup>2</sup>, D1&amp; D8, every 21~28 days只陳列在第三線化療處方。(p. 16)</li><li>4. 因研究線上建置之Study=Lipo-Doxorubicin+Opatin(D1&amp;D2)化療處方仍留置。(p. 16)</li></ol>	<ol style="list-style-type: none"><li>1. 刪除診療指引第一線第一、二及第三、四期所列之【For stage II patient, Paclitaxel 60mg/m<sup>2</sup> IV over 1 hour followed by carboplatin AUC 2 IV over 30 minutes. Weekly for 18 weeks. (category 1), esp. for Elderly patients and those with poor performance status】化療處方。(p. 16)</li><li>2. 將線上建置之Paclitaxel 60mg/m<sup>2</sup> (Weekly D1, D8 &amp; D15)+Carboplatin(AUC=5) (3 Weekly), every 21 days 列入診療指引第一線化療處方。(p. 16)</li><li>3. 將第二線或轉移及第三線化療處方重新分類，分為Platinum Sensitive及Platinum Refractory or Resistent，並將Lipodoxorubicin 30mg/m<sup>2</sup>+ Gemcitabine 650mg/m<sup>2</sup>, D1&amp; D8, every 21~28 days此筆化療處方兩處皆呈列。(p. 16)</li><li>4. 因研究線上建置之Study=Lipo-Doxorubicin+Opatin(D1&amp;D2)化療處方，研究已結束，故刪除此筆化療處方。(p. 16)</li></ol>

## 卵巢癌的FIGO新分期 2014版

## 卵巢癌的分期 AJCC第八版

卵巢癌之分期：上皮性卵巢癌，採用手術分期(**surgical staging**)；根據手術時的觀察及手術標本的組織病理檢查，來做分期的依據。病理報告需含有組織學類型、分化程度、卵巢以外的轉移與否及其轉移部位、淋巴結是否有轉移、卵巢有否向外生長的贅生物(**exophytic vegetation**)、以及腹水或腹膜腔灌洗(**peritoneal lavage**)之細胞學檢查結果。

第 I 期：癌症只限在卵巢(Tumor confined to ovaries)：

第 IA 期：癌症局限在一側的卵巢；卵巢的表面完整，且表面處沒有癌病變，腹水中或腹腔沖洗液中無癌細胞 (Tumor limited to one ovary; capsule intact, no tumor on ovarian surface. No malignant cells in ascites or peritoneal washings)。

第 IB 期：癌症局限在兩側的卵巢；卵巢的表面完整，且表面處沒有癌病變，腹水中或腹腔沖洗液中無癌細胞(Tumor limited to both ovaries; capsules intact, no tumor on ovarian surface. No malignant cells in ascites or peritoneal washings)。

第IC1期：癌症局限在一或兩側的卵巢，但手術中破裂 (Surgical spill)。

第IC2期：癌症局限在一或兩側的卵巢，但腫瘤術前已破裂或卵巢表面有腫瘤 (Capsule rupture before surgery or tumor on ovarian surface)。

第IC3期：癌症局限在一或兩側的卵巢，但腹水中或腹腔沖洗液中有癌細胞 (Malignant cells in the ascites or peritoneal washings)。

第 II 期：單側或兩側卵巢癌，並且有骨盆腔擴散(Tumor involves 1 or both ovaries with pelvic extension (below the pelvic brim) or primary peritoneal cancer)：

第 IIA 期：擴散只限於子宮或輸卵管 (Extension and/or implants on uterus and/or Fallopian tubes)。

第 IIB 期：擴散至骨盆腔內的其他組織 (Extension to other pelvic intraperitoneal tissues)。

第 III 期：單側或兩側卵巢癌，有骨盆腔以外的腹膜轉移，或轉移到後腹腔的淋巴結 (Tumor involves 1 or both ovaries with cytologically or histologically confirmed spread to the peritoneum outside the pelvis and/or metastasis to the retroperitoneal lymph nodes)：

第 IIIA 期：後腹腔淋巴結轉移和/或組織學的檢查證實有腹腔的轉移(Positive retroperitoneal lymph nodes and/or microscopic metastasis beyond the pelvis)：

第 IIIA1期：只有後腹腔淋巴結轉移 (Positive retroperitoneal lymph nodes only)：

第 IIIA1(i) 期：轉移小於或等於10 mm (Metastasis  $\leq$  10 mm)。

第 IIIA1(ii)期：轉移大於10 mm (Metastasis  $>$  10 mm)。

第 IIIA2期：組織學的檢查證實有腹腔的轉移和/或後腹腔淋巴結轉移(Microscopic, extrapelvic (above the brim) peritoneal involvement  $\pm$  positive retroperitoneal lymph nodes)。

第 IIIB 期：組織學檢查證實腹腔腹膜表面已經有了癌病變，但病變的最大徑並無超過兩公分者，和/或後腹腔淋巴結轉移(Macroscopic, extrapelvic, peritoneal metastasis  $\leq$  2 cm  $\pm$  positive retroperitoneal lymph nodes)。

第 IIIC 期：腹腔轉移病灶的最大徑已超過兩公分，和/或後腹腔淋巴結轉移，包含肝臟或脾臟外膜侵襲(Macroscopic, extrapelvic, peritoneal metastasis  $>$  2 cm  $\pm$  positive retroperitoneal lymph nodes. Includes extension to capsule or liver/spleen)。

第 IV 期：遠端轉移超出腹膜(Distant metastasis excluding peritoneal metastasis)：

第 IVA 期：肋膜積水有癌細胞 (Pleural effusion with positive cytology)。

第 IVB 期：肝臟或脾臟實質侵犯，轉移至腹外器官(包含腹股溝淋巴結與腹腔外淋巴結 (Hepatic and/or splenic parenchymal metastasis, metastasis to extra-abdominal organs (including inguinal lymph nodes and lymph nodes outside of the abdominal cavity)。

## 卵巢癌、輸卵管癌、女性腹膜癌 手術原則-1 (建議由婦癌醫師執行) (1-3)

通則：

- 1.對疑似惡性卵巢癌、輸卵管癌或腹膜癌患者，宜採腹部正中垂直開腹手術，此術式適用於第一次減癌手術(Primary cytoreduction)、期間檢癌手術(Interval cytoreduction)與再次檢癌手術(Secondary cytoreduction)。
- 2.術中病理冰凍切片有助於決定手術方式與範圍。
- 3.對特定的患者，可由婦癌醫師以微創手術進行分期或減癌手術；若無法進行適宜減癌手術(Optimal cytoreduction)，則因改用腹部正中垂直開腹手術。
- 4.對新診斷或復發之卵巢癌，可用微創手術評估適宜減癌手術的可行性；若評估後無法進行減癌手術，可考慮進行新輔助化學治療(Neoadjuvant chemotherapy)。

手術紀錄：

1.手術紀錄宜記載下列要項：

- a. 術前病灶範圍，包含骨盆腔、中腹部與上腹部。
- b. 減癌手術後，上述範圍中殘餘腫瘤的數量。
- c. 完全或不完全切除，若切除不完全，應註明主病灶的大小與位置、所有殘餘病灶的數量。

## 卵巢癌、輸卵管癌、女性腹膜癌 手術原則-2 (建議由婦癌醫師執行) (1-3)

1. 術前的腸道準備 (bowel preparation) 宜比照腸道手術之準備。
2. 宜用中央垂直開腹切口 (vertical incision) , 以獲取充分的手術視野 (exposure field) 。
3. 進入腹腔 , 即抽取腹水或經由腹腔灌洗 (peritoneal lavage) 取得腹膜腔細胞學檢查的標本(peritoneal cytologic examination) 。標本的採樣來自骨盆腔、左右兩側大腸側窩(right and left para-colic gutters) 、及左右兩側橫膈膜下表面 (the under-surface of the right and left hemidiaphragms) 。
4. 盡可能完整地取出腫瘤(encapsulated mass) , 檢體需盡快送病理檢驗 , 並常規性送冷凍切片 (frozen section) 。
5. 全子宮及兩側卵巢輸卵管切除手術 (total hysterectomy, bilateral salpingo-oophorectomy) 。
6. 考慮儘量切除輸卵管漏斗部骨盆韌帶 (infundibulopelvic ligaments) 。
7. 粘黏處需切片送檢。評估所有的腸道表面 , 且所有的可疑處都要切片送檢。
8. 若無明顯的卵巢外擴散病灶 (extra-ovarian tumor spread) , 則需隨機腹膜取樣(random peritoneal biopsy) , 如子宮直腸陷窩 (cul-de-sac) 、骨盆腔側壁、膀胱漿膜(serosa) 、兩側大腸側窩 (para-colic gutters) 、橫膈膜下表面 (subdiaphragmatic surfaces) 等。
9. 橫結腸下網膜切除手術 (infra-colic omentectomy) 。
10. 淋巴結評估 (lymph node assessment) : 要取主動脈旁淋巴結與骨盆淋巴結送病理檢查。主動脈旁的淋巴結 , 一般至少需取樣至 IMA (inferior mesenteric artery) , 但建議儘量能拿到 renal vein 之高度(漿液性(serous)卵巢癌 , 其淋巴結一開始的轉移位置往往高於 IMA 以上) 。在所有的上皮性卵巢癌主動脈旁淋巴結轉移當中 , IMA 以上的高處乃是最常見的轉移部位。而在有主動脈旁淋巴結轉移的單側上皮性卵巢癌當中 , 11%有對側的主動脈旁淋巴結轉移 , 因此雙側的主動脈旁淋巴結皆宜考慮摘取。
11. 闌尾切除手術 (appendectomy) : 若是黏液性卵巢癌 , 則應施行闌尾切除手術。
12. 關於腹腔鏡埠管路徑 (trocar tracks) : 若在卵巢癌的診斷過程中曾使用腹腔鏡者 , 可考慮切除腹腔鏡埠管路徑。
13. 完整的手術記錄 : 需載明手術前之所有病變、所使用的手術方式、手術後殘餘腫瘤(residual tumor)的大小與位置。
14. 對於強烈想要保留生育能力者 , 若腫瘤分化良好或分化中等 (grade 1/2) 、且並不是亮細胞(clear cell)癌 , 以及手術時肉眼所見為單側卵巢病變 , 且無卵巢外可見病灶時 , 可以考慮保留子宮與對側的卵巢 , 但必須執行完整分期手術的其他項目 ; 另側卵巢在無肉眼可見之病變時 , 可以不必做楔狀切片(wedge biopsy) , 以免妨害生育能力。若為雙側卵巢癌 , 則子宮在檢查之後可保留 , 但雙側卵巢都應切除 ; 其餘步驟同完整的分期手術。保留子宮的患者 , 宜做子宮腔鏡(hysteroscopy)及子宮內膜搔刮術 (curettage) 。
15. 對於卵巢以外的擴散病灶 , 應盡可能地做到最大程度的減積手術 (maximal cytoreduction) , 因為殘餘腫瘤的大小與預後有密切的關係。若標準手術無法達到適當的切除 (optimal resection ; 個別殘存腫瘤的最大直徑小於 1 公分) , 則宜考慮增加進一步手術(如部分腸道或臟器之切除)以達成此一目標。

# 上皮性卵巢癌、輸卵管癌、女性腹膜癌

## 臨床表現

## 評估檢查

## 初步治療 (建議由婦癌醫師執行) (18-20)

於腹部或骨盆腔檢查懷疑或觸診到骨盆腔腫塊及/或有腹水、及/或腹漲、及/或腹痛、骨盆腔疼痛、進食困難、一進食就飽、急尿或頻尿且沒有其他明顯惡性腫瘤的可能 (4-11)

1. 考慮完整家族史評估
  2. 腹部及骨盆腔理學檢查
  3. 如臨床懷疑為腸胃道轉移，則行消化系統評估(胃鏡與大腸鏡)
  4. 婦產科超音波檢查
  5. 腹部或骨盆腔電腦斷層\*
  6. 必要時行胸部影像學檢查(X光\*或電腦斷層)
  7. CA-125 或其他腫瘤指數
  8. 全血分析與完整生化檢查(含肝及腎功能)
  9. 可考慮正子攝影
- (6, 12-14)

剖腹探查((腹式全子宮切除及雙側卵巢輸卵管切除及完整分期手術) (21-23)  
 或  
 (期別為 IA 或 IB，不論細胞分化如何，病患想保留生育能力，可行單或雙側卵巢輸卵管切除及完整分期手術)  
 或  
 減癌手術(如期別為II、III、IV) (24-29)  
 或  
 (21-23)  
 先化學治療後再行減癌手術 (如經細針抽吸或切片證實之期別III或IV之巨大腫瘤不適合立即手術者)  
 或  
 (15-17)  
 緩和醫療(對身體狀況不適合手術與化學治療者)

流程 3

於前次手術或組織切片中發現

1. 考慮完整家族史評估
  2. 婦產科超音波檢查
  3. 腹部或骨盆腔電腦斷層\*
  4. 胸部影像學檢查(X光\*或電腦斷層)
  5. CA-125 或其他腫瘤指數
  6. 全血分析與完整生化檢查(含肝及腎功能)
  7. 需要時請院內病理部門複閱
  8. 可考慮正子攝影
- \*與期別相關之主要檢查

流程 2

流程 1

臨床研究顯示此類癌症由婦癌醫師評估與手術者較非婦癌醫師評估與手術者有較高之存活率且併發症較少

投影片 7

---

廖1

廖正義, 2017/9/20



# 上皮性卵巢癌、輸卵管癌、女性腹膜癌

臨床表現

評估檢查

初步治療 (建議由婦癌醫師執行)

前次手術分期完整詳盡

前次手術分期不完整如：  
子宮完整  
卵巢完整  
大網膜未切除  
手術記錄顯示分期手術不完整  
有殘餘腫瘤且可切除  
淋巴結廓清未完整

可能為IA或IB期  
分化良好

可能為IA或IB期  
分化中等

可能為IA或IB期  
分化不良  
或IC期

可能為II、III、  
IV期

懷疑有殘餘腫瘤

懷疑無殘餘腫瘤

懷疑有殘餘腫瘤

懷疑無殘餘腫瘤

懷疑有可切除之  
殘餘腫瘤

懷疑殘餘腫瘤不  
可切除

完整分期手術

完整分期手術

完整分期手術  
或6次化學治療

完整分期手術

完整分期手術  
或6次化學治療

減癌手術

6~8次化學治療  
或  
先3~6次化學治療  
後進行減癌手術，  
再追加術後化學  
治療

(30-32)

流程 3

(33)

流程 2

亮細胞癌(Clear Cell Carcinoma)屬於細胞分化不良(Grade 3)

# 上皮性卵巢癌、輸卵管癌、女性腹膜癌

## 評估檢查

## 初步輔助性化學治療

Less common ovarian histology  
(carcinosarcoma, clear cell, mucinous,  
low-grade serous, borderline epithelial)

流程 5,6,9

Grade 1  
serous/endometrio-  
id

流程 5

IA或IB期

Grade 2  
serous/endometri-  
oid

觀察  
或  
3~6 次靜脈化學治療(建議使用 Taxol+ Carboplatin)

IC期  
Grade 1, 2, 3

分化不良

3~6 次靜脈化學治療(建議使用 Taxol+ Carboplatin)

流程 4

II、III、IV期

化學治療  
6~8 次靜脈化學治療(建議使用含Taxol及Carboplatin  
± Bevacizumab(需自費)之配方) (71-72)  
或  
考慮腹腔內化學治療(於 II 或 III 期且手術後殘餘腫瘤 <1公分)

若先行化學治療且殘餘腫瘤對化療有反應而可再次切  
除者，則進行完整分期手術

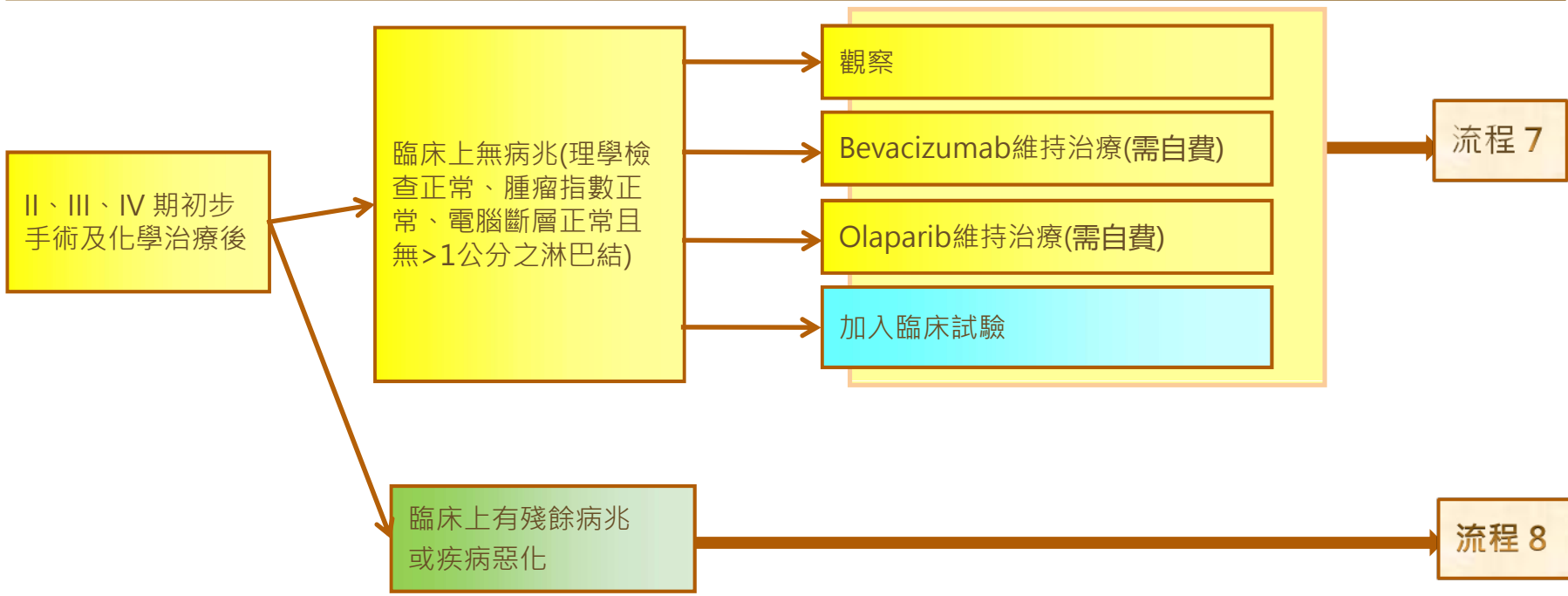
患者接受初步化療時需追蹤下列事項:

1. 每2化學療程做一次骨盆腔檢查
2. 化療中間需追蹤全血
3. 如需要時監測生化檢查
4. 每次化療前監測CA-125或其他腫瘤指數
5. 如需要時實施影像學檢查

流程 3

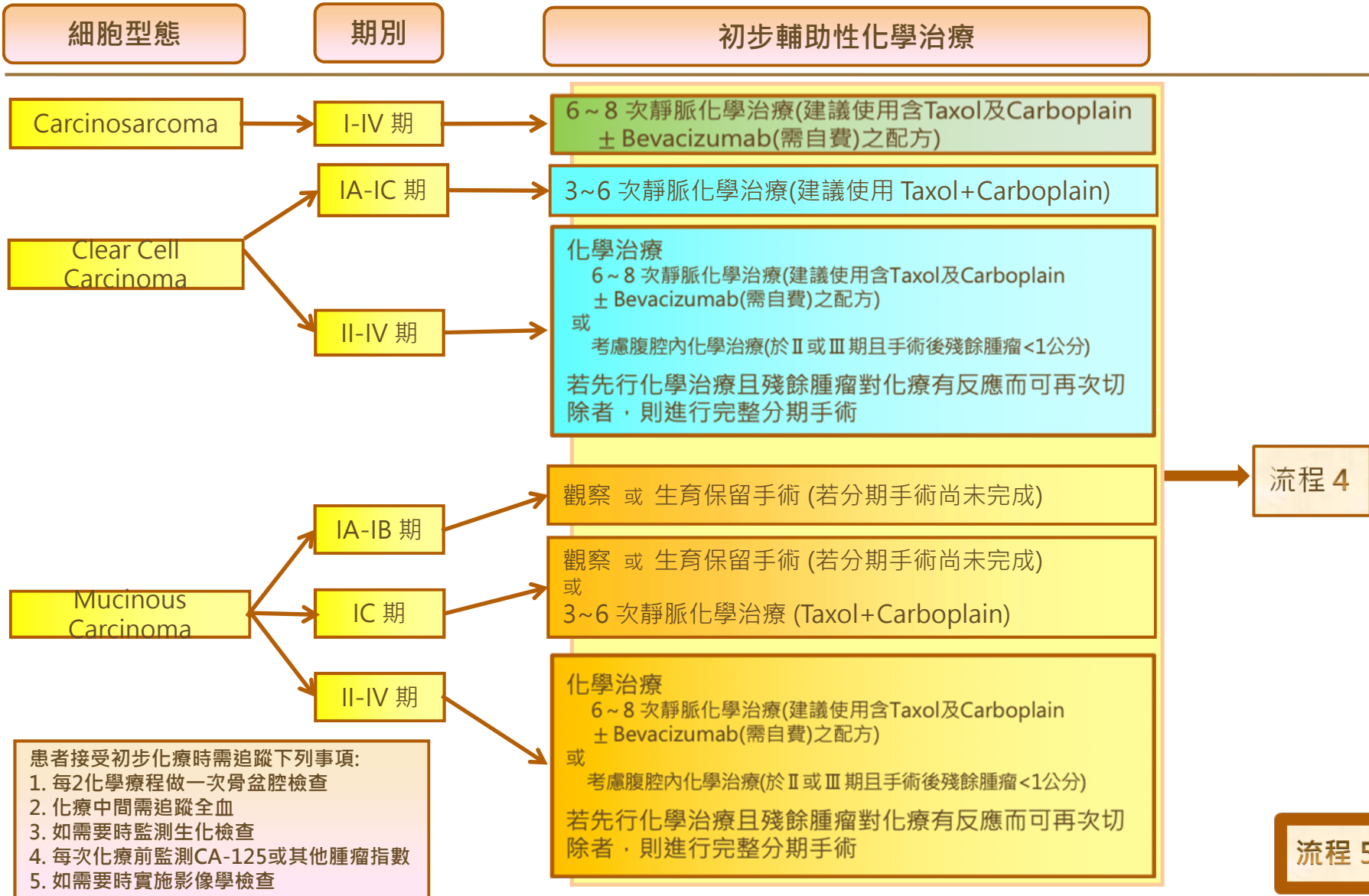
# 上皮性卵巢癌、輸卵管癌、女性腹膜癌

## 後續治療

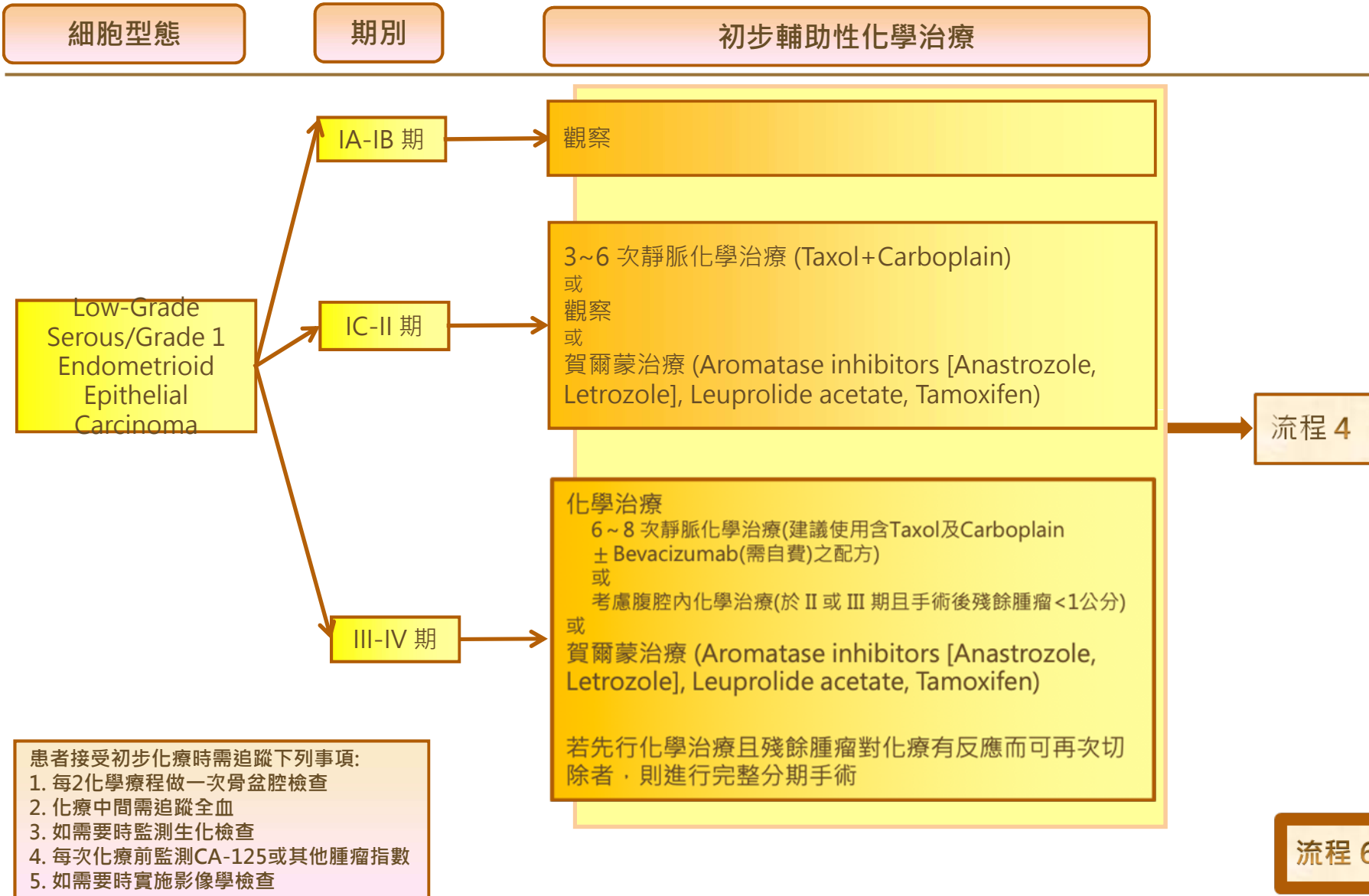


流程 4

# 上皮性卵巢癌、輸卵管癌、女性腹膜癌



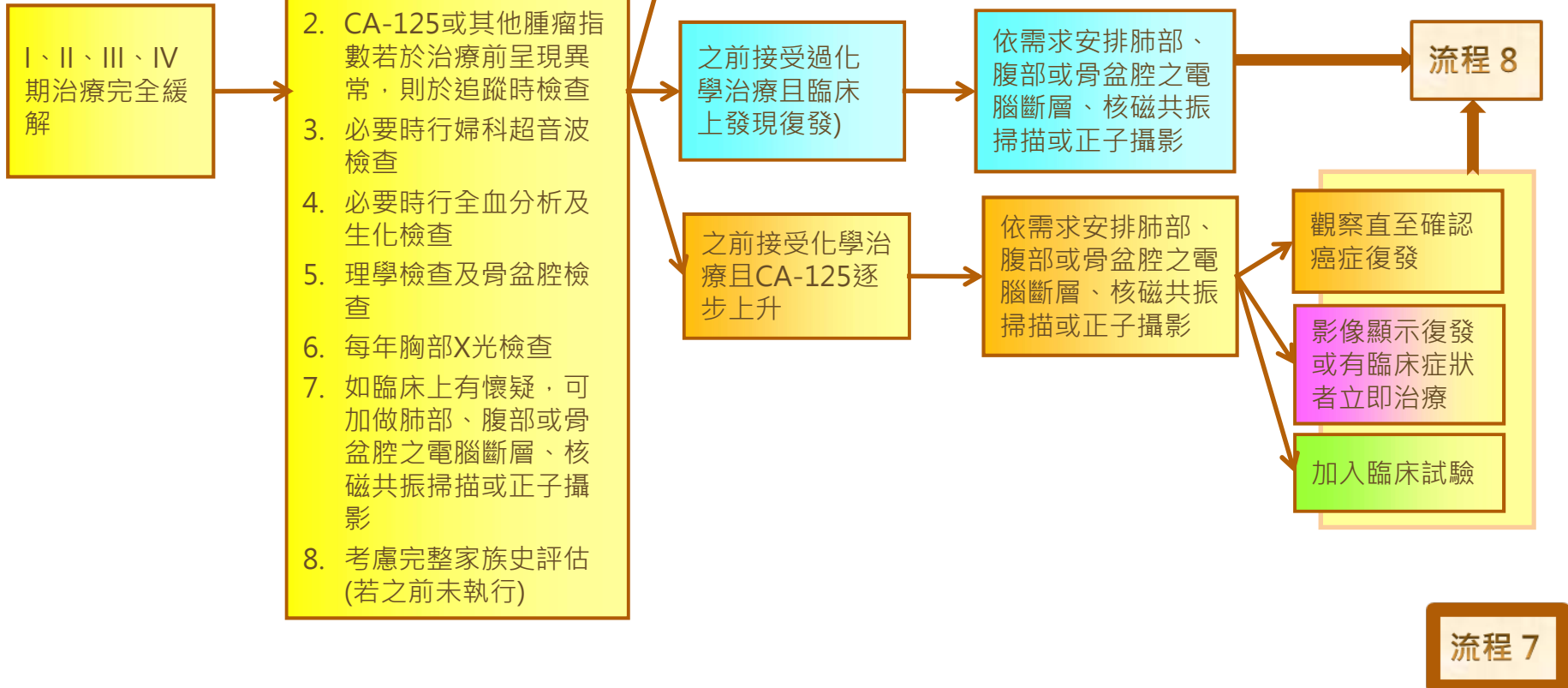
# 上皮性卵巢癌、輸卵管癌、女性腹膜癌



# 上皮性卵巢癌、輸卵管癌、女性腹膜癌 (39-40)

追蹤

復發



# 上皮性卵巢癌、輸卵管癌、女性腹膜癌 (41-43)

疾病狀態

持續性疾病或復發之治療

初次化療後惡化(progression)、穩定(stable)或持續性(persistent)疾病狀態

臨床試驗  
或  
支持療法  
或  
復發治療 (註)

初次化療後完全緩解但於停藥後 6 個月內復發或II, III, IV 期治療後只有部分緩解(partial response)

臨床試驗  
或  
復發治療 (註)  
或  
支持療法

初次化療後完全緩解但於停藥後6個月後復發

影像學  
及/或  
臨床上復發

含白金類藥物之複方化學治療  
(尤其是第一次復發時) (註)  
或  
復發治療 (註)(含RFA)  
或  
Tumor directed RT (44-48)  
或  
臨床試驗

考慮再次腫瘤減積手術

如經影像檢查後，發現部分或完全緩解，考慮  
Bevacizumab  
或PARP  
inhibitor維持療法

生化上復發  
(CA-125上升但無影像學的變化)

延遲治療直至臨床上復發  
或  
立即治療  
或  
臨床試驗

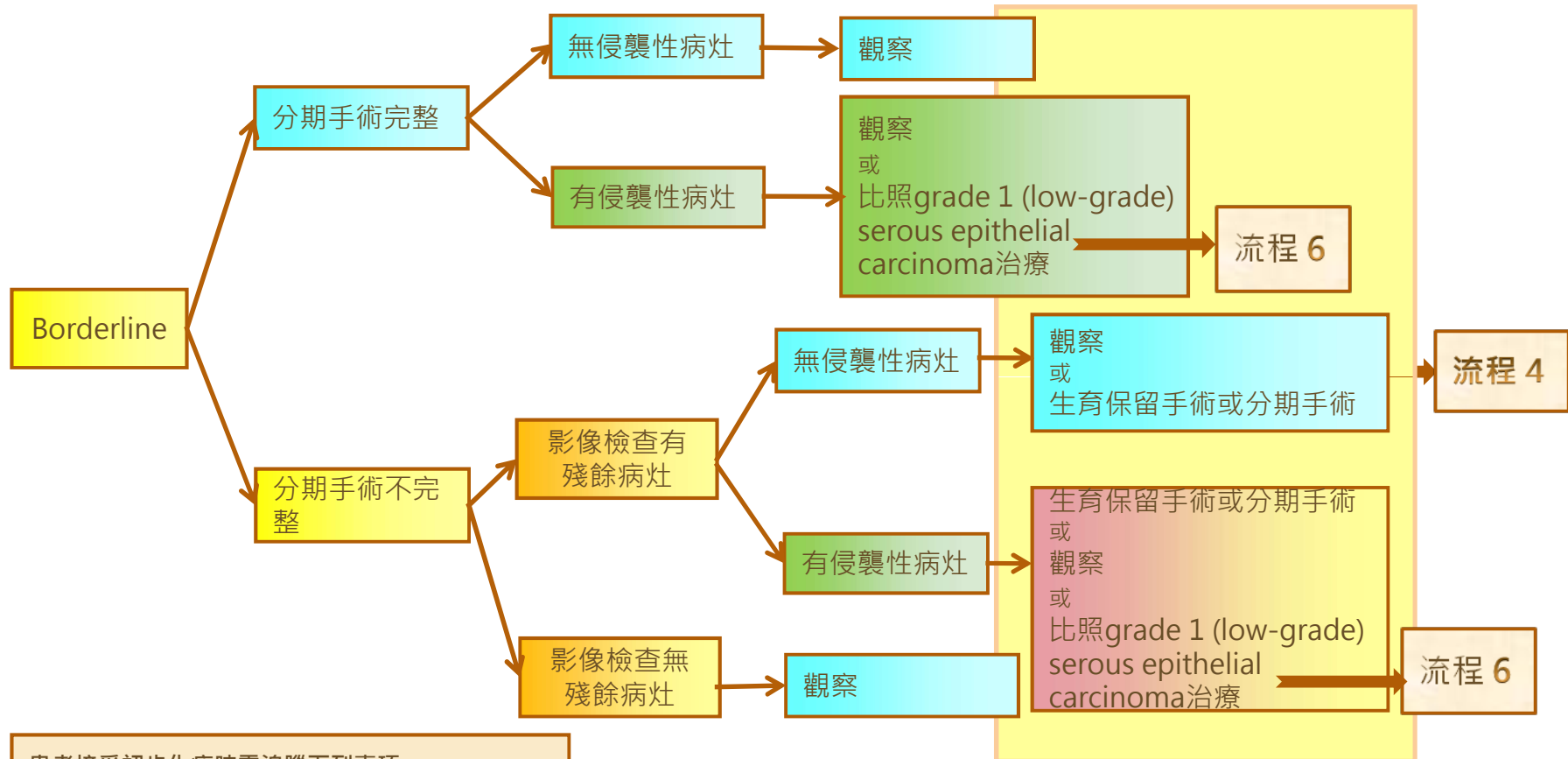
註：可考慮加上Bevacizumab或PARP inhibitor

流程 8

# 上皮性卵巢癌、輸卵管癌、女性腹膜癌

評估檢查

初步輔助性化學治療



患者接受初步化療時需追蹤下列事項:

1. 每2化學療程做一次骨盆腔檢查
2. 化療中間需追蹤全血
3. 如需要時監測生化檢查
4. 每次化療前監測CA-125或其他腫瘤指數
5. 如需要時實施影像學檢查

流程 9



## 上皮性卵巢癌、輸卵管癌、女性腹膜癌 化療藥物用藥指引

### 第一線化學治療與新輔助化學治療：

#### 第一、二期：

1. Carboplatin (AUC=5) + Epirubicin 50 mg/m<sup>2</sup> + Cyclophosphamide 500 mg/m<sup>2</sup>, every 21 days (58)
2. Taxol 175 mg/m<sup>2</sup> + Platinum (Carboplatin (AUC=5) or Cisplatin 50 mg/m<sup>2</sup>), every 21 days (有特殊狀況，如年齡大、ECOG PS差可先考慮單用Carboplatin) (34)
3. Paclitaxel 60mg/m<sup>2</sup> (Weekly D1, D8 & D15)+ Carboplatin (AUC=5) (3 Weekly),every 21 days (73)

#### 第三、四期：(可視臨床需要加上Bevacizumab: 5~15 mg/kg)

1. Taxol 175 mg/m<sup>2</sup> + Platinum(Carboplatin (AUC=5) or Cisplatin 50 mg/m<sup>2</sup>), every 21 days (有特殊狀況，如年齡大、ECOG PS差可先考慮單用Carboplatin) (34-38)
2. Paclitaxel 60mg/m<sup>2</sup> (Weekly D1, D8 & D15)+ Carboplatin (AUC=5) (3 Weekly),every 21 days (73)

### 第二線或轉移化學治療：(可視臨床需要加上Bevacizumab: 5~15 mg/kg)

#### Platinum Sensitive：

1. Lipodoxorubicin 30 mg/m<sup>2</sup> + Carboplatin AUC=5, every 28 days (49)
2. Lipodoxorubicin 30 mg/m<sup>2</sup> + Gemcitabine 650 mg/m<sup>2</sup>, D1& D8, every 21~28 days (57)
3. Gemcitabine 800~1200 mg/m<sup>2</sup> D1&D8 + Carboplatin AUC=5 D1, every 21 days (50)
4. Topotecan 0.75 mg/m<sup>2</sup> D1~D3 + Carboplatin AUC=5 D3, every 21 days (53-54)
5. Taxol 80 mg/m<sup>2</sup> + Carboplatin AUC=2 (Weekly D1, D8 & D15, every 21~28 days) (56)

#### Platinum Refractory or Resistant：

1. Lipodoxorubicin 40 mg/m<sup>2</sup> every 28 days (74)
2. Lipodoxorubicin 30 mg/m<sup>2</sup> + Gemcitabine 650 mg/m<sup>2</sup>, D1& D8, every 21~28 days (57)
3. Topotecan 1.25 mg/m<sup>2</sup> D1~D5, every 21 days (51)
4. Topotecan 3~4 mg/m<sup>2</sup> D1, D8 & D15, every 28 days (51)
5. Taxol 80 mg/m<sup>2</sup> + Topotecan 1.75 mg/m<sup>2</sup> (Weekly D1, D8 & D15, every 21~28 days) (55)
6. Cyclophosphamide 100 mg, 1# qd. (75)

### 復發後荷爾蒙治療：

Tamoxifen 10 mg, 1#, qd or bid. (52) Aromatase inhibitor, Leuprolide acetate, Megestrol acetate. (60-65)

### 維持治療：

Bevacizumab 5~15 mg/Kg (71-72)  
Olaparib 300~600 mg/Day (68-70)

腹腔內化學治療：Cisplatin 100 mg (76)

## Reference

1. Fleming GF, Seidman J, Lengyel E, et al: Epithelial ovarian cancer. In Barakat RR, Markman M, Randall ME (eds): Principles and Practice of Gynecologic Oncology, 6th ed, Philadelphia, Lippincott Williams & Wilkins, 2013:757-847.
2. Whitney CW, Spirto N. Gynecologic Oncology Group Surgical Procedures Manual. Philadelphia: Gynecologic Oncology Group; 2009.
3. Chi DS, Eisenhauer EL, Zivanovic O, et al. Improved progression-free and overall survival in advanced ovarian cancer as a result of a change in surgical paradigm. *Gynecol Oncol* 2009;114:26-31.
4. Goff BA, Mandel LS, Drescher CW, et al. Development of an ovarian cancer symptom index: possibilities for earlier detection. *Cancer* 2007;109:221-227.
5. Im SS, Gordon AN, Buttin BM, et al. Validation of referral guidelines for women with pelvic masses. *Obstet Gynecol* 2005;105:35-41.
6. ACOG Practice Bulletin. Management of adnexal masses. *Obstet Gynecol* 2007;110:201-214.
7. Dearking AC, Aletti GD, McGree ME, et al. How relevant are ACOG and SGO guidelines for referral of adnexal mass? *Obstet Gynecol* 2007;110:841-848.
8. Timmerman D, Testa AC, Bourne T, et al. Simple ultrasound-based rules for the diagnosis of ovarian cancer. *Ultrasound Obstet Gynecol* 2008;31:681-690.
9. Iyer VR, Lee SI. MRI, CT, and PET/CT for ovarian cancer detection and adnexal lesion characterization. *AJR Am J Roentgenol* 2010;194:311-321.
10. Harris RD, Javitt MC, Glanc P, et al. ACR Appropriateness Criteria(R) clinically suspected adnexal mass. *Ultrasound Q* 2013;29:79-86.
11. Dodge JE, Covens AL, Lacchetti C, et al. Management of a suspicious adnexal mass: a clinical practice guideline. *Curr Oncol* 2012;19:e244-257.
12. Yamamoto Y, Oguri H, Yamada R, et al. Preoperative evaluation of pelvic masses with combined 18F-fluorodeoxyglucose positron emission tomography and computed tomography. *Int J Gynaecol Obstet* 2008;102:124-127.
13. Castellucci P, Perrone AM, Picchio M, et al. Diagnostic accuracy of 18F-FDG PET/CT in characterizing ovarian lesions and staging ovarian cancer: correlation with transvaginal ultrasonography, computed tomography, and histology. *Nucl Med Commun* 2007;28:589-595.

## Reference

14. Risum S, Hogdall C, Loft A, et al. The diagnostic value of PET/CT for primary ovarian cancer--a prospective study. *Gynecol Oncol* 2007;105:145-149.
15. Cannistra SA, Gershenson DM, Recht A. Ovarian cancer, fallopian tube carcinoma, and peritoneal carcinoma. In: DeVita Jr. VT, Lawrence TS, Rosenberg SA, et al., eds. *DeVita, Hellman, and Rosenberg's Cancer: Principles and Practice of Oncology*, 9th ed. Philadelphia: Lippincott Williams & Wilkins; 2011.
16. Vergote I, De Brabanter J, Fyles A, et al. Prognostic importance of degree of differentiation and cyst rupture in stage I invasive epithelial ovarian carcinoma. *Lancet* 2001;357:176-182.
17. DeVita VT, Lawrence TS, Rosenberg SA, DePinho RA. *DeVita, Hellman, and Rosenberg's Cancer: Principles & Practice of Oncology* (ed 8th). Philadelphia: Lippincott Williams & Wilkins; 2008.
18. Giede KC, Kieser K, Dodge J, Rosen B. Who should operate on patients with ovarian cancer? An evidence-based review. *Gynecol Oncol* 2005;99:447-461.
19. Earle CC, Schrag D, Neville BA, et al. Effect of surgeon specialty on processes of care and outcomes for ovarian cancer patients. *J Natl Cancer Inst* 2006;98:172-180.
20. du Bois A, Quinn M, Thigpen T, et al. 2004 consensus statements on the management of ovarian cancer: final document of the 3rd International Gynecologic Cancer Intergroup Ovarian Cancer Consensus Conference (GCIg OCCC 2004). *Ann Oncol* 2005;16 Suppl 8:viii7-viii12.
21. Fleming GF, Seidman J, Lengyel E. Epithelial ovarian cancer. In: Barakat RR, Markman M, Randall ME, eds. *Principles and Practice of Gynecologic Oncology*, 6th ed. Philadelphia: Lippincott Williams & Wilkins; 2013:757-847.
22. Schorge JO, Eisenhauer EE, Chi DS. Current surgical management of ovarian cancer. *Hematol Oncol Clin North Am* 2012;26:93-109.
23. Whitney CW, Spirto N. *Gynecologic Oncology Group Surgical Procedures Manual*. Philadelphia: Gynecologic Oncology Group; 2009.
24. Schlaerth AC, Chi DS, Poyner EA, et al. Long-term survival after fertility-sparing surgery for epithelial ovarian cancer. *Int J Gynecol Cancer* 2009;19:1199-1204
25. Schilder JM, Thompson AM, DePriest PD, et al. Outcome of reproductive age women with stage IA or IC invasive epithelial ovarian cancer treated with fertility-sparing therapy. *Gynecol Oncol* 2002;87:1-7.
26. Fader AN, Rose PG. Role of surgery in ovarian carcinoma. *J Clin Oncol* 2007;25:2873-2883.
27. Wright JD, Shah M, Mathew L, et al. Fertility preservation in young women with epithelial ovarian cancer. *Cancer* 2009;115:4118-4126.

## Reference

28. Satoh T, Hatae M, Watanabe Y, et al. Outcomes of fertility-sparing surgery for stage I epithelial ovarian cancer: a proposal for patient selection. *J Clin Oncol* 2010;28:1727-1732.
29. Gershenson DM. Treatment of ovarian cancer in young women. *Clin Obstet Gynecol* 2012;55:65-74.
30. Young RC, Walton LA, Ellenberg SS, et al. Adjuvant therapy in stage I and stage II epithelial ovarian cancer. Results of two prospective randomized trials. *N Engl J Med* 1990;322:1021-1027.
31. Winter-Roach BA, Kitchener HC, Dickinson HO. Adjuvant (post-surgery) chemotherapy for early stage epithelial ovarian cancer. *Cochrane Database Syst Rev* 2009:CD004706.
32. Hogberg T, Glimelius B, Nygren P, Care SB-gSCoTAiH. A systematic overview of chemotherapy effects in ovarian cancer. *Acta Oncol* 2001;40:340-360.
33. Cristea M, Han E, Salmon L, Morgan RJ. Practical considerations in ovarian cancer chemotherapy. *Ther Adv Med Oncol* 2010;2:175-187.
34. Ozols RF, Bundy BN, Greer BE, et al. Phase III trial of carboplatin and paclitaxel compared with cisplatin and paclitaxel in patients with optimally resected stage III ovarian cancer: a Gynecologic Oncology Group study. *J Clin Oncol* 2003;21:3194-3200.
35. Burger RA, Brady MF, Bookman MA, et al. Phase III trial of bevacizumab (BEV) in the primary treatment of advanced epithelial ovarian cancer (EOC), primary peritoneal cancer (PPC), or fallopian tube cancer (FTC): A Gynecologic Oncology Group study [abstract]. *J Clin Oncol* 2010;28(Suppl 18):Abstract LBA1.
36. Burger RA, Brady MF, Bookman MA, et al. Incorporation of bevacizumab in the primary treatment of ovarian cancer. *N Engl J Med* 2011;365:2473-2483.
37. Hall M, Gourley C, McNeish I, et al. Targeted anti-vascular therapies for ovarian cancer: current evidence. *Br J Cancer* 2013;108:250-258.
38. Kristensen G, Perren T, Qian W, et al. Result of interim analysis of overall survival in the GCIg ICON7 phase III randomized trial of bevacizumab in women with newly diagnosed ovarian cancer [abstract]. *J Clin Oncol* 2011;29(Suppl 18):Abstract LBA5006.
39. Salani R, Backes FJ, Fung MF, et al. Posttreatment surveillance and diagnosis of recurrence in women with gynecologic malignancies: Society of Gynecologic Oncologists recommendations. *Am J Obstet Gynecol* 2011;204:466-478.
40. Bhosale P, Peungjesada S, Wei W, et al. Clinical utility of positron emission tomography/computed tomography in the evaluation of suspected recurrent ovarian cancer in the setting of normal CA-125 levels. *Int J Gynecol Cancer* 2010;20:936-944.
41. Markman M, Rothman R, Hakes T, et al. Second-line platinum therapy in patients with ovarian cancer previously treated with cisplatin. *J Clin Oncol* 1991;9:389-393.

## Reference

42. Fung-Kee-Fung M, Oliver T, Elit L, et al. Optimal chemotherapy treatment for women with recurrent ovarian cancer. *Curr Oncol* 2007;14:195-208.
43. Parmar MK, Ledermann JA, Colombo N, et al. Paclitaxel plus platinum-based chemotherapy versus conventional platinum-based chemotherapy in women with relapsed ovarian cancer: the ICON4/AGO-OVAR-2.2 trial. *Lancet* 2003;361:2099-2106.
44. Corn BW, Lanciano RM, Boente M, et al. Recurrent ovarian cancer. Effective radiotherapeutic palliation after chemotherapy failure. *Cancer* 1994;74:2979-2983.
45. Tinger A, Waldron T, Peluso N, et al. Effective palliative radiation therapy in advanced and recurrent ovarian carcinoma. *Int J Radiat Oncol Biol Phys* 2001;51:1256-1263.
46. Smith SC, Koh WJ. Palliative radiation therapy for gynaecological malignancies. *Best Pract Res Clin Obstet Gynaecol* 2001;15:265-278.
47. Yan J, Milosevic M, Fyles A, et al. A hypofractionated radiotherapy regimen (0-7-21) for advanced gynaecological cancer patients. *Clin Oncol (R Coll Radiol)* 2011;23:476-481.
48. Teckie S, Makker V, Tabar V, et al. Radiation therapy for epithelial ovarian cancer brain metastases: clinical outcomes and predictors of survival. *Radiat Oncol* 2013;8:36.
49. Pujade-Lauraine E, Wagner U, Aavall-Lundqvist E, et al. Pegylated liposomal Doxorubicin and Carboplatin compared with Paclitaxel and Carboplatin for patients with platinum-sensitive ovarian cancer in late relapse. *J Clin Oncol* 2010;28:3323-3329.
50. Pfisterer J, Plante M, Vergote I, et al. Gemcitabine plus carboplatin compared with carboplatin in patients with platinum-sensitive recurrent ovarian cancer: an intergroup trial of the AGO-OVAR, the NCIC CTG, and the EORTC GCG. *J Clin Oncol* 2006;24:4699-4707.
51. Sehouli J, Stengel D, Harter P, et al. Topotecan weekly versus conventional 5-day schedule in patients with platinum-resistant ovarian cancer: a randomized multicenter phase II trial of the North-Eastern German Society of Gynecological Oncology Ovarian Cancer Study Group. *J Clin Oncol* 2011;29:242-248.
52. Markman M, Iseminger KA, Hatch KD, et al. Tamoxifen in platinum-refractory ovarian cancer: a Gynecologic Oncology Group Ancillary Report. *Gynecol Oncol* 1996;62:4-6.
53. Ten Bokkel Huinink W, Carmichael J, Armstrong D, Gordon A, Malfetano J. *Semin Oncol*. Efficacy and safety of topotecan in the treatment of advanced ovarian carcinoma. Department of Internal Medicine, The Netherlands Cancer Institute, Amsterdam. 1997 Feb;24(1 Suppl 5):S5-19-S5-25.
54. Sehouli J, Oskay-Ozcelik G. *Curr Med Res Opin*. Current role and future aspects of topotecan in relapsed ovarian cancer. 2009 Mar;25(3):639-51.
55. Stathopoulos GP. *Cancer Chemother Pharmacol*. Weekly administration of topotecan-paclitaxel as second-line treatment in ovarian cancer. 2007 Jun;60(1):123-8

## Reference

56. Abaid LN, Cancer Chemother Pharmacol. A phase II study of modified dose-dense paclitaxel and every 4-week carboplatin for the treatment of advanced-stage primary epithelial ovarian, fallopian tube, or peritoneal carcinoma. 2013 Jul;72(1):101-7
57. Ferrandina G, Gynecol Oncol. Gemcitabine and liposomal doxorubicin in the salvage treatment of ovarian cancer: updated results and long-term survival. 2005 Aug;98(2):267-73.
58. Andersson H. Acta Oncol. Carboplatin in combination with epirubicin and cyclophosphamide in patients with advanced ovarian cancer. A phase II study. 1995;34(6):821-7.
59. Pignata S, Scambia G, Katsaros D, et al. Carboplatin plus paclitaxel once a week versus every 3 weeks in patients with advanced ovarian cancer (MITO-7): a randomised, multicentre, open-label, phase 3 trial. Lancet Oncol 2014;15:396-405.
60. Yokoyama Y, Mizunuma H. Recurrent epithelial ovarian cancer and hormone therapy. World J Clin Cases 2013; 1(6):187-190.
61. Rao GG, Miller DS. Hormonal therapy in epithelial ovarian cancer. Expert Rev Anticancer Ther 2006;6(1):43-47.
62. Papadimitriou CA, et al. Hormonal therapy with letrozole for relapsed epithelial ovarian cancer. Long-term results of a phase II study. Oncology 2004;66(2):112-7.
63. Bowman A, et al. CA125 response is associated with estrogen receptor expression in a phase II trial of letrozole in ovarian cancer: identification of an endocrine-sensitive subgroup. Clin Cancer Res 2002;8(7):2233-9.
64. del Carmen MG, et al. Phase II trial of anastrozole in women with asymptomatic müllerian cancer. Gynecol Oncol 2003;91(3):596-602.
65. Ramirez PT, et al. Efficacy of letrozole in the treatment of recurrent platinum- and taxane-resistant high-grade cancer of the ovary or peritoneum. Gynecol Oncol 2008;110(1):56-9.
66. Kaufman B, et al. Olaparib monotherapy in patients with advanced cancer and a germline BRCA1/2 mutation. J Clin Oncol 2015;20;33(3):244-50.
67. Clinical Commentary. 2014 FIGO staging for ovarian, fallopian tube and peritoneal cancer. Gynecol Oncol 2014;133: 401-404
68. Pujade-Lauraine E, Ledermann JA, Selle F, GebSKI V, Penson RT, Oza AM, Korach J, Huzarski T, Poveda A, Pignata S, Friedlander M, Colombo N, Harter P, Fujiwara K, Ray-Coquard I, Banerjee S, Liu J, Lowe ES, Bloomfield R, Pautier P; **Olaparib tablets as maintenance therapy in patients with platinum-sensitive, relapsed ovarian cancer and a BRCA1/2 mutation (SOLO2/ENGOT-Ov21): a double-blind, randomised, placebo-controlled, phase 3 trial.** Lancet Oncol. 2017 Sep;18(9):1274-1284.
69. Ledermann J, Harter P, Gourley C, Friedlander M, Vergote I, Rustin G, Scott C, Meier W, Shapira-Frommer R, Safra T, Matei D, Macpherson E, Watkins C, Carmichael J, Matulonis U. **Olaparib maintenance therapy in platinum-sensitive relapsed ovarian cancer.** N Engl J Med. 2012 Apr 12;366(15):1382-92.

## Reference

70. M Friedlander K Moore N Colombo G Scambia B-G Kim A Oaknin A LisyanskayaA Floquet A Leary G S Sonke C Gourley S Banerjee A M Oza A González-MartínC Aghajanian W Bradley E S Lowe R Bloomfield P Disilvestro **Maintenance olaparib following platinum-based chemotherapy in newly diagnosed patients (pts) with advanced ovarian cancer (OC) and a BRCA1/2 mutation (BRCAm): Phase III SOLO1 trial** *Annals of Oncology*, Volume 29, Issue suppl\_9, 1 November 2018
71. Oza AM, Cook AD, Pfisterer J, Embleton A, Ledermann JA, Pujade-Lauraine E, Kristensen G, Carey MS, Beale P, Cervantes A, Park-Simon TW, Rustin G, Joly F, Mirza MR, Plante M, Quinn M, Poveda A, Jayson GC, Stark D, Swart AM, Farrelly L, Kaplan R, Parmar MK, Perren TJ; **Standard chemotherapy with or without bevacizumab for women with newly diagnosed ovarian cancer (ICON7): overall survival results of a phase 3 randomised trial.** *Lancet Oncol.* 2015 Aug;16(8):928-36.
72. [Burger RA](#)<sup>1</sup>, [Brady MF](#), [Bookman MA](#), [Fleming GF](#), [Monk BJ](#), [Huang H](#), [Mannel RS](#), [Homesley HD](#), [Fowler J](#), [Greer BE](#), Boente M, Birrer MJ, Liang SX; Gynecologic Oncology Group. **Incorporation of bevacizumab in the primary treatment of ovarian cancer** *N Engl J Med.* 2011 Dec 29;365(26):2473-83.
73. Thigpen JT, Aghajanian CA, Alberts DS, Campos SM, Gordon AN, Markman M, McMeekin DS, Monk BJ, Rose PG; Role of pegylated liposomal doxorubicin in ovarian cancer. *Gynecol Oncol.*2005 Jan; 96(1):10-8
74. Wong CN, Liu FS; Continuous oral cyclophosphamide as salvage or maintenance therapy in ovarian, primary peritoneal, and fallopian tube cancers: A retrospective, single institute study. *Twain J Obstet Gynecol.* 2017 Jun; 56(3):302-305.
75. Chan JK, Brady MF, Penson RT, Huang H, Birrer MJ, Walker JL, DiSilvestro PA, Rubin SC, Martin LP, Davidson SA, Huh WK, O'Malley DM, Boente MP, Michael H, Monk BJ; *N Engl J Med.* 2016 Feb 25;374(8):738-48
76. Amstrong DK, Bunday B, Wenzel L, Huang HQ, Baergen R, Lele S, Copeland LJ, Walker JL, Burger RA; Intraperitoneal cisplatin and paclitaxel in ovarian cancer; *N Engl J Med.* 2006 Jan 5; 354(1):34-43