

高雄榮民總醫院 子宮內膜癌診療指引

2020年02月25日第一版

婦癌醫療團隊擬訂

注意事項：這個診療原則主要作為醫師和其他保健專家診療癌症病人參考之用。假如你是一個癌症病人，直接引用這個診療原則並不恰當，只有你的醫師才能決定給你最恰當的治療。

修訂指引

- 本共識依下列參考資料修改版本
 - NCCN Clinical Practical Guidelines in Oncology™
Uterine Cancer (Version 5.2019)
 - 子宮內膜癌臨床指引：國家衛生研究院
 - 婦癌研究委員會

會議討論

上次會議：2019/01/17

本共識與上一版的差異

上一版	新版
<ol style="list-style-type: none">1. 原流程圖八中有” 仍未定論” 的註記。(p. 15)2. 原流程圖八無手術以外治療選項。(p. 15)3. 原有的化療使用原則(針對復發性、轉移性及高風險性)可使用的配方化療處方Pembrolizumab(Keytruda) (200mg)無For MSI-H/dMMR tumor備註。(p. 19)	<ol style="list-style-type: none">1. 刪除流程圖八中” 仍未定論” 的註記。(p. 15)2. 在流程圖八新增無法或不適手術者的治療選項。(p. 15)3. 在化療使用原則(針對復發性、轉移性及高風險性)可使用的配方化療處方Pembrolizumab(Keytruda) (200mg)新增For MSI-H/dMMR tumor備註。(p. 19)

高雄榮總婦產部 子宮內膜癌臨床治療指引

2010 New FIGO and TNM staging (AJCC 8th)

Primary Tumor (T)		
T	FIGO	T Criteria
TX		Primary tumor cannot be assessed
T0		No evidence of primary tumor
T1	I	Tumor confined to the corpus uteri, including endocervical glandular involvement
T1a	IA	Tumor limited to the endometrium or invading less than half the myometrium
T1b	IB	Tumor invading one half or more of the myometrium
T2	II	Tumor invading the stromal connective tissue of the cervix but not extending beyond the uterus. Does NOT include endocervical glandular involvement.
T3	III	Tumor involving serosa, adnexa, vagina, or parametrium
T3a	IIIA	Tumor involving the serosa and/or adnexa (direct extension or metastasis)
T3b	IIIB	Vaginal involvement (direct extension or metastasis) or parametrial involvement
T4	IVA	Tumor invading the bladder mucosa and/or bowel mucosa (bullous edema is not sufficient to classify a tumor as T4)

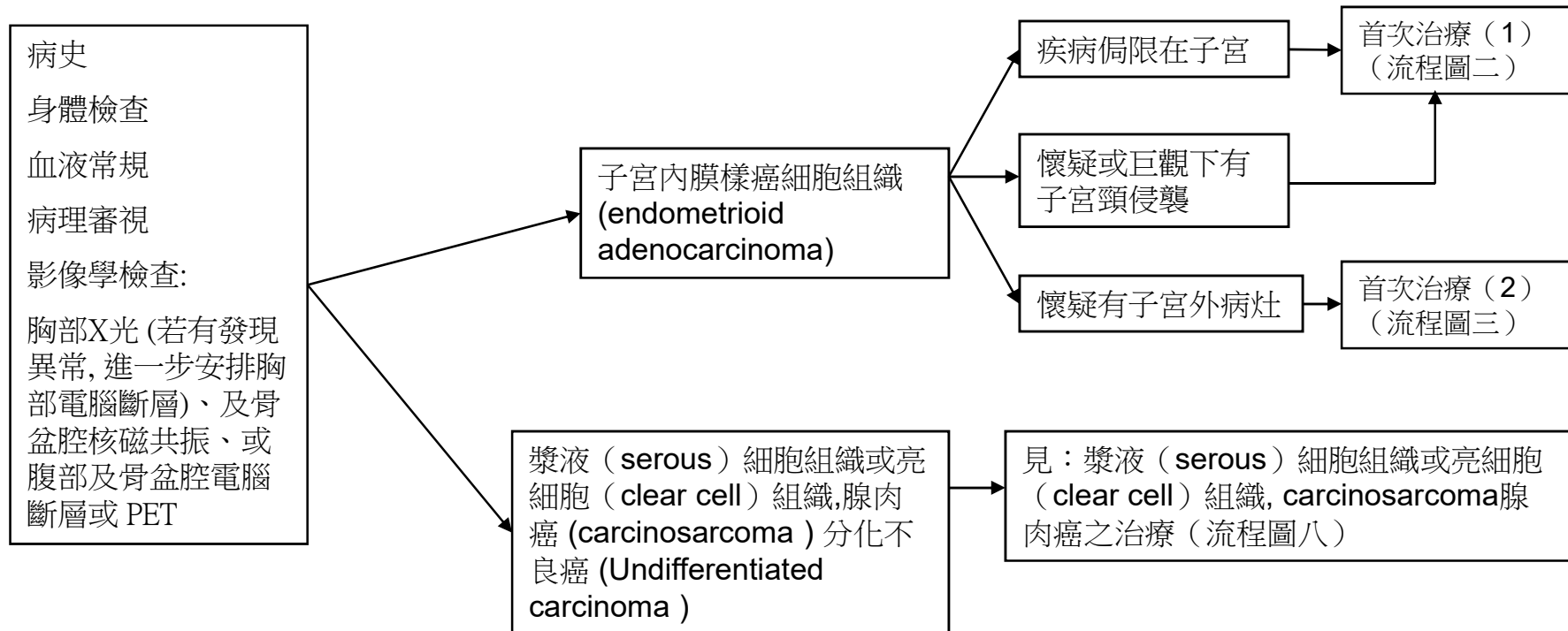
Regional Lymph Node (N)		
N	FIGO	N Criteria
NX		Regional lymph nodes cannot be assessed
N0		No regional lymph node metastasis
N0 (i+)		Isolated tumor cells in regional lymph node(s) no greater than 0.2 mm
N1	IIIC1	Regional lymph nodes metastasis to pelvic lymph nodes
N1mi	IIIC1	Regional lymph node metastasis (greater than 0.2 mm but not greater than 2.0 mm in diameter) to pelvic lymph nodes
N1a	IIIC1	Regional lymph node metastasis (greater than 2.0 mm in diameter) to pelvic lymph nodes
N2	IIIC2	Regional lymph node metastasis to para-aortic lymph nodes, with or without positive pelvic lymph nodes
N2mi	IIIC2	Regional lymph node metastasis (greater than 0.2 mm but not greater than 2.0 mm in diameter) to para-aortic lymph nodes, with or without positive pelvic lymph nodes
N2a	IIIC2	Regional lymph node metastasis (greater than 2.0 mm in diameter) to para-aortic lymph nodes, with or without positive pelvic lymph nodes

Distant Metastasis (M)		
M	FIGO	M Criteria
M0		No distant metastasis
M1	IVB	Distant metastasis (includes metastasis to inguinal lymph nodes, intraperitoneal disease, lung, liver, or bone). (It excludes metastasis to pelvic or para-aortic lymph nodes, vagina, uterine serosa, or adnexa).

高雄榮總婦產部 子宮內膜癌臨床治療指引

2010 New FIGO and TNM staging (AJCC 8th)

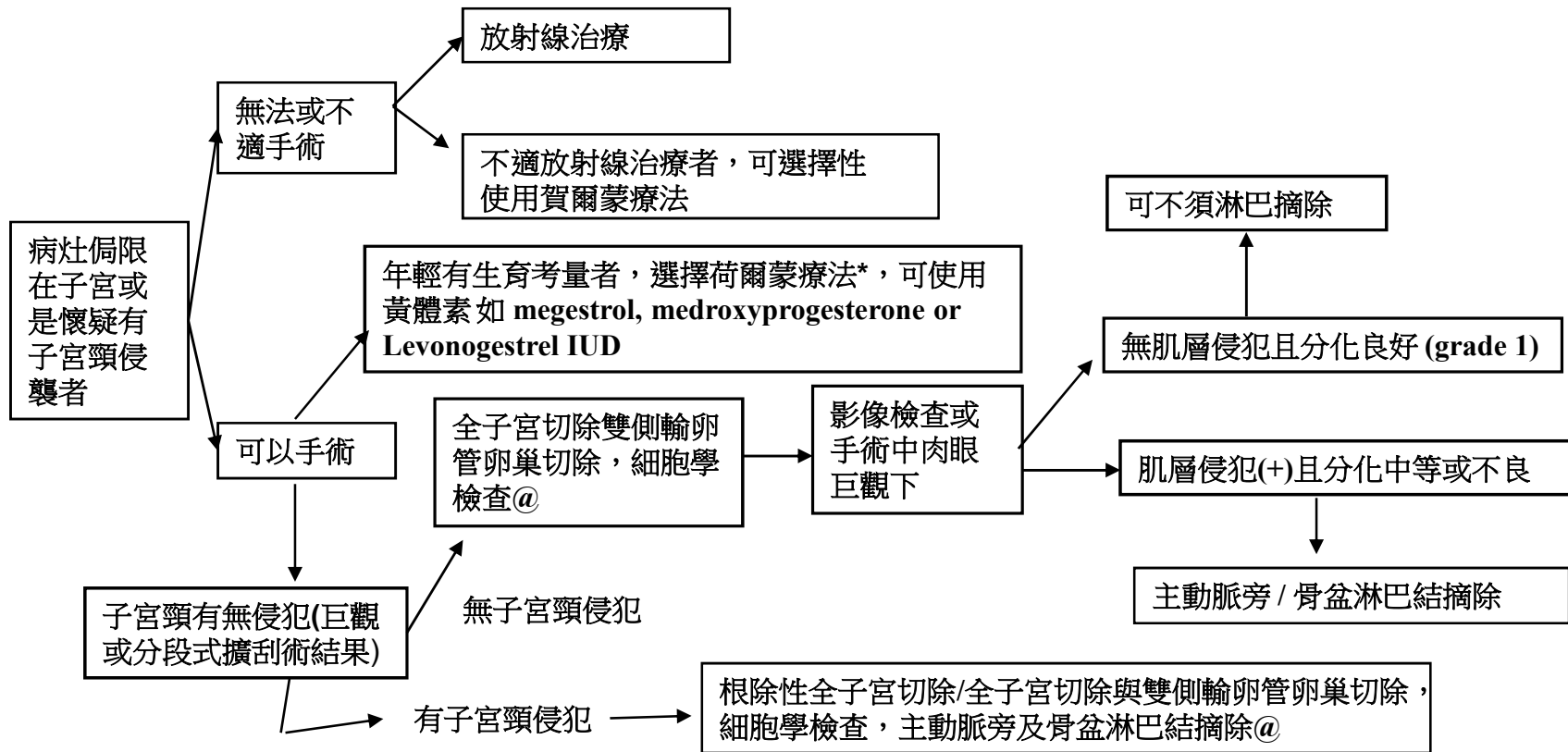
STAGE GROUPS			
T	N	M	stage
T1	N0	M0	I
T1a	N0	M0	IA
T1b	N0	M0	IB
T2	N0	M0	II
T3	N0	M0	III
T3a	N0	M0	IIIA
T3b	N0	M0	IIIB
T1-T3	N1/N1mi/N1a	M0	IIIC1
T1-T3	N2/N2mi/N2a	M0	IIIC2
T4	Any N	M0	IVA
Any T	Any N	M1	IVB



流程圖一

首次治療(1)

術前評估：病史 身體檢查 血液檢查 子宮頸內頸暨子宮內膜切片 (分段式擴刮術) 子宮頸細胞學檢查 胸部X光*，核磁共振*或電腦斷層*，腫瘤指標(CEA,CA-125,CA-199) *與期別相關之主要檢查(必要項目)



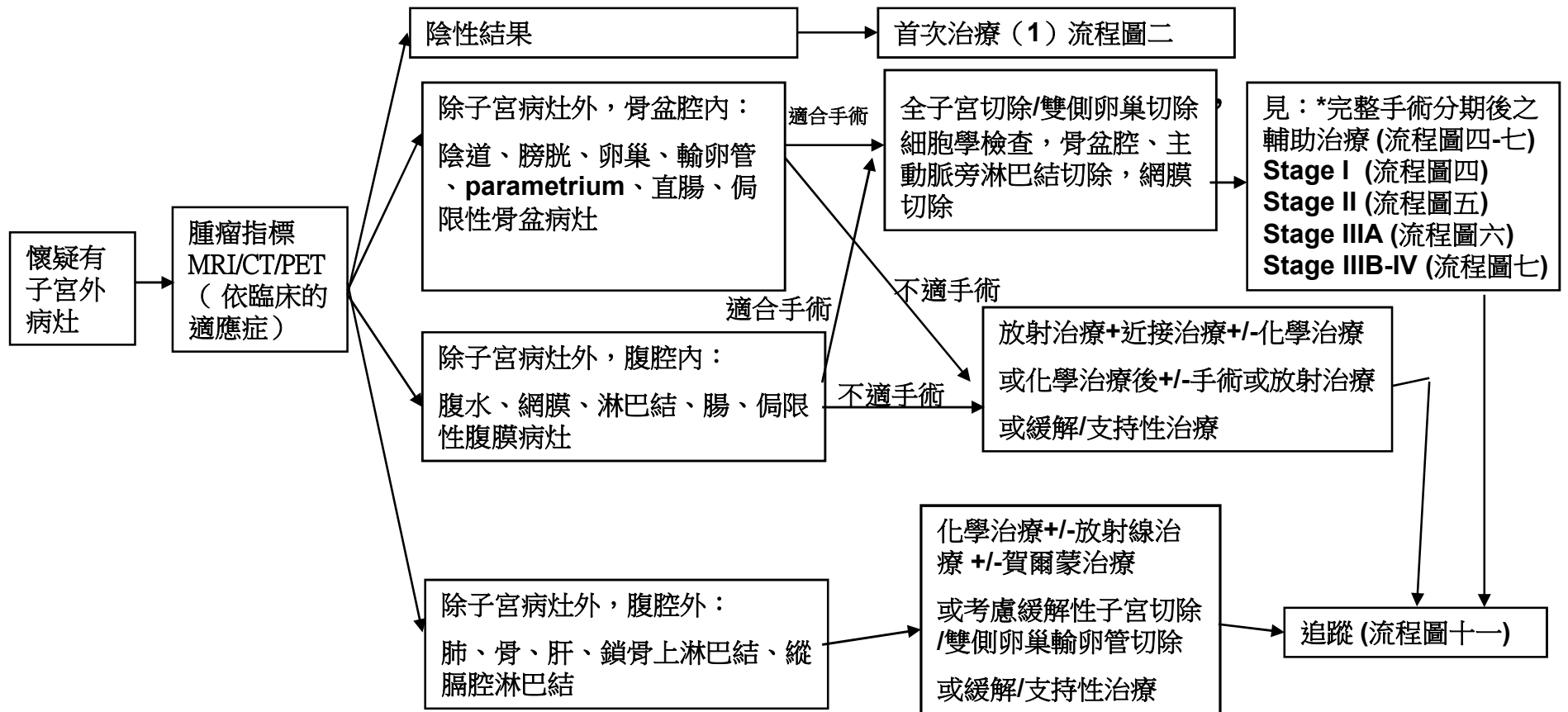
@: 卵巢是否全切抑或保留由臨床醫師視病情與年齡及病人意願決定, <45 y/o, 子宮肌肉層侵犯<50% 且為**grade I**，可考慮保留卵巢，建議切除輸卵管。

* 影像檢查僅內膜病灶且細胞分化程度為**Grade 1**者

流程圖二

首次治療 (2)

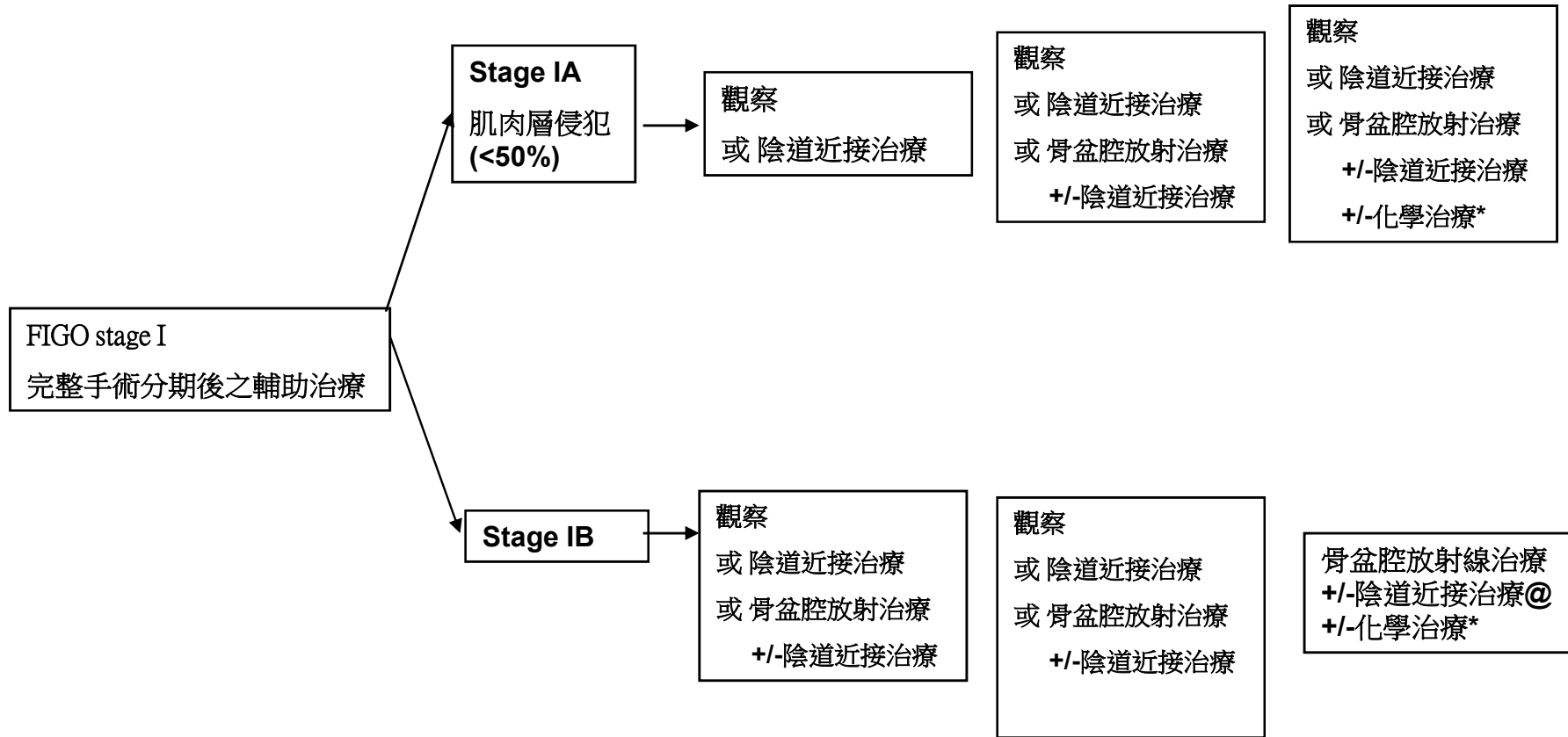
術前評估：病史 身體檢查 血液檢查 子宮頸內頸暨子宮內膜切片 子宮頸細胞學檢查 胸部X光*，核磁共振*或電腦斷層*或正子掃描，腫瘤指標(CEA,CA-125,CA-199)
*與期別相關之主要檢查(必要項目)



流程圖三

*完整手術定義：全子宮切除（或子宮根除術，或骨盆腔臟器切除手術）±兩側卵巢輸卵管切除併後腹腔淋巴節摘除（骨盆及主動脈旁）及腹腔內沖洗液細胞學檢查 ±網膜切除

G1 (分化良好) G2 (分化中等) G3 (分化不良)

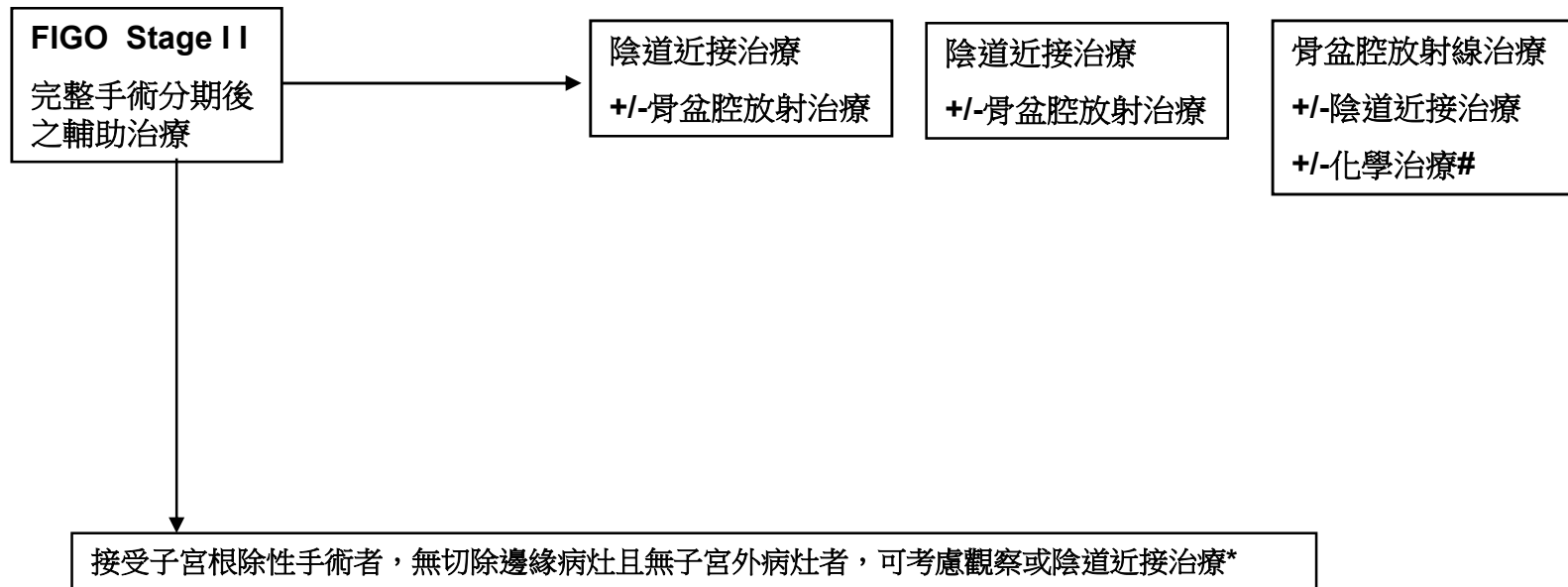


@骨盆腔放射治療 +/- 陰道近接治療 +/-化學治療：可考慮用於下列復發風險高之情況，其危險因子包括：年齡60歲以上、淋巴血管腔侵襲、較大腫瘤（2公分以上）、子宮下段侵襲。

*：仍未定論：若年輕女性考慮生活品質想避免因放射治療引起的性功能障礙可考慮使用化學治療

流程圖四

G1 (分化良好) G2 (分化中等) G3 (分化不良)



*：觀察或陰道近接治療-可選擇在根除性子宮除後邊緣無病灶，且無子宮外病灶

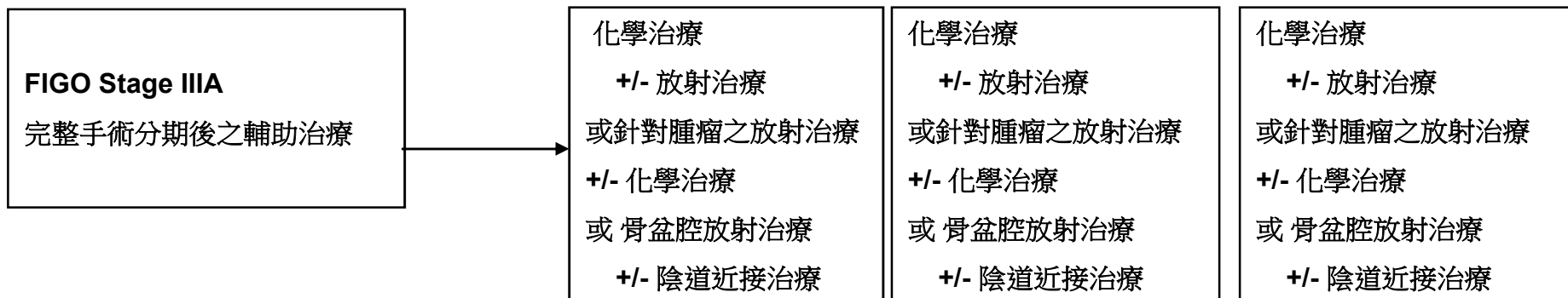
#：尚未定論：若年輕女性考慮生活品質想避免因放射治療引起的性功能障礙可考慮使用化學治療

流程圖五

G1(分化良好)

G2(分化中等)

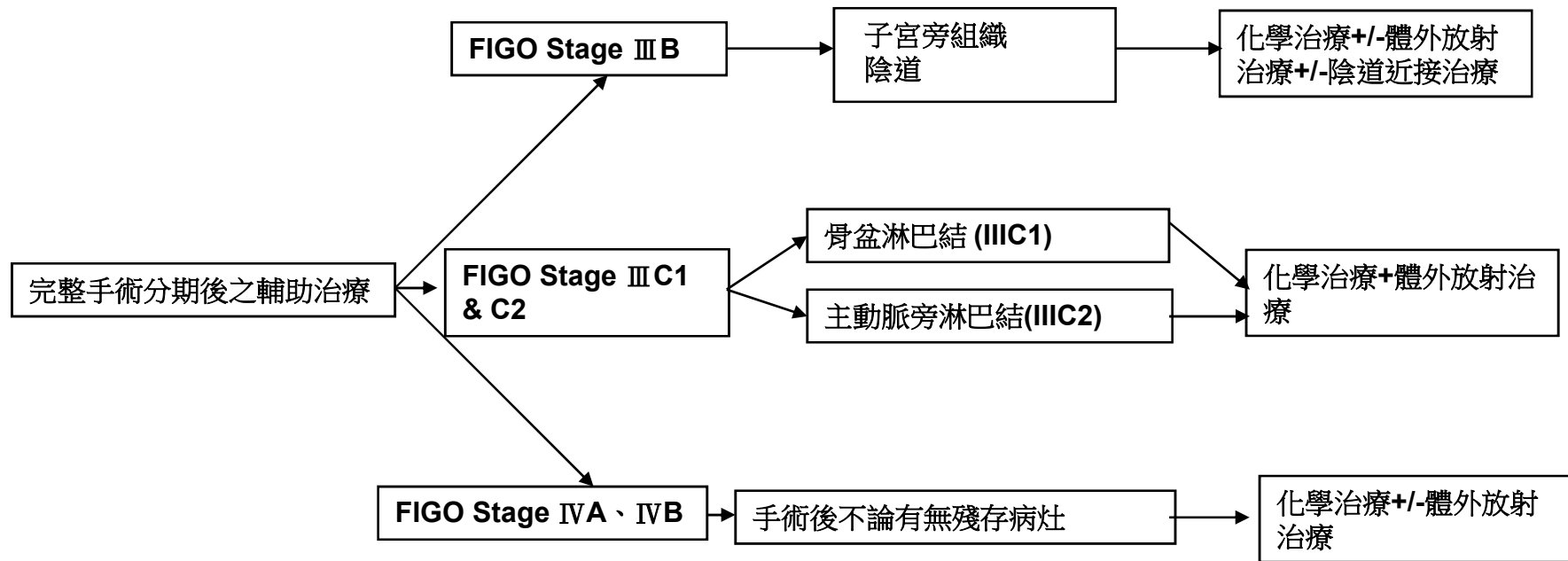
G3(分化不良)



流程圖六

任何分化程度

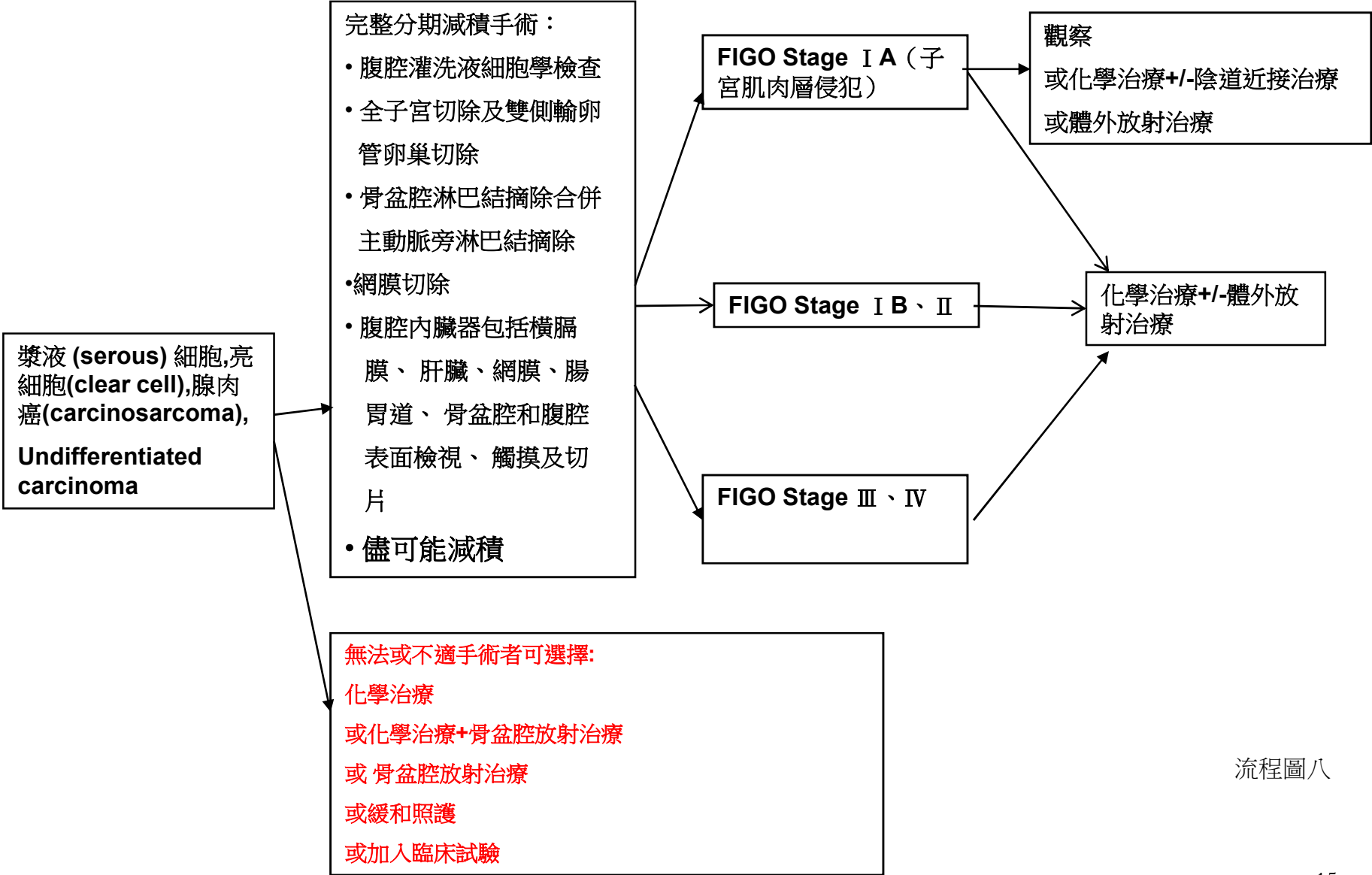
輔助治療



若有嚴重內科合併症或不適合上述治療者，可以使用荷爾蒙治療

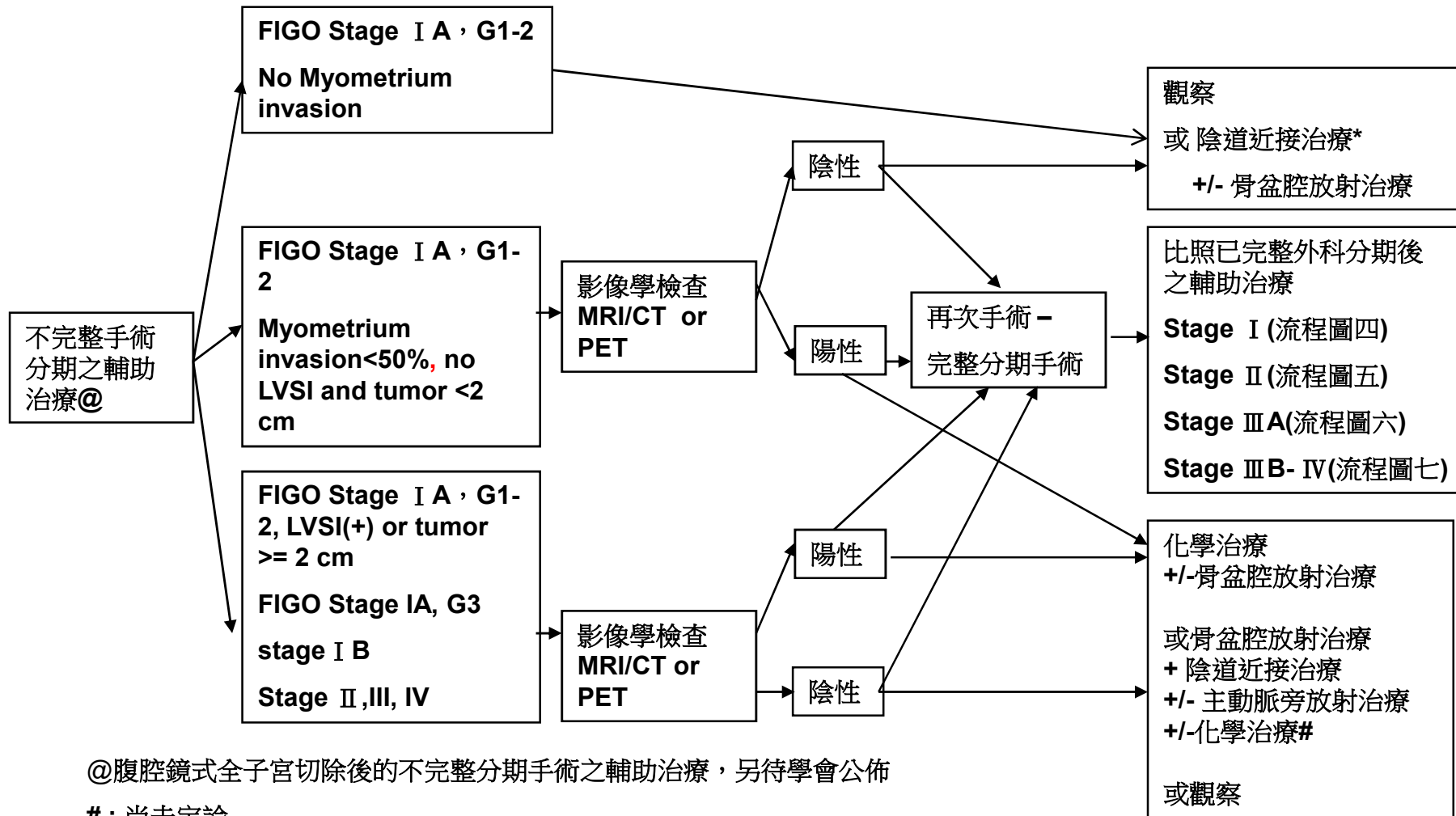
流程圖七

輔助治療



流程圖八

不完全分期手術 (或意外發現) 僅子宮切除 或 +/- 雙側 / 單側輸卵管卵巢切除



@腹腔鏡式全子宮切除後的不完整分期手術之輔助治療，另待學會公佈

#：尚未定論

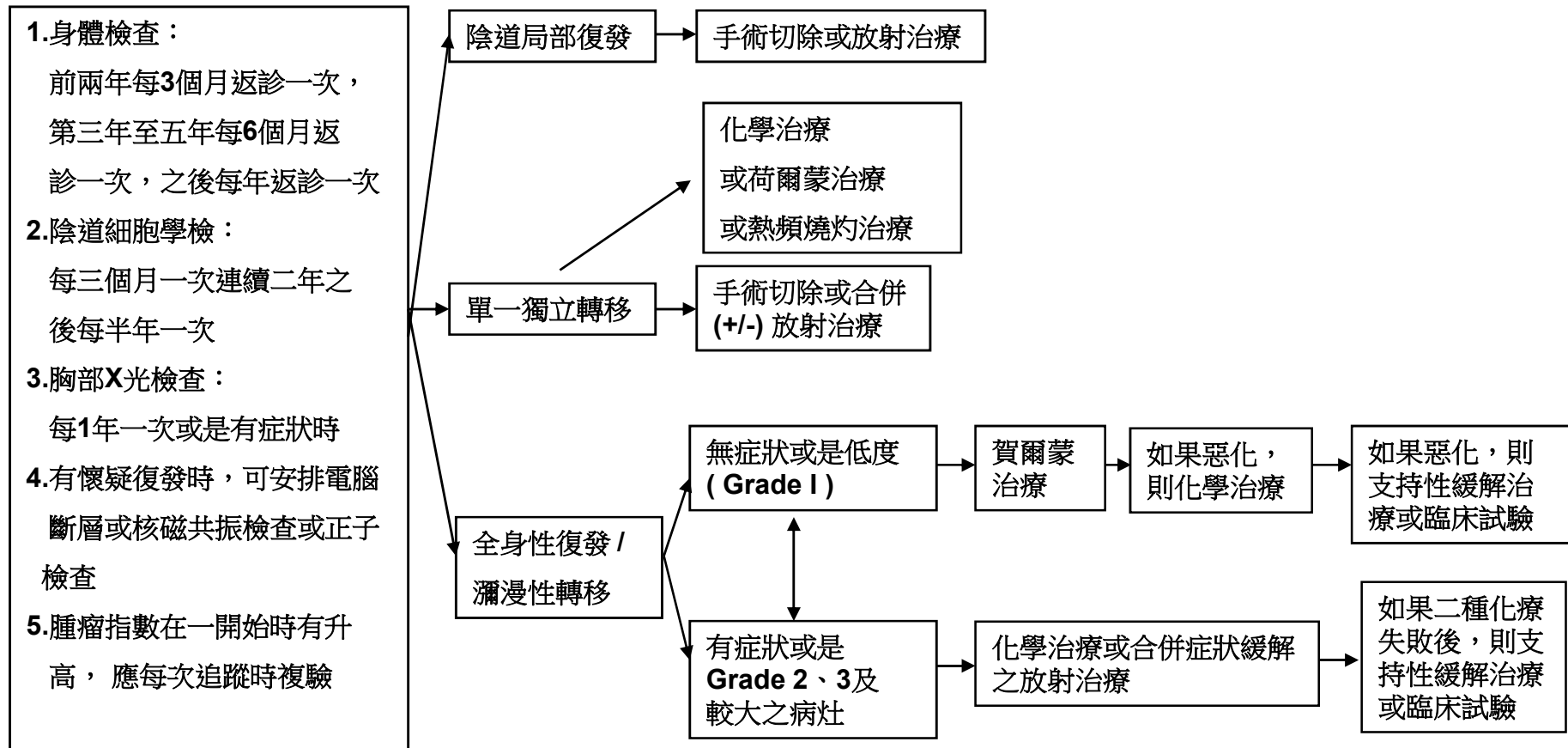
*: 腫瘤大小，年紀，腫瘤在下段

流程圖九

追蹤監測

復發轉移的臨床表徵

援救治療



流程圖十

化療使用原則可使用以下配方

1. Taxol (payself)(175mg/m²)+Carboplatin(AUC 5)-Ccr.< 60ml/min
Taxol (payself)(175mg/m²)+Cisplatin(50mg/m²) -Ccr.> 60ml/min (23)
2. PEI (Epirubicine 為optional): (8)
Epirubicine(50mg/m²)+Carboplatin(AUC=5)+Ifosfamide+mesna(4gm/m²) - Ccr<60ml/min
Epirubicine(50mg/m²)+Cisplatin(50mg/m²)+Ifosfamide+mesna(4gm/m²) -Ccr>60ml/min
3. Topotecan(0.75mg/m²) +Carboplatin(AUC=5)-Ccr.< 60ml/min (30,31)
Topotecan(0.75mg/m²) +Cisplatin(50mg/m²)-Ccr.> 60ml/min
4. PLD (payself) (30 mg/m²)+ Cisplatin(50mg/m²)-Ccr.> 60ml/min(32,33)
PLD (payself) (30 mg/m²)+ Carboplatin(AUC=5)-Ccr.< 60ml/min (32,33)
5. PLD (payself) (40 mg/m²) (32,33)
6. Weekly Topotecan (4mg/m²)(34)
7. Avastin (payself)(5~15mg/kg) (29)

化療使用原則(針對復發性、轉移性及高風險性)可使用以下配方

1. Taxol (payself)(175mg/m²)+Carboplatin(AUC 5)-Ccr.< 60ml/min
Taxol (payself)(175mg/m²)+Cisplatin(50mg/m²) -Ccr.> 60ml/min (23)
2. PEI (Epirubicine 為 optional) (8)
Epirubicine(50mg/m²)+Carboplatin(AUC=5)+Ifosfamide+mesna(4gm/m²)
Epirubicine(50mg/m²)+Cisplatin(50mg/m²)+Ifosfamide+mesna(4gm/m²)
3. Topotecan(0.75mg/m²) +Carboplatin(AUC=5)-Ccr.< 60ml/min (30,31)
Topotecan(0.75mg/m²) +Cisplatin(50mg/m²)-Ccr.> 60ml/min
4. PLD (payself) (30 mg/m²)+ Cisplatin(50mg/m²)-Ccr.> 60ml/min(32,33)
PLD (payself) (30 mg/m²)+ Carboplatin(AUC=5)-Ccr.< 60ml/min (32,33)
5. PLD (payself) (40 mg/m²) (32,33)
6. Avastin (payself)(5~15mg/kg) (29)
7. Weekly Topotecan (4mg/m²)(34)
8. Pembrolizumab(Keytruda) (200mg) (35) (**For MSI-H/dMMR tumor**)

賀爾蒙治療使用原則可使用以下配方

Medroxyprogesterone acetate (Farlutal) 500mg 1# qd ⁽²⁷⁾

Megestrol 160 mg/qd

Levonorgestrel IUD (For fertility sparing)

Letrozole 2.5mg 1# qd ⁽²⁸⁾

Tamoxifen 10mg 1# bid ⁽²⁶⁾

參考文獻

- 1. NCCN (national Comprehensive cancer network) Practice guideline in oncology, 2017.
- 2. Benedetti Panici P, Basile S, Maneschi F, Alberto Lissoni A, Signorelli M, Scambia G, et al. Systematic pelvic lymphadenectomy vs. no lymphadenectomy in early-stage endometrial carcinoma: randomized clinical trial. *J Natl Cancer Inst* 2008;100:1707–16.
- 3. ASTEC study group Kitchener H, Swart AM, Qian Q, Amos C, Parmar MK. Efficacy of systematic pelvic lymphadenectomy in endometrial cancer (MRC ASTEC trial): a randomised study. *Lancet* 2009;373:125–36.
- 4. Aalders J, Abeler V, Kolstad P, Onsrud M. Postoperative external irradiation and prognostic parameters in stage I endometrial carcinoma: clinical and histopathologic study of 540 patients. *Obstet Gynecol* 1980;56:419–27.
- 5. Creutzberg CL, van Putten WL, Wárlám-Rodenhuis CC, van den Bergh AC, de Winter KA, Koper PC, et al. Outcome of high-risk stage IC, grade 3, compared with stage I endometrial carcinoma patients: the postoperative radiation therapy in endometrial carcinoma trial. *J Clin Oncol* 2004;22:1234–41.
- 6. Keys HM, Roberts JA, Brunetto VL, Zaino RJ, Spirtos NM, Bloss JD, et al. A phase III trial of surgery with or without adjunctive external pelvic radiation therapy in intermediate risk endometrial adenocarcinoma: a Gynecologic Oncology Group study. *Gynecol Oncol* 2004;92:744–51.
- 7. Lee CM, Szabo A, Shrieve DC, Macdonald OK, Gaffney DK. Frequency and effect of adjuvant radiation therapy among women with stage I endometrial adenocarcinoma. *JAMA* 2006;295:389–97.
- 8. Randall ME, Filiaci VL, Muss H, Spirtos NM, Mannel RS, Fowler J, et al. Randomized phase III trial of whole-abdominal irradiation versus doxorubicin and cisplatin chemotherapy in advanced endometrial carcinoma: a Gynecologic Oncology Group study. *J Clin Oncol* 2006;24:36–44.
- 9. Susumu N, Sagae S, Udagawa Y, Niwa K, Kuramoto H, Satoh S, et al. Randomized phase III trial of pelvic radiotherapy versus cisplatin-based combined chemotherapy in patients with intermediate- and high-risk endometrial cancer: a Japanese Gynecologic Oncology Group study. *Gynecol Oncol* 2008;108:226–33.
- 10. Homesley HD, Filiaci V, Gibbons SK, Long HJ, Cella D, Spirtos NM, et al. A randomized phase III trial in advanced endometrial carcinoma of surgery and volume directed radiation followed by cisplatin and doxorubicin with or without cisplatin: a Gynecologic Oncology Group study. *Gynecol Oncol* 2009;112:543–52.
- 11. Kwon JS, Carey MS, Cook EF, Qiu F, Paszat L. Patterns of practice and outcomes in intermediate- and high-risk stage I and II endometrial cancer: a population-based study. *Int J Gynecol Cancer*. 2007;17:433–40.
- 12. Mariani A, Dowdy SC, Cliby WA, Gostout BS, Jones MB, Wilson TO, et al. Prospective assessment of lymphatic dissemination in endometrial cancer: a paradigm shift in surgical staging. *Gynecol Oncol*. 2008;109:11–8.
- 13. Orr JW Jr, Taylor PT Jr. Surgical management of endometrial cancer: how much is enough? *Gynecol Oncol*. 2008;109:1–3.

參考文獻

- 14. Greven K, Winter K, Underhill K, Fontenesi J, Cooper J, Burke T. Final analysis of RTOG 9708: adjuvant postoperative irradiation combined with cisplatin/paclitaxel chemotherapy following surgery for patients with high-risk endometrial cancer. *Gynecol Oncol.* 2006;103:155-9.
- 15. Hogberg T, Rosenberg P, Kristensen G, de Oliveira CF, de Pont Christensen R, Sorbe B, et al. A randomized phase-III study on adjuvant treatment with radiation (RT)/- chemotherapy (CT) in early stage high-risk endometrial cancer (NSGO-EC-9501/EORTC 55991 [abstract 5503]. *J Clin Oncol.* 2007;25:S18.
- 16. Nout RA, Putter H, Jurgenliemk-Schulz IM, Jobsen JJ, Lutgens LC, van der Steen-Banasik EM, Mens JW, et al. Vaginal brachytherapy versus external beam pelvic radiotherapy for high-intermediate risk endometrial cancer: Results of the randomized PORTEC-2 trial [abstract LBA5503]. *J Clin Oncol.* 2008;26 Suppl.
- 17. Hamilton CA, Cheung MK, Osann K, Chen L, Teng NN, Longacre TA, et al. Uterine papillary serous and clear cell carcinomas predict for poorer survival compared to grade 3 endometrioid corpus cancers. *Br J Cancer.* 2006; 94:642-6.
- 18. Frei KA, Kinkel K, Bonél HM, Lu Y, Zaloudek C, Hricak H. Prediction of deep myometrial invasion in patients with endometrial cancer: clinical utility of contrast-enhanced MR imaging—a meta-analysis and Bayesian analysis. *Radiology.* 2000;216:444-9.
- 19. Manfredi R, Mirk P, Maresca G, Margariti PA, Testa A, Zannoni GF, et al. Local-regional staging of endometrial carcinoma: role of MR imaging in surgical planning. *Radiology.* 2004;231:372-8.
- 20. Gallion HH, Brunetto VL, Cibull M, Lentz SS, Reid G, Soper JT, et al. Randomized phase III trial of standard timed doxorubicin plus cisplatin versus circadian timed doxorubicin plus cisplatin in stage III and IV or recurrent endometrial carcinoma: a Gynecologic Oncology Group study. *J Clin Oncol.* 2003;21:3808-13.
- 21. Aapro MS, van Wijk FH, Bolis G, Chevallier B, van der Burg ME, Poveda A, et al. Doxorubicin versus doxorubicin and cisplatin in endometrial carcinoma: definitive results of a randomised study (55872) by the EORTC Gynaecological Cancer Group. *Ann Oncol.* 2003;14:441-8.
- 22. Thigpen JT, Brady MF, Homesley HD, Malfetano J, DuBeshter B, Burger RA, et al. Phase III trial of doxorubicin with or without cisplatin in advanced endometrial carcinoma: a Gynecologic Oncology Group study. *J Clin Oncol.* 2004;22:3902-8.
- 23. Fleming GF, Filiaci VL, Bentley RC, Herzog T, Sorosky J, Vaccarello L, et al. Phase III randomized trial of doxorubicin cisplatin versus doxorubicin 24-h paclitaxel filgrastim in endometrial carcinoma: a Gynecologic Oncology Group study. *Ann Oncol.* 2004;15:1173-8.
- 24. Maggi R, Lissoni A, Spina F, Melpignano M, Zola P, Favalli G, et al. Adjuvant chemotherapy vs radiotherapy in high-risk endometrial carcinoma: results of a randomised trial. *Br J Cancer.* 2006;95:266-71.
- 25. Kuoppala T, Maenpää J, Tomas E, Puistola U, Salmi T, Grenman S, et al. Surgically staged high-risk endometrial cancer: randomized study of adjuvant radiotherapy alone vs. sequential chemo-radiotherapy. *Gynecol Oncol.* 2008;110:190-5.

參考文獻

- 26. Fiorica JV¹, Brunetto VL, Hanjani P, Lentz SS, Mannel R, Andersen W; Gynecologic Oncology Group study. Phase II trial of alternating courses of megestrol acetate and tamoxifen in advanced endometrial carcinoma: a Gynecologic Oncology Group study. Gynecol Oncol. 2004 Jan;92(1):10-4.
- 27. Thigpen JT¹, Brady MF, Alvarez RD, Adelson MD, Homesley HD, Manetta A, Soper JT, Given FT. Oral medroxyprogesterone acetate in the treatment of advanced or recurrent endometrial carcinoma: a dose-response study by the Gynecologic Oncology Group. J Clin Oncol. 1999 Jun;17(6):1736-44.
- 28. Ramirez PT¹, Schmeler KM, Milam MR, Slomovitz BM, Smith JA, Kavanagh JJ, Deavers M, Levenback C, Coleman RL, Gershenson DM. Efficacy of letrozole in the treatment of recurrent platinum- and taxane-resistant high-grade cancer of the ovary or peritoneum. Gynecol Oncol. 2008 Jul;110(1):56-9. doi: 10.1016/j.ygyno.2008.03.014. Epub 2008 May 5.
- 29. Viswanathan AN¹, Lee H², Berkowitz R³, Berlin S⁴, Campos S⁴, Feltmate C³, Horowitz N³, Muto M³, Sadow CA⁵, Matulonis U⁴. A prospective feasibility study of radiation and concurrent bevacizumab for recurrent endometrial cancer. Gynecol Oncol. 2014 Jan;132(1):55-60. doi: 10.1016/j.ygyno.2013.10.031. Epub 2013 Nov 4.
- 30. Hall JB, Higgins RV, Naumann RW et al. Phase II study of topotecan and cisplatin stages III and IV or for recurrent endometrial cancer. *Proc Am Soc Clin Oncol* 2000;19:409a
- 31. Fiorica JV. Update on the treatment of cervical and uterine carcinoma: focus on topotecan. Oncologist. 2002;7 Suppl 5:36-45.
- 32. Justin M. Julius, PharmD, Janos L. Tanyi, MD, PhD, Graciela M. Noguera-Gonzalez, MPH, Jack L. Watkins, PharmD, Robert L. Coleman, MD, Judith K. Wolf, MD, and Judith A. Smith, PharmD, BCOP, CPHQ, FCCP, FISOPP. Evaluation of pegylated liposomal doxorubicin dose on the adverse drug event profile and outcomes in treatment of recurrent endometrial cancer. *International journal of gynecological cancer*. 2013 Feb;23(2):348-354.
- 33. A. du Bois, J. Pfisterer, N. Burchardi, S. Loibl, J. Huober, P. Wimberger, A. Burges, A. Stahle, C. Jackisch, H. Kolbl. Combination therapy with pegylated liposomal doxorubicin and carboplatin in gynecologic malignancies: A Arbeitsgemeinschaft gynaekologische onkologie studiengruppe ovariakarzinom and kommission uterus. *Gynecologic Oncology*. 2007 Oct; 107:518-525.
- 34. Traina TA¹, Sabbatini P, Aghajanian C, Dupont J. Weekly topotecan for recurrent endometrial cancer: a case series and review of the literature. Gynecol Oncol. 2004 Oct;95(1):235-41.
- 35. Arend RC¹, Jones BA², Martinez A³, Goodfellow P⁴. Endometrial cancer: Molecular markers and management of advanced stage disease. Gynecol Oncol. 2018 Sep;150(3):569-580. doi: 10.1016/j.ygyno.2018.05.015. Epub 2018 May 27.