

高雄榮民總醫院

子宮頸癌診療原則

2019年10月24日 第二版

婦癌醫療團隊擬訂

注意事項：這個診療原則主要作為醫師和其他保健專家診療癌症病人參考之用。假如你是一個癌症病人，直接引用這個診療原則並不恰當，只有你的醫師才能決定給你最恰當的治療。

修訂指引

- 本共識依下列參考資料修改版本
 - NCCN Clinical Practical Guidelines in Oncology™ Cervical Cancer (V. 2019)⁽¹⁾
 - 婦癌研究委員會(2011)，子宮頸癌篩檢臨床指引與子宮頸癌臨床指引：國家衛生研究院⁽²⁻³⁾
 - 其他相關子宮頸癌臨床指引⁽⁴⁻¹⁰⁾

會議討論

上次會議：2019/01/22

本共識與上一版的差異

上一版	新版
<ol style="list-style-type: none">1. 原為 2014 FIGO分期(p. 4-5)2. 流程圖一在FIGO IB1分期治療，與FIGO IB2分期治療流程不同，原無FIGO IB3分期 (p. 8)3. 流程圖二在FIGO IB流程原只有FIGO IB2分期，無FIGO IB3分期(p. 9)4. 化學治療部分，第IV期B，持續性疾病 /復發或轉移性疾病 之全身性化學治療的原則中陳列Gemcitabine+ Cisplatin or Carboplatin 化療處方(p. 13)5. 線上未建置Paclitaxel 175mg/m²+ topotecan 0.75mg/m² ± Bevacizumab 7.5~15mg/kg 化療處方(p. 14)	<ol style="list-style-type: none">1. 更改為 2018 FIGO分期(p. 4-6)2. 流程圖一將FIGO IB1分期治療流程增加 FIGO IB2分期，並刪除腫瘤小於2公分字眼，而原FIGO IB2分期治療流程更改為 FIGO IB3分期 (p. 8)3. 流程圖二FIGO IB2分期，更改為FIGO IB3分期(p. 9)4. 化學治療部分，刪除第IV期B，持續性疾病 /復發或轉移性疾病 之全身性化學治療的原則中之Gemcitabine+ Cisplatin or Carboplatin 化療處方(p. 13)5. 新增Paclitaxel 175mg/m²+ topotecan 0.75mg/m² ± Bevacizumab 7.5~15 mg/kg 化療處方(p. 14)

2018 FIGO staging

Stage	Description
I	The carcinoma is strictly confined to the cervix (extension to the uterine corpus should be disregarded)
IA	Invasive carcinoma that can be diagnosed only by microscopy, with maximum depth of invasion <5 mm ^a
IA1	Measured stromal invasion <3 mm in depth
IA2	Measured stromal invasion ≥3 mm and <5 mm in depth
IB	Invasive carcinoma with measured deepest invasion ≥5 mm (greater than Stage IA), lesion limited to the cervix uteri ^b
IB1	Invasive carcinoma ≥5 mm depth of stromal invasion, and <2 cm in greatest dimension
IB2	Invasive carcinoma ≥2 cm and <4 cm in greatest dimension
IB3	Invasive carcinoma ≥4 cm in greatest dimension
II	The carcinoma invades beyond the uterus, but has not extended onto the lower third of the vagina or to the pelvic wall
IIA	Involvement limited to the upper two-thirds of the vagina without parametrial involvement
IIA1	Invasive carcinoma <4 cm in greatest dimension
IIA2	Invasive carcinoma ≥4 cm in greatest dimension
IIB	With parametrial involvement but not up to the pelvic wall
III	The carcinoma involves the lower third of the vagina and/or extends to the pelvic wall and/or causes hydronephrosis or nonfunctioning kidney and/or involves pelvic and/or para-aortic lymph nodes ^c
IIIA	The carcinoma involves the lower third of the vagina, with no extension to the pelvic wall
IIIB	Extension to the pelvic wall and/or hydronephrosis or nonfunctioning kidney (unless known to be due to another cause)
IIIC	Involvement of pelvic and/or para-aortic lymph nodes, irrespective of tumor size and extent (with r and p notations) ^c
IIIC1	Pelvic lymph node metastasis only
IIIC2	Para-aortic lymph node metastasis
IV	The carcinoma has extended beyond the true pelvis or has involved (biopsy proven) the mucosa of the bladder or rectum. (A bullous edema, as such, does not permit a case to be allotted to Stage IV)
IVA	Spread to adjacent pelvic organs
IVB	Spread to distant organs

When in doubt, the lower staging should be assigned.

^aImaging and pathology can be used, where available, to supplement clinical findings with respect to tumor size and extent, in all stages.

^bThe involvement of vascular/lymphatic spaces does not change the staging. The lateral extent of the lesion is no longer considered.

^cAdding notation of r (imaging) and p (pathology) to indicate the findings that are used to allocate the case to Stage IIIC. Example: If imaging indicates pelvic lymph node metastasis, the stage allocation would be Stage IIIC1r, and if confirmed by pathologic findings, it would be Stage IIIC1p. The type of imaging modality or pathology technique used should always be documented.

Source: Bhatla et al.¹⁷

Cervix Uteri AJCC 第八版

Primary Tumor		
T		T Criteria
TX		Primary tumor cannot be assessed
T0		No evidence of primary tumor
T1		The carcinoma is strictly confined to the cervix (extension to the uterine corpus should be disregarded)
T1a		Invasive carcinoma that can be diagnosed only by microscopy, with maximum depth of invasion
	T1a1	Measured stromal invasion <3 mm in depth or <7 mm in horizontal spread
	T1a2	Measured stromal invasion ≥3 mm and <5 mm in depth, with <7 mm in horizontal spread
T1b		Clinically visible lesion confined to the cervix or microscopic lesion greater than T1a/IA2. Includes all macroscopically visible lesions, even those with superficial invasion.
	T1b1	Clinically visible lesion <4 cm in greatest dimension
	T1b2	Clinically visible lesion ≥4 cm in greatest dimension
T2		The carcinoma invades beyond the uterus, but has not extended onto the lower third of the vagina or to the pelvic wall
T2a		Involvement limited to the upper two-thirds of the vagina without parametrial involvement
	T2a1	Invasive carcinoma <4 cm in greatest dimension
	T2a2	Invasive carcinoma ≥4 cm in greatest dimension
T2b		With parametrial involvement but not up to the pelvic wall
T3		The carcinoma involves the lower third of the vagina and/or extends to the pelvic wall and/or causes hydronephrosis or nonfunctioning kidney
T3a		The carcinoma involves the lower third of the vagina, with no extension to the pelvic wall
T3b		Extension to the pelvic wall and/or hydronephrosis or nonfunctioning kidney (unless known to be due to another cause)
T4		The carcinoma has extended beyond the true pelvis or has involved (biopsy proven) the mucosa of the bladder or rectum. (bullous edema, as such, does not permit a case to be allotted to T4)

* The pelvic sidewall is defined as the muscle, fascia, neurovascular structures and skeletal portions of the bony pelvis. On rectal exam, there is no cancer-free space between the tumor and pelvic sidewall.

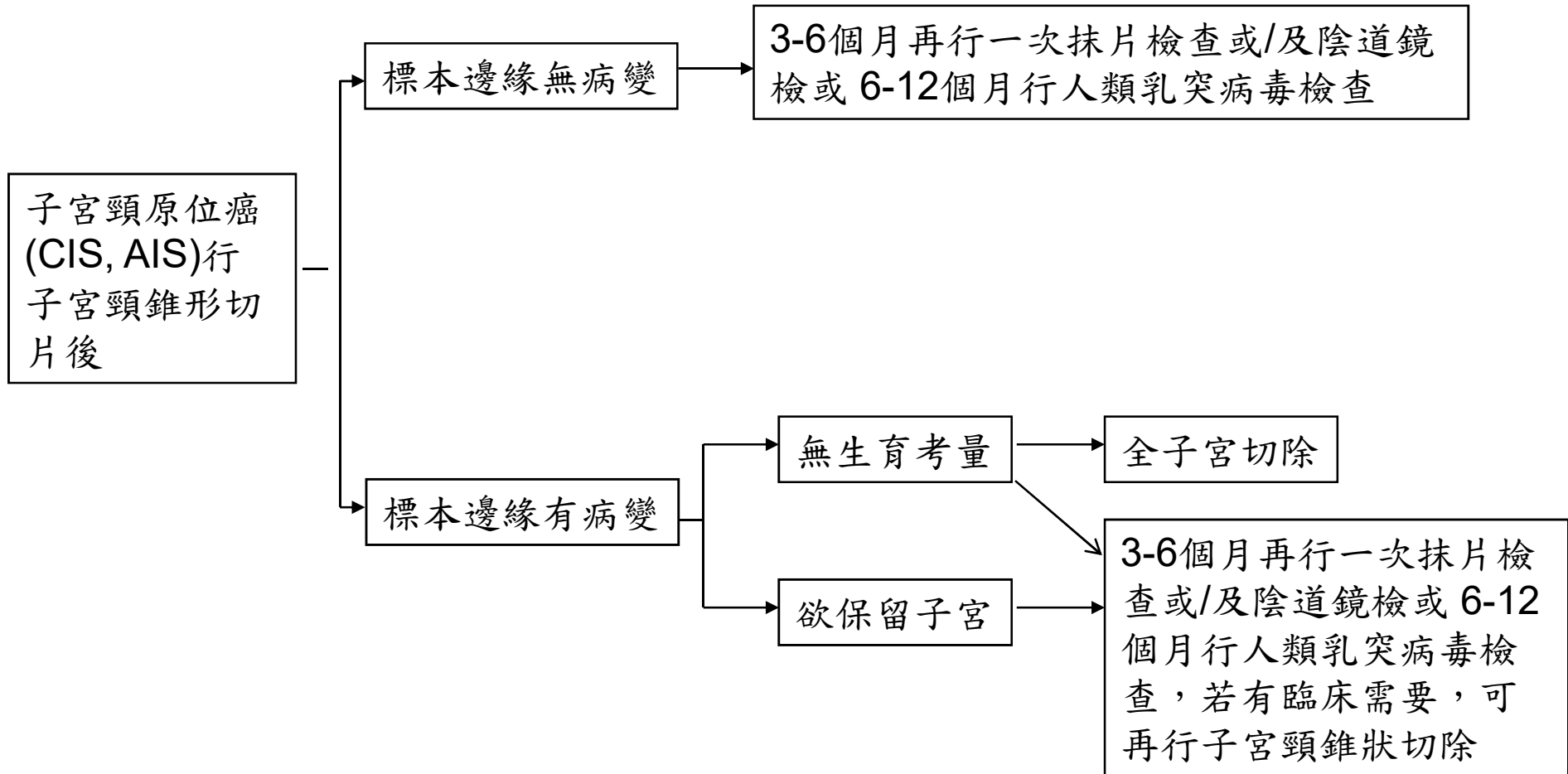
Cervix Uteri AJCC 第八版

Regional Lymph Node (N)	
N	N Criteria
NX	Regional lymph node cannot be assessed
N0	No regional lymph node metastasis
N0(i+)	Isolated tumor cells in regional lymph node(s) no greater than 0.2 mm
N1	Regional lymph node metastasis

Distant Metastasis (M)	
M	M Criteria
M0	No distant metastasis
M1	Distant metastasis (including peritoneal spread or involvement of the supraclavicular, mediastinal, or distant lymph nodes; lung; liver; or bone)

AJCC STAGE GROUPS			
T	N	M	Stage
T1	Any N	M0	I
T1a	Any N	M0	IA
T1a1	Any N	M0	IA1
T1a2	Any N	M0	IA2
T1b	Any N	M0	IB
T1b1	Any N	M0	IB1
T1b2	Any N	M0	IB2
T2	Any N	M0	II
T2a	Any N	M0	IIA
T2a1	Any N	M0	IIA1
T2a2	Any N	M0	IIA2
T2b	Any N	M0	IIB
T3	Any N	M0	III
T3a	Any N	M0	IIIA
T3b	Any N	M0	III
T4	Any N	M0	IVA
Any T	Any N	M1	IVB

高雄榮總婦癌團隊 子宮頸原位癌臨床治療指引



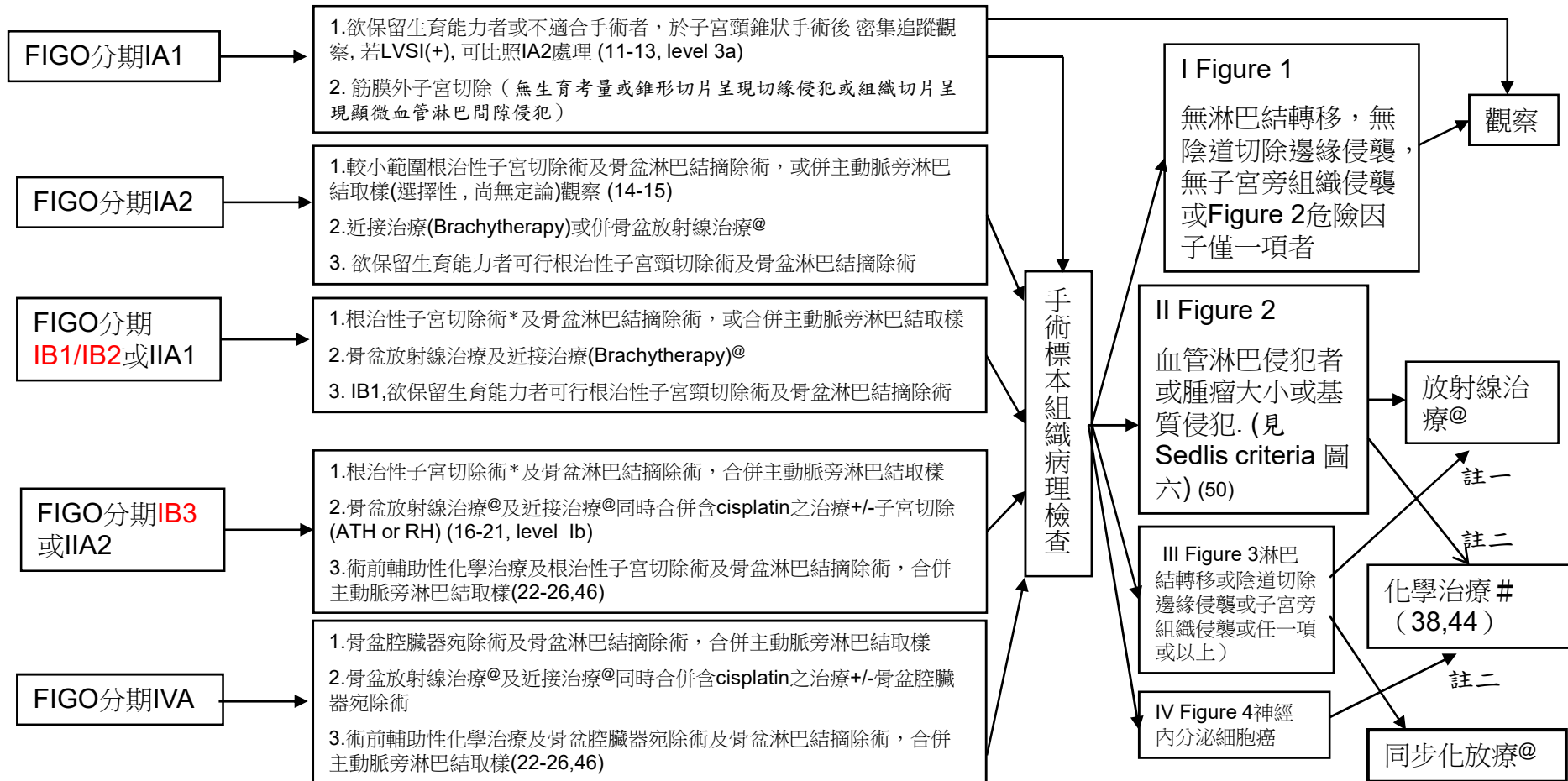
高雄榮總婦癌團隊 子宮頸癌臨床治療指引

子宮頸癌治療流程

治療前檢查：1.病史及理學檢查*；2.全血球計數；3.子宮頸切片之組織病理檢查；4.子宮頸錐狀手術+子宮頸管搔刮術(當子宮頸切片之組織病理檢查結果為微侵襲癌者)；5.胸部X光*；6.分期高於IA者，安排腹部或骨盆電腦斷層*或核磁共振*(52)；7.常規生化檢驗；8.血清腫瘤標記檢驗(鱗狀細胞癌者:SCC、CEA；腺癌者:CEA、CA-125,CA-199)

選擇性檢查：#分期為IB2或以上者，膀胱或直腸鏡檢；#葡萄糖正子攝影 *與期別相關之主要檢查(必要項目)

輔助治療



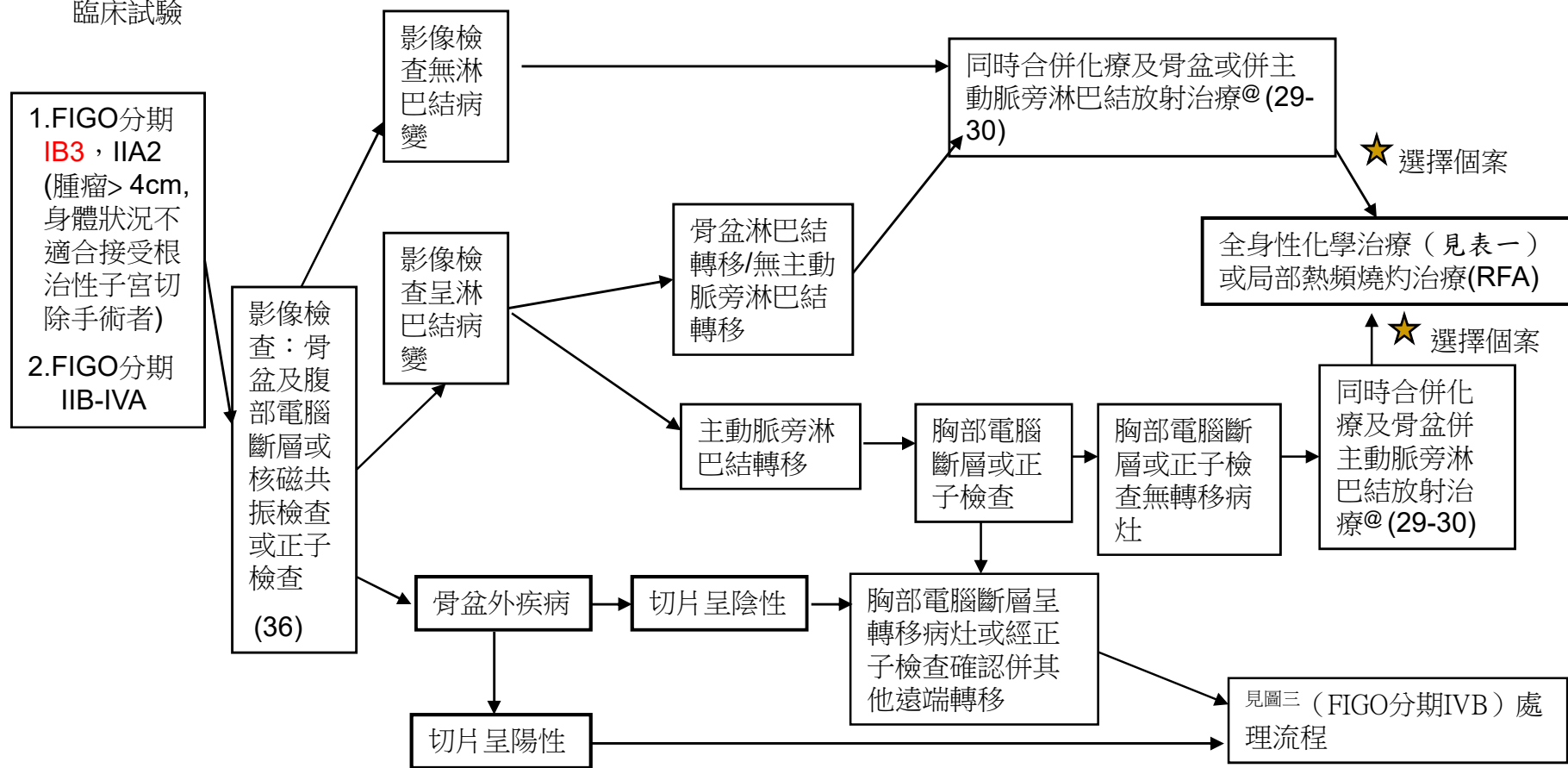
*:含神經保留式根治性子宮切除術 (nerve sparing radical hysterectomy)；#:請見表一；註一：病患年紀太大或合併多重內科疾病者；註二：年輕女性考慮避免性功能障礙者或接受過放射線治療者；@: 放射治療、近接治療或同步化放療請見放射腫瘤部治療指引

圖一

高雄榮總婦癌團隊 子宮頸癌臨床治療指引

FIGO分期IIB-IVA(局部晚期)子宮頸癌，或不適合施行根治性子宮切除手術之IB、IIA治療流程

- 1.放射治療包括體外放射治療及近接治療[@]
- 2.同步化放療時使用含cisplatin 40 mg/m² /carboplatin 100 mg/m² or AUC2 weekly x 6 courses（或配合放療療程）之化療或臨床試驗

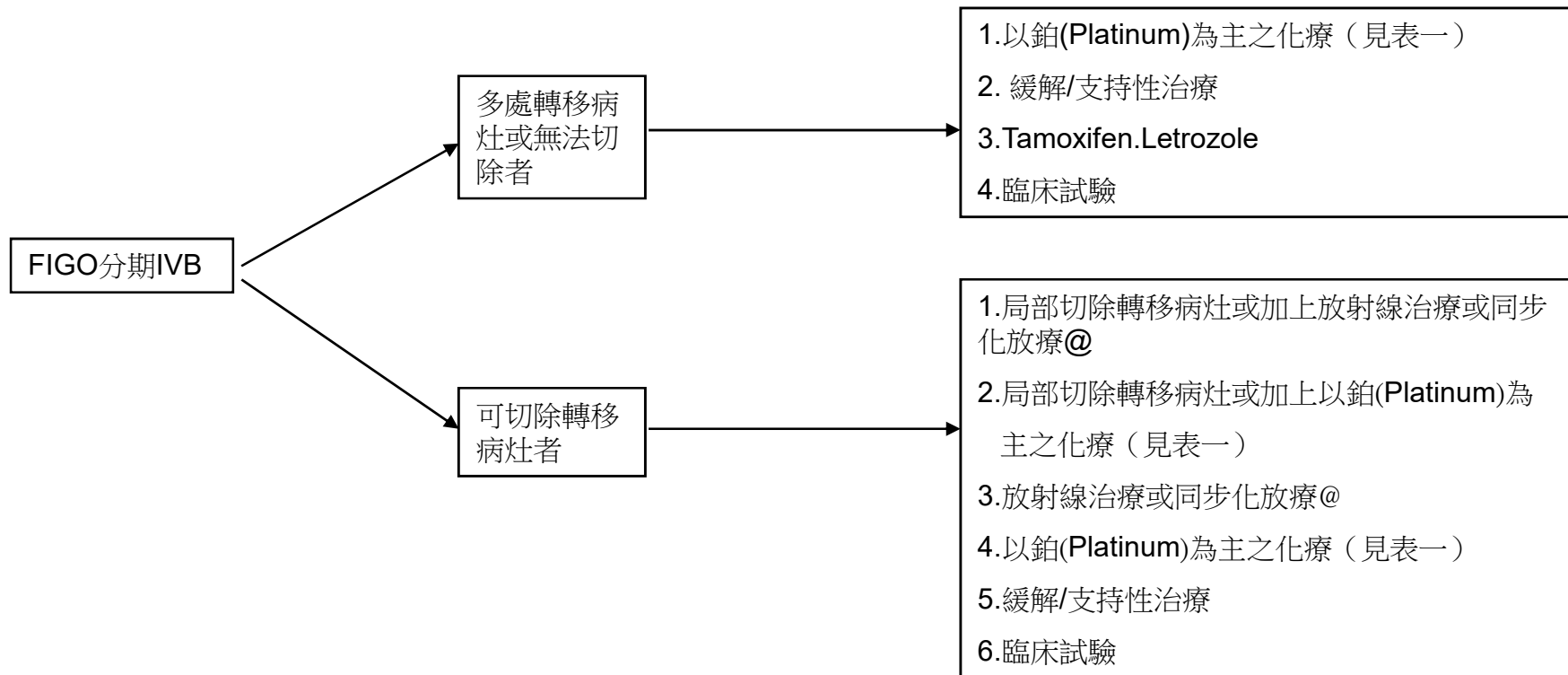


[@]：放射治療或同步化放療及併主動脈旁淋巴結放射治療請見放射腫瘤部治療指引

★：仍有residual tumor

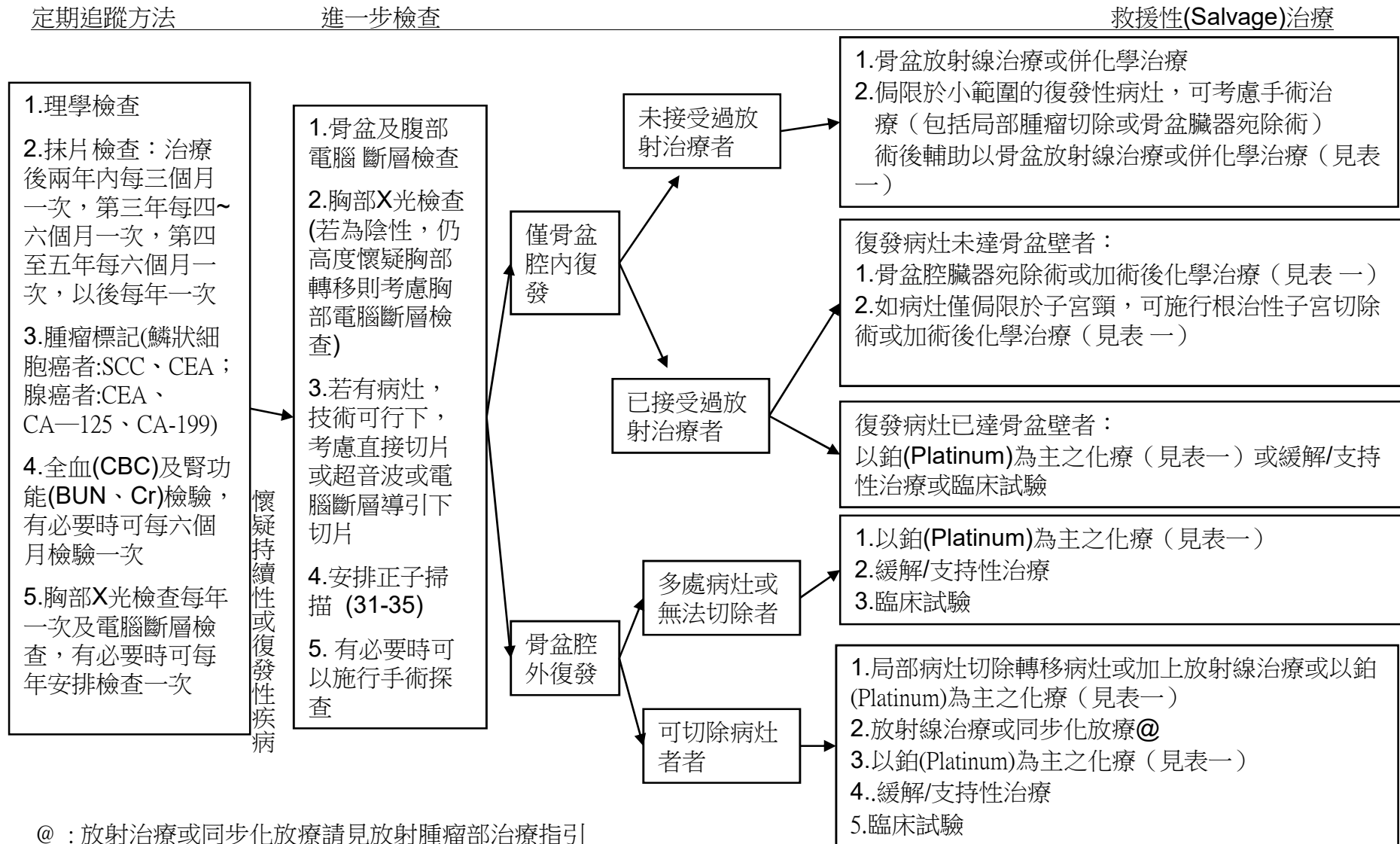
圖二

FIGO分期IVB(遠端轉移)子宮頸癌治療流程



高雄榮總婦癌團隊 子宮頸癌臨床治療指引

子宮頸癌治療後追蹤及復發的處置

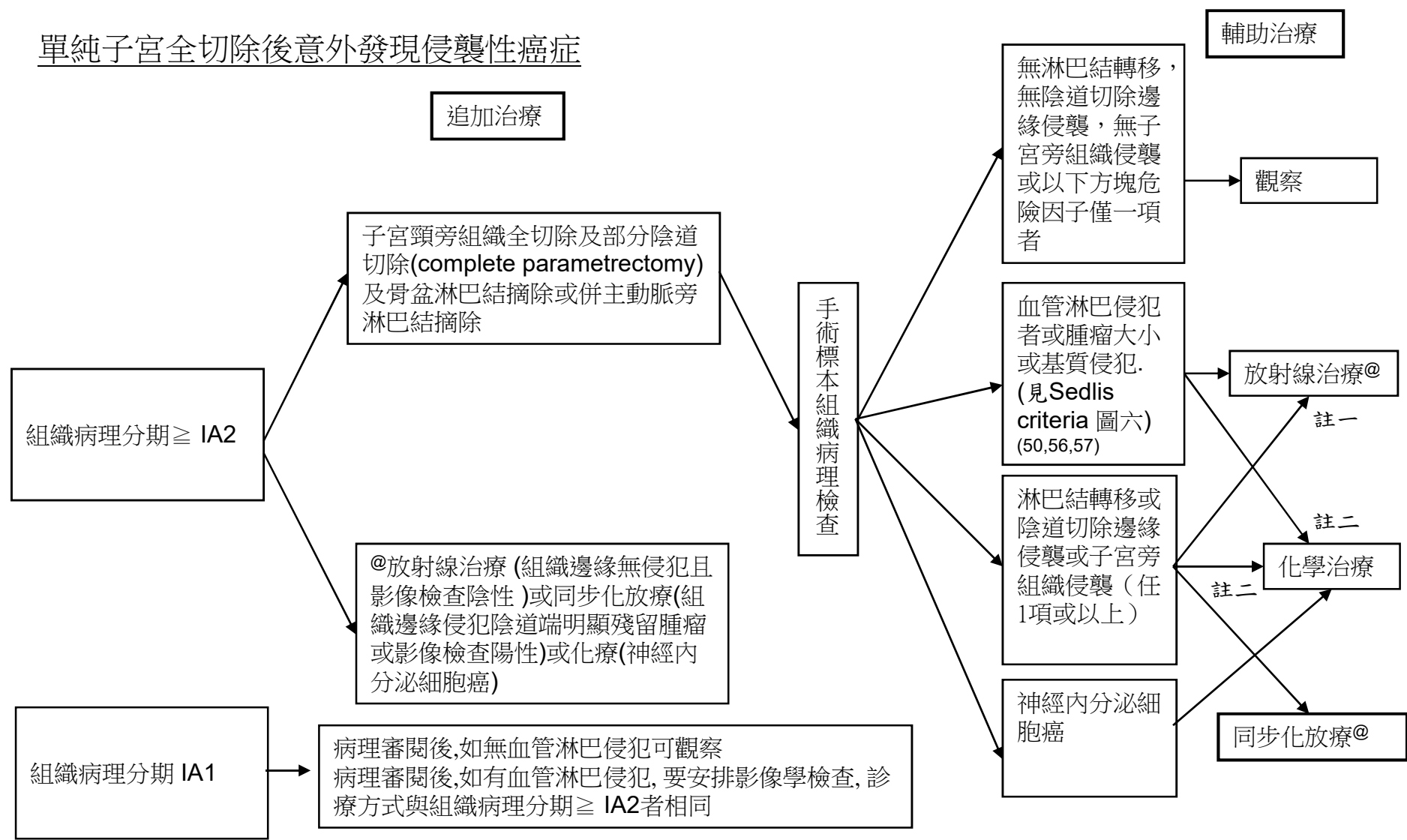


@：放射治療或同步化放療請見放射腫瘤部治療指引

圖四

高雄榮總婦癌團隊 子宮頸癌臨床治療指引

單純子宮全切除後意外發現侵襲性癌症



#:請見表一；註一：病患年紀太大或合併多重內科疾病者；註二：年輕女性考慮避免性功能障礙者或接受過放射線治療者；
@: 放射治療或同步化放療請見放射腫瘤部治療指引

圖五

SEDLIS CRITERIA FOR EXTERNAL PELVIC RADIATION AFTER RADICAL HYSTERECTOMY IN NODE-NEGATIVE, MARGIN-NEGATIVE, PARAMETRIA-NEGATIVE CASES^{1,2,3,4}

LVSI	Stromal Invasion	Tumor Size (cm) (Determined by clinical palpation)
+	Deep 1/3	Any
+	Middle 1/3	≥2
+	Superficial 1/3	≥5
-	Middle or Deep 1/3	≥4

LVSI: Lymphovascular space invasion

高雄榮總婦癌團隊 子宮頸癌臨床治療指引-化學治療或同步化學與放射治療

術前新輔助化學治療：以 platinum-based 為原則，可使用以下的選擇

- 1.IP (ifosfamide 4 gm/m²+cisplatin 50mg/m² or carboplatin AUC=5 every 21 days x 3~6 cycles)(48,49)
- 2.Irinotecan 60mg/m²+cisplatin 50mg/m² or carboplatin AUC=5 every 28 days x 3~6 cycles (optional)(43,47)
- 3.(IB2-IIB) weekly Taxol + Carboplatin(AUC=2) (D1,D8,D15)x 9 cycles(58)
- 4.Clinical trials

手術後輔助化學治療：以 platinum-based 為原則，可使用以下的選擇

- 1.IP (ifosfamide 4 gm/m²+cisplatin 50mg/m² or carboplatin AUC=5 every 21 days x 6 cycles) (38,45,49)
- 2.Clinical trials

神經內分泌癌手術後輔助化學治療或化放療以 platinum-based 為原則可使用以下的選擇

- 1.VP-16/cyclophosphamide/platinum (VP-16 100mg/m²+cyclophosphamide 500mg/m²+cisplatin 50mg/m² or carboplatin AUC=5 every 21 days x 6 cycles) (53,54)

第IV期B，持續性疾病 (persistent disease)復發或轉移性疾病 (recurrent/metastatic disease) 之全身性化學治療或免疫療法為原則，可使用以下的選擇

- 1.Topotecan 0.75mg/m² x 3 days+ cisplatin 50mg/m² or carboplatin AUC=5 every 21 days x 6 cycles(GOG 179, level Ib) (42) ± Bevacizumab 7.5~15 mg/kg
- 2.IP (ifosfamide 4gm/m²+cisplatin 50mg/m² or carboplatin AUC=5 every 21 days x 6 cycles)(GOG 110, level Ib)
- 3.Paclitaxel 175mg/m²+ cisplatin 50mg/m² or carboplatin AUC=5 every 21 days x 6 cycles)(optional)(GOG 169, GOG 204, level Ib) (51) ± Bevacizumab 7.5~15 mg/kg (GOG 240) (55)
- 4.Irinotecan/platinum (Irinotecan 60mg/m²+cisplatin 50mg/m² or carboplatin AUC=5 every 28 days x 6 cycles) (optional) (43,47)
5. Paclitaxel 175mg/m²(D1)+ topotecan 0.75mg/m²(D1-3) ±Bevacizumab 7.5~15 mg/kg(D1) every 21~28 days (63)
6. Tamoxifen 10mg QD (61,62)
7. Keytruda(Pembrolizumab) for PD-L1(+) or MSI-H/dMMR tumor ((59, 60 (KEYNOTE-028,158)) / 8.Clinical trials

同步化放療時使用含cisplatin 40 mg/m² /carboplatin 100 mg/m² or AUC2 weekly x6 cycles 之化療或臨床試驗藥物(29)

高雄榮總婦癌團隊 子宮頸癌臨床治療指引-化學治療或同步化學與放射治療

1. CCRT-CISPLATIN(40MG/M²)
2. CCRT-CARBOPLATIN(100MG/M²) OR AUC₂
3. CCRT-WEEKLY CISPLATIN(40MG/M²) + GEMCITABINE(120MG/M²)
4. P(CARBOPLATIN(AUC=5))C(CYCLOPHOSPHAMIDE (500MG/M²))+VP-16(100MG/M²)-CCR. <60ML/MIN
5. P(CISPLATIN(50MG/M²)) C+VP-16-CCR. >60ML/MIN
6. 1ST LINE. I(IFOSFAMIDE+MESNA(4GM/M²)) P(CARBOPLATIN(AUC=5))-CCR.< 60ML/MIN
7. 1ST LINE. IP(CISPLATIN(50MG/M²))-CCR.> 60ML/MIN
8. 2ND LINE. TAXOL (PAYSOLF) (175MG/M²)(D1) +TOPOTECAN(0.75MG/M²)(D1-3)

高雄榮總婦癌團隊 子宮頸癌臨床治療指引-化學治療或同步化學與放射治療

9. 2ND LINE. IRINOTECAN(PAYSELF) (60MG/M2)
+CARBOPLATIN(AUC=5) (D1)
10. 2ND LINE. IRINOTECAN(PAYSELF)(60MG/M2)+CISPLATIN
(50MG/M2) (D1)
11. 2ND LINE. IRINOTECAN(PAYSELF)(60MG/M2)-D8 OR D15
12. 2ND LINE. TAXOL (PAYSELF)(175MG/M2)+ CARBOPLATIN
(AUC=5)-CCR.< 60ML/MIN
13. 2ND LINE. TAXOL (PAYSELF) (175MG/M2) +CISPLATIN
(50MG/M2)-CCR.> 60ML/MIN
14. 2ND LINE. TOPOTECAN(0.75MG/M2) +CARBOPLATIN
(AUC=5)-CCR.< 60ML/MIN
15. 2ND LINE. TOPOTECAN (0.75MG/M2) +CISPLATIN
(50MG/M2)-CCR.> 60ML/MIN
16. WEEKLY TAXOL(80MG/M2) +CISPLATIN(20MG/M2)
(D1 OR D8 OR D15)

高雄榮總婦癌團隊 子宮頸癌臨床治療指引-化學治療或同步化學與
放射治療

17. WEEKLY TAXOL(80MG/M²) +CARBOPLATIN(AUC=2)
(D1 OR D8 OR D15)
18. AVASTIN (PAYSELF)(7.5~15MG/KG)
19. TAMOXIFEN 10mg QD
20. PEMBROLIZUMAB(KEYTRUDA)

References

- 1.NCCN Clinical Practice Guideline in Oncology™ – Cervical Cancer (V. 2019)
- 2.TGOG子宮頸癌篩檢指引| 2007年版, 國家衛生研究院
- 3. TGOG子宮頸癌臨床指引 2010年版, 國家衛生研究院 (2010/08/14 TAGO meeting in Taichung)
- 4.Jemal A, Siegel R, Ward E, et al. Cancer Statistics, 2006. CA Cancer J Clin 2006;56:106-130.
- 5.Edwards BK, Brown ML, Wingo PA, et al. Annual report to the nation on the status of cancer, 1975-2002, featuring populationbased trends in cancer treatment. J Natl Cancer Inst 2005;97:1407-1427.
- 6.Parkin DM, Bray F, Ferlay J. Global cancer statistics, 2002. CA Cancer J Clin 2005;55:74-108.
- 7.American College of Obstetricians and Gynecologists. ACOG practice bulletin. Diagnosis and treatment of cervical carcinomas. Number 35, May 2002. Int J Gynaecol Obstet 2002;78:79-91.
- 8.Chi DS. Laparoscopy in gynecologic malignancies. Oncology 1999;13:773-782.
- 9.Benedet JL, Bender H, Jones H 3rd, et al. FIGO staging classifications and clinical practice guidelines in the management of gynecologic cancers. FIGO Committee on Gynecologic Oncology. Int J Gynaecol Obstet 2000;70:209-262.
- 10.Haie-Meder C, Fervers B, Fondrinier E, et al. SOR guidelines for concomitant chemoradiotherapy for patients with uterine cervical cancers: evidence update bulletin 2004. Ann Oncol 2005;16:1100-1108.
- 11.Koliopoulos G, Sotiriadis A, Kyrgiou M, et al. Conservative surgical methods for FIGO stage IA2 squamous cervical carcinoma and their role in preserving women's fertility. Gynecol Oncol 2004;93:469-473.
- 12.Bernardini M, Barrett J, Seaward G, et al. Pregnancy outcomes in patients after radical trachelectomy. Am J Obstet Gynecol 2003;189:1378-1382.
- (Trachelectomy 保留生育力 case series)
- 13.Boss EA, van Golde RJ, Beerendonk CC, et al. Pregnancy after radical trachelectomy: A real option? Gynecol Oncol 2005;99:S152-6. Epub 2005 Sep 2.
- (Trachelectomy 保留生育力 review)
- 14.WT Creasman, RJ Zaino, FJ Major, PJ DiSaia, KD Hatch and HD Homesley, Early invasive carcinoma of the cervix (3 to 5 mm invasion): risk factors and prognosis: a Gynecologic Oncology Group study, Am J Obstet Gynecol 178 (1998), pp. 62–65.
- (Cervical cancer stage IA2)

References

- 15. WB Jones, GO Mercer, JL Lewis, SC Rubin and WJ Hoskins, Early invasive carcinoma of the cervix, *Gynecol Oncol* **51** (1993), pp. 26–32.
- **(Cervical cancer stage IA2)**
- 16. Landoni F, Maneco A, Colombo A, et al. Randomized study of radical surgery vs. radiotherapy for stage Ib-IIa cervical cancer. *Lancet* 1997;350:535-540.
- **(RH vs R/T)**
- 17. Keys HM, Bundy BN, Stehman FB, et al. Cisplatin, radiation, and adjuvant hysterectomy compared with radiation and adjuvant hysterectomy for bulky stage IB cervical carcinoma. *N Engl J Med* 1999;340:1154-1161.
- **(CCRT + Hysterectomy vs R/T + hysterectomy, IB2)**
- 18. Rose PG, M.D., Bundy BN, Watkins EB, et al. Concurrent Cisplatin-Based Radiotherapy and Chemotherapy for Locally Advanced Cervical Cancer. *N Engl J Med* 1999; 340:1144-1153.
- **(Cisplatin based CCRT for locally advanced Cx Ca)**
- 19. Morris M, Eifel PJ, Lu J, et al. Pelvic radiation with concurrent chemotherapy compared with pelvic and para-aortic radiation for high-risk cervical cancer. *N Engl J Med* 1999;340:1137-1143.
- **(Primary CCRT for locally advanced)**
- 20. Frederick B. Stehman, Shamshad Ali, Henry M. Keys et al, Radiation therapy with or without weekly cisplatin for bulky stage 1B cervical carcinoma: follow-up of a Gynecologic Oncology Group trial. *American Journal of Obstetrics and Gynecology*, Volume 197, Issue 5, November 2007, Pages 503.e1-503.e6
- **(CCRT + hysterectomy vs RT +hysterectomy)**
- 21. Henry M. Keys, Brian N. Bundy, Frederick B. Stehman et al, Radiation therapy with and without extrafascial hysterectomy for bulky stage IB cervical carcinoma: a randomized trial of the Gynecologic Oncology Group. *Gynecologic Oncology*, Volume 89, Issue 3, June 2003, Pages 343-353
- **(R/T + hysterectomy vs RT alone)**
- 22. Pierluigi Benedetti-Panici, Stefano Greggi, Alessandro Colombo et al. Neoadjuvant Chemotherapy and Radical Surgery Versus Exclusive Radiotherapy in Locally Advanced Squamous Cell Cervical Cancer: Results From the Italian Multicenter Randomized Study. *JCO* Jan 1 2002: 179-188.
- **(Neoadjuvant C/T + RH vs Pelvic RT in Locally advanced)**

References

- 23. Ting-Chang Chang, Chyong-Huey Lai, Ji-Hong Hong et al. Randomized trial of neoadjuvant cisplatin, vincristine, bleomycin, and radical hysterectomy versus radiation therapy for bulky stage IB and IIA cervical cancer. *Journal of Clinical Oncology*, Vol 18, Issue 8 (April), 2000: 1740-1747
(Neoadjuvant C/T + RH vs Pelvic RT in Locally advanced)
- 24. Sardi J, Sananes C, Giaroli A et al. Results of a prospective randomized trial with neoadjuvant chemotherapy in stage IB, bulky, squamous carcinoma of the cervix. *Gynecol Oncol*. 1993 May;49(2):156-65
(Neoadjuvant C/T + RH)
- 25. Juan E. Sardi, Adolfo Giaroli, Carlos Sananes et al. Long-Term Follow-up of the First Randomized Trial Using Neoadjuvant Chemotherapy in Stage Ib Squamous Carcinoma of the Cervix: The Final Results. *Gynecologic Oncology*, Volume 67, Issue 1, October 1997, Pages 61-69.
(Neoadjuvant C/T + RH 這篇文章覺得加上 NACT 是有比較好)
- 26. Gary L. Eddy, Brian N. Bundy, William T. Creasman et al. Treatment of ("bulky") stage IB cervical cancer with or without neoadjuvant vincristine and cisplatin prior to radical hysterectomy and pelvic/para-aortic lymphadenectomy: A phase III trial of the gynecologic oncology group. *Gynecologic Oncology*, Volume 106, Issue 2, August 2007, Pages 362-369
(Neoadjuvant C/T + RH vs RH 這篇文章覺得加上 NACT 沒有比較好)
- 27. Cosin JA, Fowler JM, Chen MD et al. Pretreatment surgical staging of patients with cervical carcinoma: the case for lymph node debulking. *Cancer*. 1998 Jun 1;82(11):2241-8
(先拿 LN 做 Surgical staging 對於 locally advanced Cx Ca 的預後 有 幫助的文章, n = 266)
- 28. Lai CH, Huang KG, Hong JH, et al. Randomized trial of surgical staging (extraperitoneal or laparoscopic) versus clinical staging in locally advanced cervical cancer. *Gynecol Oncol*. 2003 Apr;89(1):160-7.
(先拿 LN 做 Surgical staging 對於 locally advanced Cx Ca 的預後 沒有 幫助的文章, n = 61, RCT)
- 29. Peters WA 3rd, Liu PY, Barrett RJ 2nd, et al. Concurrent chemotherapy and pelvic radiation therapy compared with pelvic radiation therapy alone as adjuvant therapy after radical surgery in high-risk early-stage cancer of the cervix. *J Clin Oncol* 2000;18:1606-1613.
(RH 手術後加做 CCRT 的文章)

References

- 30.Sedlis A, Bundy BN, Rotman MZ et al. A randomized trial of pelvic radiation therapy versus no further therapy in selected patients with stage IB carcinoma of the cervix after radical hysterectomy and pelvic lymphadenectomy: A Gynecologic Oncology Group Study. *Gynecol Oncol.* 1999 May;73(2):177-83
(RH 手術後加做CCRT的文章)
- 31.Perry W, Grigsby. 4th International Cervical Cancer Conference: update on PET and cervical cancer. *Gynecologic Oncology*, Volume 99, Issue 3, Supplement 1, December 2005, Pages S173-S175
(PET對於子宮頸癌診斷的幫忙)
- 32.Rose PG, Adler LP, Rodriguez M et al. Positron emission tomography for evaluating para-aortic nodal metastasis in locally advanced cervical cancer before surgical staging: a surgicopathologic study. *J Clin Oncol.* 1999 Jan;17(1):41-5
(PET對於Para-aortic LN mets的術前診斷的幫忙)
- 33.Chou HH, Chang TC, Yen TC et al. Low value of [18F]-fluoro-2-deoxy-D-glucose positron emission tomography in primary staging of early-stage cervical cancer before radical hysterectomy. *J Clin Oncol.* 2006 Jan 1;24(1):123-8
(PET對於子宮頸癌術前診斷 沒有幫忙)
- 34.Boughanim M, Leboulleux S, Rey A et al. Histologic results of para-aortic lymphadenectomy in patients treated for stage IB2/II cervical cancer with negative [18F]fluorodeoxyglucose positron emission tomography scans in the para-aortic area. *J Clin Oncol.* 2008 May 20;26(15):2558-61
(PET對於Para-aortic LN mets的術前診斷到底有沒有幫忙)
- 35.Chao A, Ho KC, Wang CC et al. Positron emission tomography in evaluating the feasibility of curative intent in cervical cancer patients with limited distant lymph node metastases. *Gynecol Oncol.* 2008 May 20. [Epub ahead of print]
(PET對於LN mets的術前診斷以及預後 到底有沒有幫忙)
- 36.Mayr NA, Taoka T, Yuh WT et al. Method and timing of tumor volume measurement for outcome prediction in cervical cancer using magnetic resonance imaging. *Int J Radiat Oncol Biol Phys.* 2002 Jan 1;52(1):14-22.
(MRI對於子宮頸癌診斷的幫忙)
- 37.Ohara K, Tsunoda H, Satoh T et al. Use of the small pelvic field instead of the classic whole pelvic field in postoperative radiotherapy for cervical cancer: reduction of adverse events. *Int J Radiat Oncol Biol Phys.* 2004 Sep 1;60(1):258-64
(縮小放射線照射範圍，相較於全骨盆照射，是否可減低副作用)
- 38.Nobuhiro Takeshima, Kenji Umayahara, Kiyoshi Fujiwara et al. Treatment results of adjuvant chemotherapy after radical hysterectomy for intermediate- and high-risk stage IB–IIA cervical cancer. *Gynecologic Oncology*, Volume 103, Issue 2, November 2006, Pages 618-622
(術後化學治療對於子宮頸癌的高危險族群是否有幫助)

References

- **39.GOG 110** : Omura GA, Blessing JA, Vaccarella L, et al: Randomized trial of cisplatin versus cisplatin plus mitolactol versus cisplatin plus ifosfamide in advanced squamous carcinoma of the cervix: A Gynecologic Oncology Group study. *J Clin Oncol* 15:165-171, 1997
- **40.GOG 149** : Buxton E, Meanwell C, Hilton C, et al: Combination bleomycin, ifosfamide, and cisplatin chemotherapy in cervical cancer. *J Natl Cancer Inst* 81:359-361, 1989
- **41.GOG 169** : Moore DH, Blessing JA, McQuellon RP, et al: Phase III study of cisplatin with or without paclitaxel in Stage IVB, recurrent or persistent squamous cell carcinoma of the cervix: A Gynecologic Oncology Group study. *J Clin Oncol* 22:3113-3119, 2004
- **42.GOG 179** : Fiorica J, Holloway R, Ndubisi B, et al: Phase II trial of topotecan and cisplatin in persistent or recurrent squamous and nonsquamous carcinomas of the cervix. *Gynecol Oncol* 85:89-94, 2002
- 43.T Sugiyama, T Nishida, S Kumagai, et al. Combination therapy with irinotecan and cisplatin as neoadjuvant chemotherapy in locally advanced cervical cancer. *Br J Cancer*. 1999;81(1): 95–98.
- 44.Lee KB, Lee JM, Ki KD et al. Comparison of adjuvant chemotherapy and radiation in patients with intermediate risk factors after radical surgery in FIGO stage IB-IIA cervical cancer. *Int J Gynecol Cancer*. 2008 Sep-Oct;18(5):1027-31.
- 45.Rosa DD, Medeiros LR, Edelweiss MI, et al. Adjuvant platinum-based chemotherapy for early stage cervical cancer. *Cochrane Database Syst Rev*. 2009 Jul 8;(3):CD005342
- 46.Rydzewska L, Tierney J, Vale CL et al. Neoadjuvant chemotherapy plus surgery versus surgery for cervical cancer. *Cochrane Database Syst Rev*. 2010 Jan 20;(1):CD007406.
- 47.Matsumura M, Takeshima N, Ota T et al. Neoadjuvant chemotherapy followed by radical hysterectomy plus postoperative chemotherapy but no radiotherapy for Stage IB2-IIIB cervical cancer-Irinotecan and platinum chemotherapy. *Gynecol Oncol*. 2010 Aug 13. [Epub ahead of print]
- 48.Buda A, Dell'Anna T, Signorelli M, et al. Role of ifosfamide in cervical cancer: an overview, *Oncology*. 2003;65 Suppl 2:63-6.
- 49.Kumar JV, Doval DC, Rao R, Rawal S.et al. A retrospective study of patients with locally advanced cancer of the cervix treated with neoadjuvant chemotherapy followed by radical surgery. *Int J Gynecol Cancer*. 2009 Apr;19(3):417-22.

References

- 50. Alexander Sedlis, Brian N. Bundy, Marvin Z. Rotman, et al. A Randomized Trial of Pelvic Radiation Therapy versus No Further Therapy in Selected Patients with Stage IB Carcinoma of the Cervix after Radical Hysterectomy and Pelvic Lymphadenectomy: A Gynecologic Oncology Group Study. *Gynecologic Oncology* 73; 177–183, 1999
- 51. Bradley J. Monk, Michael W. Sill, D. Scott McMeekin, et al. Phase III Trial of Four Cisplatin-Containing Doublet Combinations in Stage IVB, Recurrent, or Persistent Cervical Carcinoma: A Gynecologic Oncology Group Study. *J Clin Oncol* 27:4649-4655, 2009
- 52. Haie-Meder C, Morice P, Castiglione M; **ESMO Guidelines Working Group. Cervical cancer: ESMO Clinical Practice Guidelines for diagnosis, treatment and follow-up.** *Ann Oncol.* 2010 May;21 Suppl 5:v37-40. No abstract available.
- 53. McCann GA, Boutsicaris CE, Preston MM, et al. Neuroendocrine carcinoma of the uterine cervix: the role of multimodality therapy in early-stage disease. *Gynecologic Oncology* 129(1):135-9, 2013
- 54. Cohen JG, Kapp DS, Shin JY, et al. Small cell carcinoma of the cervix: treatment and survival outcomes of 188 patients. *Am J Obstet Gynecol.* 203(4):347.e1-6, 2010
- 55. Tewari KS, Sill MW, Long HJ 3rd, et al. Improved survival with bevacizumab in advanced cervical cancer. *N Engl J Med.* 2014;370(8):734–743. •• Pivotal phase III trial that demonstrated an improvement in OS by adding bevacizumab to chemotherapy in patients with persistent, recurrent, and metastatic cervical cancer, with subsequent FDA approval for these patients.
- 56. Delgado G1, Bundy B, Zaino R, Sevin BU, Creasman WT, Major F. Prospective surgical-pathological study of disease-free interval in patients with stage IB squamous cell carcinoma of the cervix: a Gynecologic Oncology Group study. *Gynecol Oncol.* 1990 Sep;38(3):352-7.
- 57. Rotman M1, Sedlis A, Piedmonte MR, Bundy B, Lentz SS, Muderspach LI, Zaino RJ. A phase III randomized trial of postoperative pelvic irradiation in Stage IB cervical carcinoma with poor prognostic features: follow-up of a gynecologic oncology group study. *Int J Radiat Oncol Biol Phys.* 2006 May 1;65(1):169-76.

References

- 58. Vera Loizzi, Vittoria Del Vecchio, Francesco M. Crupano, Valentina Minicucci, Valeria V. Fumarulo, Leonardo Resta, Antonella Vimercati, Stefano Bettocchi, Ettore Cicinelli & Gennaro Cormio. A phase II study: dose-dense carboplatin and paclitaxel as neoadjuvant chemotherapy in locally advanced cervical cancer. *Journal of Chemotherapy* 2018 VOL. 30 NO. 4
- 59. Frenel JS, Le Tourneau C, O'Neil B, , Ott PA, Piha-Paul SA, Gomez-Roca C, van Brummelen EMJ, Rugo HS, Thomas S, Saraf S, Rangwala R, Varga A. Safety and Efficacy of Pembrolizumab in Advanced, Programmed Death Ligand 1-Positive Cervical Cancer: Results From the Phase Ib KEYNOTE-028 Trial. *J Clin Oncol.* 2017 Dec 20;35(36):4035-4041.
- 60. Hyun Cheol Chung, Jan H. M. Schellens, Jean-Pierre Delord, Ruth Perets, Antoine Italiano, Ronnie Shapira-Frommer, et al. Pembrolizumab treatment of advanced cervical cancer: Updated results from the phase 2 KEYNOTE-158 study. *J Clin Oncol.* 2018 36
- 61. Chia-Jung Hsieh, Mun-Kun Hong, Pau-Chung Chen, Jen-Hung Wang and Tang-Yuan Chu. Antiestrogen use reduces risk of cervical neoplasia in breast cancer patients: a population-based study. *Oncotarget*, 2017, VOL. 8, (No. 17), pp:29361-29369.
- 62. Gabriella Ferrandina, Franco O. Ranelletti, Luigi M. Larocca, Nicola Maggiano, Erika Fruscella, Francesco Legge, Giuseppe Santeusano, Alessandro Bombonati, Salvatore Mancuso, and Giovanni Scambia. Tamoxifen Modulates the Expression of Ki67, Apoptosis, and Microvessel Density in Cervical Cancer. *Clinical Cancer Research*. Vol. 7, 2656-2661, September 2001.
- 63. Frumovitz M, Munsell MF, Burzawa JK, Byers LA, Ramalingam P, Brown J, Coleman RL. Combination therapy with topotecan, paclitaxel, and bevacizumab improves progression-free survival in recurrent small cell neuroendocrine carcinoma of the cervix. *Gynecol Oncol.* 2017 Jan;144(1):46-50.