

# 高雄榮民總醫院 惡性卵巢生殖細胞癌 診療指引

2020年03月17日 第一版

婦癌醫療團隊擬訂

注意事項：這個診療原則主要作為醫師和其他保健專家診療癌症病人參考之用。假如你是一個癌症病人，直接引用這個診療原則並不恰當，只有你的醫師才能決定給你最恰當的治療。

# 會議討論

上次會議：2019/02/26

## 本共識與上一版的差異

上一版	新版
1. 無。	1. 審視最新版NCCN guideline與本院現制定之診療指引無差異，故此版無須修改。

AJCC 8<sup>th</sup>

<b>Primary Tumor (T)</b>		
<b>T</b>	<b>FIGO</b>	<b>T Criteria</b>
TX		Primary tumor cannot be assessed
T0		No evidence of primary tumor
T1	I	Tumor limited to ovaries (one or both) or fallopian tube(s)
T1a	IA	Tumor limited to one ovary (capsule intact) or fallopian tube, no tumor on ovarian or fallopian tube surface; no malignant cells in ascites or peritoneal washings
T1b	IB	Tumor limited to both ovaries (capsules intact) or fallopian tubes; no tumor on ovarian or fallopian tube surface; no malignant cells in ascites or peritoneal washings
T1c	IC	Tumor limited to one or both ovaries or fallopian tubes, with any of the following:
T1c1	IC1	Surgical spill
T1c2	IC2	Capsule ruptured before surgery or tumor on ovarian or fallopian tube surface
T1c3	IC3	Malignant cells in ascites or peritoneal washings

T2	II	Tumor involves one or both ovaries or fallopian tubes with pelvic extension below pelvic brim or primary peritoneal cancer
T2a	IIA	Extension and/or implants on the uterus and/or fallopian tube(s) and/or ovaries
T2b	IIB	Extension to and/or implants on other pelvic tissues
T3	III	Tumor involves one or both ovaries or fallopian tubes, or primary peritoneal cancer, with microscopically confirmed peritoneal metastasis outside the pelvis and/or metastasis to the retroperitoneal (pelvic and/or para-aortic) lymph nodes
T3a	IIIA2	Microscopic extrapelvic (above the pelvic brim) Peritoneal involvement with or without positive retroperitoneal lymph nodes
T3b	IIIB	Macroscopic peritoneal metastasis beyond pelvis 2 cm or less in greatest dimension with or without metastasis to the retroperitoneal lymph nodes
T3c	IIIC	Macroscopic peritoneal metastasis beyond the pelvis more than 2 cm in greatest dimension with or without metastasis to the retroperitoneal lymph nodes (includes extension of tumor to capsule of liver and spleen without parenchymal involvement of either organ)

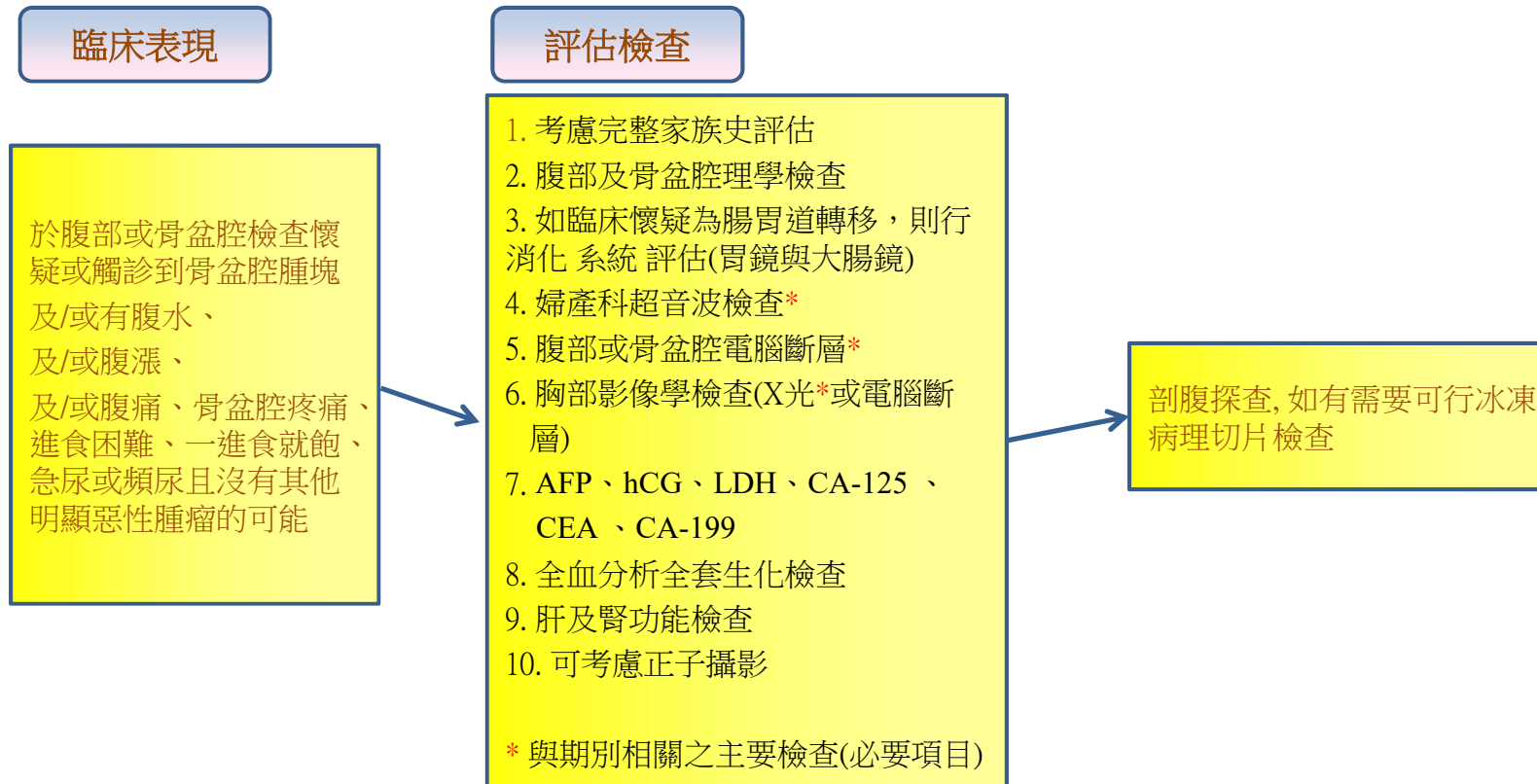
<b>Regional Lymph Node (N)</b>		
<b>N</b>	<b>FIGO</b>	<b>N Criteria</b>
NX		Regional lymph nodes cannot be assessed
N0		No regional lymph node metastasis
N0 (i+)		Isolated tumor cells in regional lymph node(s) no greater than 0.2 mm
N1	IIIA1	Positive retroperitoneal lymph nodes only (histologically confirmed)
N1a	IIIA1i	Metastasis up to and including 10 mm in greatest dimension
N1b	IIIA1ii	Metastasis more than 10 mm in greatest dimension

<b>Distant Metastasis (M)</b>		
<b>M</b>	<b>FIGO</b>	<b>M Criteria</b>
M0		No distant metastasis
M1	IV	Distant metastasis, including pleural effusion with positive cytology ; liver or splenic parenchymal metastasis; metastasis to extra-abdominal organs (including inguinal lymph nodes and lymph nodes outside the abdominal cavity); and transmural involvement of intestine
M1a	IVA	Pleural effusion with positive cytology
M1b	IVB	Liver or splenic parenchymal metastases; metastases to extra-abdominal organs (including inguinal lymph nodes and lymph nodes outside the abdominal cavity); transmural involvement of intestine

<b>STAGE GROUPS</b>			
<b>T</b>	<b>N</b>	<b>M</b>	<b>stage</b>
T1	N0	M0	I
T1a	N0	M0	IA
T1b	N0	M0	IB
T1c	N0	M0	IC
T2	N0	M0	II
T2a	N0	M0	IIA
T2b	N0	M0	IIB
T1/T2	N1	M0	IIIA1
T3a	N0/N1/Nx	M0	IIIA2
T3b	N0/N1/Nx	M0	IIIB
T3c	N0/N1/Nx	M0	IIIC
Any T	Any N	M1	IV
Any T	Any N	M1a	IVA
Any T	Any N	M1b	IVB

治療前的評估:

疑似有卵巢惡性腫瘤的35歲以下年輕女性患者，在開始治療之前，建議檢查CA-125, AFP、hCG、LDH、CEA、CA-199



流程圖一



患者的染色體若含有46,XY

- ◆雙側的性腺應及早切除者：  
若為45,X/46,XY鑲嵌型或是46,XY，而且腹腔內的性腺呈發育不良(dysgenesis)者
- ◆考慮等到青春期之後再摘除性腺者：  
若為46,XY，罹患雄性素反應不良症候群，而腹腔內性腺(即睪丸)的組織型態正常者

流程圖二

## 分期手術

手術中經由冷凍切片診斷為生殖細胞癌之後，若患者仍想要懷孕，則可保留子宮與對側卵巢。若要進行完整的分期手術，注意事項包括：

- ◆術前的腸道準備應同腸道手術之準備
- ◆宜用中央垂直開腹切口，以獲取充份的手術視野
- ◆進入腹腔，即抽取腹水或經由腹腔灌洗取得腹膜腔細胞學檢查的標本
- ◆盡可能完整的取出腫瘤，檢體需盡快送病理檢驗，並常規性送冷凍切片
- ◆若患者不想保留生育能力，則行全子宮及兩側卵巢輸卵管切除手術；若想要懷孕的患者，在經由冷凍切片證實為惡性生殖細胞腫瘤者，可保留子宮與對側卵巢
- ◆應詳細檢查對側，必要時施行對側卵巢的切片檢查
- ◆考慮盡量切除主要腫瘤側的輸卵管漏斗部骨盆韌帶
- ◆粘黏處需切片送檢
- ◆評估所有的腸道表面，且所有的可疑處都要切片送檢
- ◆若無明顯卵巢外擴散病灶，則需隨機腹膜取樣，如子宮直腸陷窩、骨盆腔側壁、膀胱漿膜、兩側大腸側窩、橫隔膜下表面等
- ◆橫結腸下網膜切除手術
- ◆淋巴結評估應包括骨盆淋巴結及主動脈旁淋巴結，主動脈旁淋巴結希望取到inferior mesenteric artery的高度，如有可能最好能取到renal vessel的高度
- ◆考慮切除之前腹腔鏡手術的埠管路徑
- ◆完整手術記錄殘餘腫瘤的大小與位置

首次減積手術

- ◆由於化學治療對於卵巢惡性生殖細胞腫瘤非常有效，因而即使腫瘤病灶已廣泛地散佈，仍可行生育保留手術，保留其正常的子宮與正常的對側卵巢。
- ◆手術的範圍應該要兼顧盡量清除病變與不造成手術併發症，不可因手術併發症而延誤手術後化學治療的進行。

流程圖四

### 關於較保守的手術

- ◆由於患者大部份為年輕女性，而生殖細胞腫瘤多為單側性，且化學治療非常有效，因而即使腫瘤病灶已廣泛地散佈，大部份的患者仍可行生育保留手術，保留其正常的子宮與正常的對側卵巢（但若患者不考慮保留生育能力，則全部切除）。
- ◆對於雙側卵巢都有病灶，但仍極力想保留生育能力的患者，臨床醫師與病患及家屬溝通討論保留單側卵巢的利弊得失，或許可以考慮保留一側之卵巢與輸卵管，再於手術之後進行化學治療。
- ◆對側卵巢若外觀正常，則除了 dysgerminoma 或含有 dysgerminoma 成份的mixed germ cell tumor 以外，不宜做不必要的切片，以免造成卵巢提早衰竭或黏粘，損及日後的生育能力。

流程圖五

關於分期手術不完全的患者

- ◆可能可以不必化學治療者（即臨床上看來像是 stage IA grade 1 immature teratoma 或 stage I dysgerminoma者）：
  - 若影像學檢查無特別發現，則 考慮追蹤
  - 若影像學檢查無特別發現，但腫瘤指數有異常者，仍考慮追蹤或進一步徹底的分期手術確認。
  - 若影像學檢查有特別發現，則需進一步徹底的分期手術確認。
  
- ◆已知需化學治療者：
  - 通常不需要單獨為了進一步分期而再次手術

流程圖六

手術之後不用化學治療的狀況

---

- ◆充分的分期（comprehensive staging）手術之後的 Stage IA grade 1 immature teratoma
- ◆充分的分期手術之後的 Stage I dysgerminoma

流程圖七

第一線化學治療

- ◆ 首選配方：BEP (bleomycin、etoposide、cisplatin) 每21天1次，共3-4次 (11,17,21)
  - 較適合台灣人的配方：Cisplatin 50 mg/m<sup>2</sup>, IV, day 1  
Etoposide 100 mg/m<sup>2</sup>, IV, on days 1-3  
Bleomycin 15 mg/m<sup>2</sup>, IV, on days 1-3 (每天總量不超過25mg)
  - ◆ 施行BEP配方前，考慮安排肺功能檢查。  
若不適合用Bleomycin的病人，可考慮使用etoposide + cisplatin (45)
- ◆ 重要副作用
  - Pulmonary fibrosis  
危險因子：Bleomycin 終身累積劑量450mg以上  
Bleomycin 單次劑量超過15mg/m<sup>2</sup>  
年紀超過70歲  
肺氣腫  
肺部曾經接受放射線治療
  - Acute myelogenous leukemia(AML)  
危險因子：Etoposide 累積劑量2000 mg/m<sup>2</sup>以上
  - 卵巢傷害  
可能有益之預防措施：在化學治療開始之前與進行期間，  
考慮使用gonadotropin-releasing hormone agonists或口服避孕藥

流程圖八

放射治療

僅限於：

- ◆身體狀況不適合化學治療的dysgerminoma 患者，或
- ◆經過多種化學治療後，仍有腫瘤相關之局部症狀者
- ◆各種原因無法化學治療者，可考慮放射治療

流程圖九



完成治療之後的追蹤

- ◆ 追蹤頻率：
  - 前兩年建議每2-4個月追蹤一次
  - 三到五年每3-6個月追蹤一次
  - 其後每6-12個月追蹤一次
  
- ◆ 追蹤項目：
  - 詢問病史、理學檢查
  - 超音波、Chest X-ray(每年一次)
  - 血中腫瘤標記檢查(若治療前的某項血中腫瘤標記有上升者)
  - 可依臨床判斷而安排影像檢查(如CT、MRI、PET scan等)，尤其是對治療前血中腫瘤標記正常而無法用血中腫瘤標記來追蹤的患者

流程圖十

第一線化學治療失敗時(轉移)

惡性生殖細胞腫瘤的「鉑敏感性」( platinum-sensitive) :

- ◆定義為在含鉑類藥物的化學治療結束後 6 個月之上才發生復發
- ◆考慮使用先前之化學治療處方(注意Bleomycin 總累積劑量)

惡性生殖細胞腫瘤的「鉑抗藥性」( platinum-resistant) :

- ◆定義為在含鉑類藥物的化學治療當中或化學治療結束後 6 個月之內即發生復發

- VIP (Vinoblastine 0.11 mg/kg/day x 2d 、 ifosfamid 4gm/m<sup>2</sup> 、 cisplatin 50mg/m<sup>2</sup> x 6 cycles)
- TIP (paclitacel 175mg/m<sup>2</sup> 、 ifosfamide4gm/m<sup>2</sup> 、 cisplatin 50mg/m<sup>2</sup> x6 cycles)
- 高劑量化學治療
- ◆Paclitaxel + carboplatin
- ◆ Paclitaxel+ ifosfamide
- ◆ Paclitaxel+ gemcitabine

流程圖十一

姑息緩解性治療

---

- ◆ 支持性照護，或
- ◆ 姑息緩解性之放射治療，或
- ◆ 緩解性的化學治療

流程圖十二

# Reference

- 1. Badawy, A., A. Elnashar, et al. (2009). "Gonadotropin-releasing hormone agonists for prevention of chemotherapy-induced ovarian damage: prospective randomized study." *Fertil Steril* 91(3): 694-697.
- 2. Bjorkholm, E., M. Lundell, et al. (1990). "Dysgerminoma. The Radiumhemmet series 1927-1984." *Cancer* 65(1): 38-44.
- 3. Blum, R. H., S. K. Carter, et al. (1973). "A clinical review of bleomycin--a new antineoplastic agent." *Cancer* 31(4): 903-914.
- 4. Blumenfeld, Z. and M. von Wolff (2008). "GnRH-analogues and oral contraceptives for fertility preservation in women during chemotherapy." *Hum Reprod Update* 14(6): 543-552.
- 5. Boice, J. D., Jr., G. Engholm, et al. (1988). "Radiation dose and second cancer risk in patients treated for cancer of the cervix." *Radiat Res* 116(1): 3-55.
- 6. Bonazzi, C., F. Peccatori, et al. (1994). "Pure ovarian immature teratoma, a unique and curable disease: 10 years' experience of 32 prospectively treated patients." *Obstet Gynecol* 84(4): 598-604.
- 7. Comerci, J. T., Jr., F. Licciardi, et al. (1994). "Mature cystic teratoma: a clinicopathologic evaluation of 517 cases and review of the literature." *Obstet Gynecol* 84(1): 22-28.
- 8. Cushing, B., R. Giller, et al. (1999). "Surgical resection alone is effective treatment for ovarian immature teratoma in children and adolescents: a report of the pediatric oncology group and the children's cancer group." *Am J Obstet Gynecol* 181(2): 353-358.
- 9. Dark, G. G., M. Bower, et al. (1997). "Surveillance policy for stage I ovarian germ cell tumors." *J Clin Oncol* 15(2): 620-624.
- 10. de Wit, R., G. Stoter, et al. (1997). "Importance of bleomycin in combination chemotherapy for good-prognosis testicular nonseminoma: a randomized study of the European Organization for Research and Treatment of Cancer Genitourinary Tract Cancer Cooperative Group." *J Clin Oncol* 15(5): 1837-1843.
- 11. Dimopoulos, M. A., C. Papadimitriou, et al. (2004). "Treatment of ovarian germ cell tumors with a 3-day bleomycin, etoposide, and cisplatin regimen: a prospective multicenter study." *Gynecol Oncol* 95(3): 695-700.
- 12. Dos Santos, L., E. Mok, et al. (2007). "Squamous cell carcinoma arising in mature cystic teratoma of the ovary: a case series and review of the literature." *Gynecol Oncol* 105(2): 321-324.

# Reference

- 13. Fallat, M. E. and P. K. Donahoe (2006). "Intersex genetic anomalies with malignant potential." *Curr Opin Pediatr* 18(3): 305-311.
- 14. Geisler, J. P., R. Goulet, et al. (1994). "Growing teratoma syndrome after chemotherapy for germ cell tumors of the ovary." *Obstet Gynecol* 84(4 Pt 2): 719-721.
- 15. Gershenson, D. M. (1988). "Menstrual and reproductive function after treatment with combination chemotherapy for malignant ovarian germ cell tumors." *J Clin Oncol* 6(2): 270-275.
- 16. Gershenson, D. M. (1993). "Update on malignant ovarian germ cell tumors." *Cancer* 71(4 Suppl): 1581-1590.
- 17. Gershenson, D. M., M. Morris, et al. (1990). "Treatment of malignant germ cell tumors of the ovary with bleomycin, etoposide, and cisplatin." *J Clin Oncol* 8(4): 715-720.
- 18. Goldiner, P. L., G. C. Carlon, et al. (1978). "Factors influencing postoperative morbidity and mortality in patients treated with bleomycin." *Br Med J* 1(6128): 1664-1667.
- 19. Gordon, A., D. Lipton, et al. (1981). "Dysgerminoma: a review of 158 cases from the Emil Novak Ovarian Tumor Registry." *Obstet Gynecol* 58(4): 497-504.
- 20. Hart, W. R. and D. M. Burkons (1979). "Germ cell neoplasms arising in gonadoblastomas." *Cancer* 43(2): 669-678.
- 21. Horwich, A., D. T. Sleijfer, et al. (1997). "Randomized trial of bleomycin, etoposide, and cisplatin compared with bleomycin, etoposide, and carboplatin in good-prognosis metastatic nonseminomatous germ cell cancer: a Multiinstitutional Medical Research Council/European Organization for Research and Treatment of Cancer Trial." *J Clin Oncol* 15(5): 1844-1852.
- 22. Howell, S. and S. Shalet (1998). "Gonadal damage from chemotherapy and radiotherapy." *Endocrinol Metab Clin North Am* 27(4): 927-943.
- 23. Kanazawa, K., T. Suzuki, et al. (2000). "Treatment of malignant ovarian germ cell tumors with preservation of fertility: reproductive performance after persistent remission." *Am J Clin Oncol* 23(3): 244-248.
- 24. Kondagunta, G. V., J. Bacik, et al. (2005). "Combination of paclitaxel, ifosfamide, and cisplatin is an effective second-line therapy for patients with relapsed testicular germ cell tumors." *J Clin Oncol* 23(27): 6549-6555.
- 25. Loehrer, P. J., Sr., D. Johnson, et al. (1995). "Importance of bleomycin in favorable-prognosis disseminated germ cell tumors: an Eastern Cooperative Oncology Group trial." *J Clin Oncol* 13(2): 470-476.

# Reference

- 26. Loehrer, P. J., Sr., R. Lauer, et al. (1988). "Salvage therapy in recurrent germ cell cancer: ifosfamide and cisplatin plus either vinblastine or etoposide." *Ann Intern Med* 109(7): 540-546.
- 27. Mann, J. R., F. Raafat, et al. (2000). "The United Kingdom Children's Cancer Study Group's second germ cell tumor study: carboplatin, etoposide, and bleomycin are effective treatment for children with malignant extracranial germ cell tumors, with acceptable toxicity." *J Clin Oncol* 18(22): 3809-3818.
- 28. Marina, N. M., B. Cushing, et al. (1999). "Complete surgical excision is effective treatment for children with immature teratomas with or without malignant elements: A Pediatric Oncology Group/Children's Cancer Group Intergroup Study." *J Clin Oncol* 17(7): 2137-2143.
- 29. McKeage, M. J., B. D. Evans, et al. (1990). "Carbon monoxide diffusing capacity is a poor predictor of clinically significant bleomycin lung. New Zealand Clinical Oncology Group." *J Clin Oncol* 8(5): 779-783.
- 30. Messing, M. J., D. M. Gershenson, et al. (1992). "Primary treatment failure in patients with malignant ovarian germ cell neoplasms." *Int J Gynecol Cancer* 2(6): 295-300.
- 31. Motzer, R. J., N. L. Geller, et al. (1991). "Salvage chemotherapy for patients with germ cell tumors. The Memorial Sloan-Kettering Cancer Center experience (1979-1989)." *Cancer* 67(5): 1305-1310.
- 32. Nichols, C. R., E. S. Breeden, et al. (1993). "Secondary leukemia associated with a conventional dose of etoposide: review of serial germ cell tumor protocols." *J Natl Cancer Inst* 85(1): 36-40.
- 33. Norris, H. J., H. J. Zirkin, et al. (1976). "Immature (malignant) teratoma of the ovary: a clinical and pathologic study of 58 cases." *Cancer* 37(5): 2359-2372.
- 34. O'Connor, D. M. and H. J. Norris (1994). "The influence of grade on the outcome of stage I ovarian immature (malignant) teratomas and the reproducibility of grading." *Int J Gynecol Pathol* 13(4): 283-289.
- 35. Peccatori, F., C. Bonazzi, et al. (1995). "Surgical management of malignant ovarian germ-cell tumors: 10 years' experience of 129 patients." *Obstet Gynecol* 86(3): 367-372.
- 36. Pfannenber, C., P. Aschoff, et al. (2010). "PET/CT with 18F-FLT: does it improve the therapeutic management of metastatic germ cell tumors?" *J Nucl Med* 51(6): 845-853.
- 37. Pui, C. H. (1991). "Epipodophyllotoxin-related acute myeloid leukaemia." *Lancet* 338(8780): 1468.

# Reference

- 38. Rim, S. Y., S. M. Kim, et al. (2006). "Malignant transformation of ovarian mature cystic teratoma." *Int J Gynecol Cancer* 16(1): 140-144.
- 39. Rogers, P. C., T. A. Olson, et al. (2004). "Treatment of children and adolescents with stage II testicular and stages I and II ovarian malignant germ cell tumors: A Pediatric Intergroup Study--Pediatric Oncology Group 9048 and Children's Cancer Group 8891." *J Clin Oncol* 22(17): 3563-3569.
- 40. Slayton, R. E., M. M. Hreshchyshyn, et al. (1978). "Treatment of malignant ovarian germ cell tumors: response to vincristine, dactinomycin, and cyclophosphamide (preliminary report)." *Cancer* 42(2): 390-398.
- 41. Tangjitgamol, S., S. Manusirivithaya, et al. (2003). "Squamous cell carcinoma arising from dermoid cyst: Case reports and review of literature." *Int J Gynecol Cancer* 13(4): 558-563.
- 42. Williams, S., J. A. Blessing, et al. (1994). "Adjuvant therapy of ovarian germ cell tumors with cisplatin, etoposide, and bleomycin: a trial of the Gynecologic Oncology Group." *J Clin Oncol* 12(4): 701-706.
- 43. Williams, S. D., J. A. Blessing, et al. (1994). "Second-look laparotomy in ovarian germ cell tumors: the gynecologic oncology group experience." *Gynecol Oncol* 52(3): 287-291.
- 44. Williams, S. D., J. A. Blessing, et al. (1989). "Cisplatin, vinblastine, and bleomycin in advanced and recurrent ovarian germ-cell tumors. A trial of the Gynecologic Oncology Group." *Ann Intern Med* 111(1): 22-27.
- 45. Williams, S. D., J. Kauderer, et al. (2004). "Adjuvant therapy of completely resected dysgerminoma with carboplatin and etoposide: a trial of the Gynecologic Oncology Group." *Gynecol Oncol* 95(3): 496-499.
- 46. Zanetta, G., C. Bonazzi, et al. (2001). "Survival and reproductive function after treatment of malignant germ cell ovarian tumors." *J Clin Oncol* 19(4): 1015-1020.