

高雄榮民總醫院

卵巢惡性生殖細胞癌

診療指引

2022年 第一版 2022/5/10

婦癌醫療團隊擬訂

注意事項

這個診療原則主要作為醫師和其他保健專家診療癌症病人參考之用。假如你是一個癌症病人，直接引用這個診療原則並不恰當，只有你的醫師才能決定給你最恰當的治療。

修訂指引

- 本共識依下列參考資料修改版本
 - NCCN Clinical Practical Guidelines in Oncology™ Ovarian Cancer, including Fallopian Tube Cancer and Primary Peritoneal Cancer (V.1 2022)
 - 婦癌臨床診療指引：國家衛生研究院 (2011)
 - 婦癌研究委員會

會議討論

上次會議：2021/03/23

本共識與上一版的差異

上一版	新版
1. 無。	1. 審視最新版NCCN guideline與本院現制定之診療指引無差異，故此版無須修改。

2014 FIGO Stage of Ovarian Cancer

卵巢癌之分期：上皮性卵巢癌，採取手術分期(surgical staging)，根據手術時的觀察及手術標本的組織病理檢查，來做分期的依據。病理報告需含有組織學類型、分化程度、卵巢以外的轉移與否及其轉移部位、淋巴結是否有轉移、卵巢有否向外生長的贅生物(exophytic vegetation)、以及腹水或腹膜腔灌洗(peritoneal lavage)之細胞學檢查結果。

第 I 期：癌症只限在卵巢(Tumor confined to ovaries)

第 IA 期：癌症局限在一側的卵巢；卵巢的表面完整，且表面處沒有癌病變，腹水中或腹腔沖洗液中無癌細胞 (Tumor limited to one ovary; capsule intact, no tumor on ovarian surface. No malignant cells in ascites or peritoneal washings)。

第 IB 期：癌症局限在兩側的卵巢；卵巢的表面完整，且表面處沒有癌病變，腹水中或腹腔沖洗液中無癌細胞(Tumor limited to both ovaries; capsules intact, no tumor on ovarian surface. No malignant cells in ascites or peritoneal washings)。

第IC1期：癌症局限在一或兩側的卵巢，但手術中破裂 (Surgical spill)。

第IC2期：癌症局限在一或兩側的卵巢，但腫瘤術前已破裂或卵巢表面有腫瘤 (Capsule rupture before surgery or tumor on ovarian surface)。

第IC3期：癌症局限在一或兩側的卵巢，但腹水中或腹腔沖洗液中有癌細胞 (Malignant cells in the ascites or peritoneal washings)。

第 II 期：單側或兩側卵巢癌，並且有骨盆腔擴散(Tumor involves 1 or both ovaries with pelvic extension (below the pelvic brim) or primary peritoneal cancer)

第 IIA 期：擴散只限於子宮或輸卵管 (Extension and/or implants on uterus and/or Fallopian tubes)。

第 IIB 期：擴散至骨盆腔內的其他組織 (Extension to other pelvic intraperitoneal tissues)。

第 III 期：單側或兩側卵巢癌，有骨盆腔以外的腹膜轉移，或轉移到後腹腔的淋巴結 (Tumor involves 1 or both ovaries with cytologically or histologically confirmed spread to the peritoneum outside the pelvis and/or metastasis to the retroperitoneal lymph nodes)

第 IIIA 期：後腹腔淋巴結轉移和/或組織學的檢查證實有腹腔的轉移(Positive retroperitoneal lymph nodes and/or microscopic metastasis beyond the pelvis)

第 IIIA1期：只有後腹腔淋巴結轉移 (Positive retroperitoneal lymph nodes only)：

第 IIIA1(i) 期：轉移小於或等於10 mm (Metastasis \leq 10 mm)。

第 IIIA1(ii)期：轉移大於10 mm (Metastasis $>$ 10 mm)。

第 IIIA2期：組織學的檢查證實有腹腔的轉移和/或後腹腔淋巴結轉移(Microscopic, extrapelvic (above the brim) peritoneal involvement \pm positive retroperitoneal lymph nodes)。

第 IIIB 期：組織學檢查證實腹腔腹膜表面已經有了癌病變，但病變的最大徑並無超過兩公分者，和/或後腹腔淋巴結轉移(Macroscopic, extrapelvic, peritoneal metastasis \leq 2 cm \pm positive retroperitoneal lymph nodes)。

第 IIIC 期：腹腔轉移病灶的最大徑已超過兩公分，和/或後腹腔淋巴結轉移，包含肝臟或脾臟外膜侵襲(Macroscopic, extrapelvic, peritoneal metastasis $>$ 2 cm \pm positive retroperitoneal lymph nodes. Includes extension to capsule or liver/spleen)。

第 IV 期：遠端轉移超出腹膜(Distant metastasis excluding peritoneal metastasis)

第 IVA 期：肋膜積水有癌細胞 (Pleural effusion with positive cytology)。

第 IVB 期：肝臟或脾臟實質侵犯，轉移至腹外器官(包含腹股溝淋巴結與腹腔外淋巴結 (Hepatic and/or splenic parenchymal metastasis, metastasis to extra-abdominal organs (including inguinal lymph nodes and lymph nodes outside of the abdominal cavity)。

AJCC 8th Ed TNM Stage of Ovarian Cancer

Primary Tumor (T)		
T	FIGO	T Criteria
TX		Primary tumor cannot be assessed
T0		No evidence of primary tumor
T1	I	Tumor limited to ovaries (one or both) or fallopian tube(s)
T1a	IA	Tumor limited to one ovary (capsule intact) or fallopian tube, no tumor on ovarian or fallopian tube surface; no malignant cells in ascites or peritoneal washings
T1b	IB	Tumor limited to both ovaries (capsules intact) or fallopian tubes; no tumor on ovarian or fallopian tube surface; no malignant cells in ascites or peritoneal washings
T1c	IC	Tumor limited to one or both ovaries or fallopian tubes, with any of the following:
T1c1	IC1	Surgical spill
T1c2	IC2	Capsule ruptured before surgery or tumor on ovarian or fallopian tube surface
T1c3	IC3	Malignant cells in ascites or peritoneal washings

T2	II	Tumor involves one or both ovaries or fallopian tubes with pelvic extension below pelvic brim or primary peritoneal cancer
T2a	IIA	Extension and/or implants on the uterus and/or fallopian tube(s) and/or ovaries
T2b	IIB	Extension to and/or implants on other pelvic tissues
T3	III	Tumor involves one or both ovaries or fallopian tubes, or primary peritoneal cancer, with microscopically confirmed peritoneal metastasis outside the pelvis and/or metastasis to the retroperitoneal (pelvic and/or para-aortic) lymph nodes
T3a	IIIA2	Microscopic extrapelvic (above the pelvic brim) Peritoneal involvement with or without positive retroperitoneal lymph nodes
T3b	IIIB	Macroscopic peritoneal metastasis beyond pelvis 2 cm or less in greatest dimension with or without metastasis to the retroperitoneal lymph nodes
T3c	IIIC	Macroscopic peritoneal metastasis beyond the pelvis more than 2 cm in greatest dimension with or without metastasis to the retroperitoneal lymph nodes (includes extension of tumor to capsule of liver and spleen without parenchymal involvement of either organ)

Regional Lymph Node (N)		
N	FIGO	N Criteria
NX		Regional lymph nodes cannot be assessed
N0		No regional lymph node metastasis
N0 (i+)		Isolated tumor cells in regional lymph node(s) no greater than 0.2 mm
N1	IIIA1	Positive retroperitoneal lymph nodes only (histologically confirmed)
N1a	IIIAli	Metastasis up to and including 10 mm in greatest dimension
N1b	IIIAlii	Metastasis more than 10 mm in greatest dimension

Distant Metastasis (M)		
M	FIGO	M Criteria
M0		No distant metastasis
M1	IV	Distant metastasis, including pleural effusion with positive cytology; liver or splenic parenchymal metastasis; metastasis to extra-abdominal organs (including inguinal lymph nodes and lymph nodes outside the abdominal cavity); and transmural involvement of Intestine
M1a	IVA	Pleural effusion with positive cytology
M1b	IVB	Liver or splenic parenchymal metastases; metastases to extra-abdominal organs (including inguinal lymph nodes and lymph nodes outside the abdominal cavity); transmural involvement of Intestine

STAGE GROUPS			
T	N	M	Stage
T1	N0	M0	I
T1a	N0	M0	IA
T1b	N0	M0	IB
T1c	N0	M0	IC
T2	N0	M0	II
T2a	N0	M0	IIA
T2b	N0	M0	IIB
T1/T2	N1	M0	IIIA1
T3a	N0/N1/Nx	M0	IIIA2
T3b	N0/N1/Nx	M0	IIIB
T3c	N0/N1/Nx	M0	IIIC
Any T	Any N	M1	IV
Any T	Any N	M1a	IVA
Any T	Any N	M1b	IVB

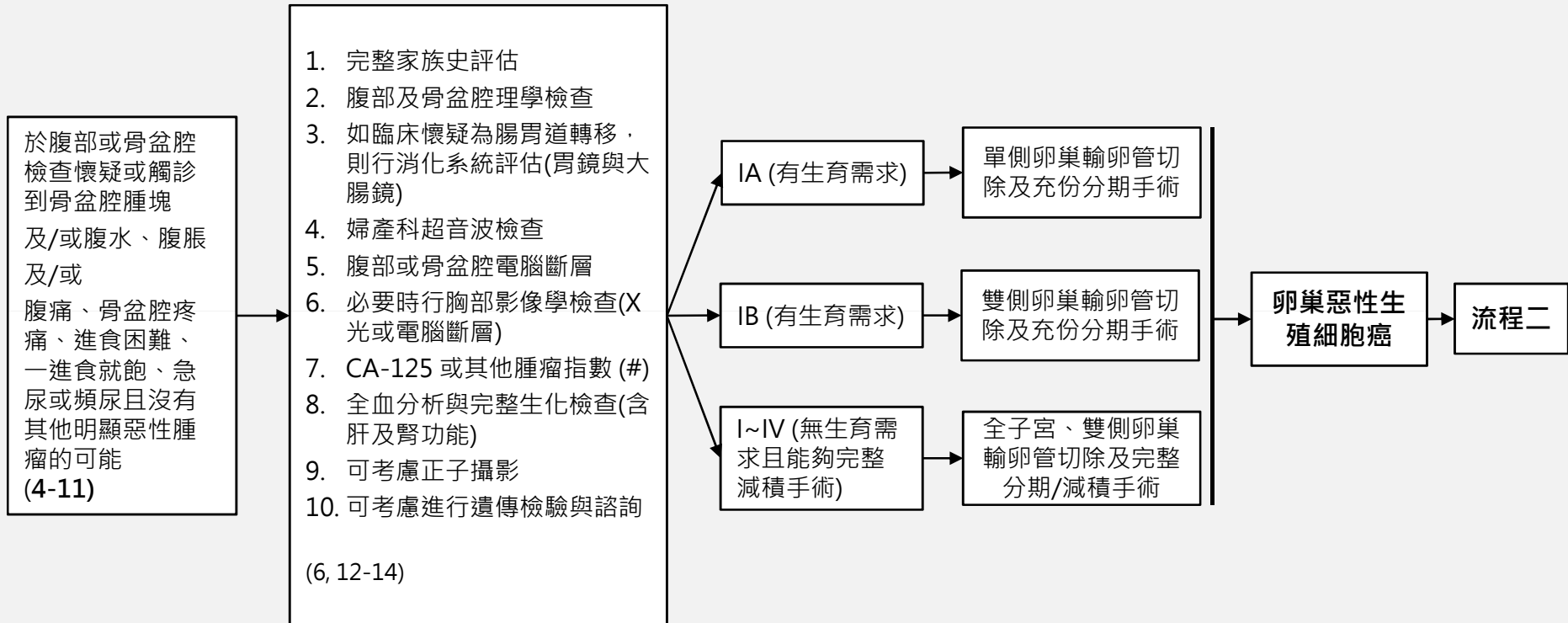
高雄榮總婦癌團隊 卵巢惡性生殖細胞癌 臨床治療指引

臨床表現

評估檢查

臨床期別

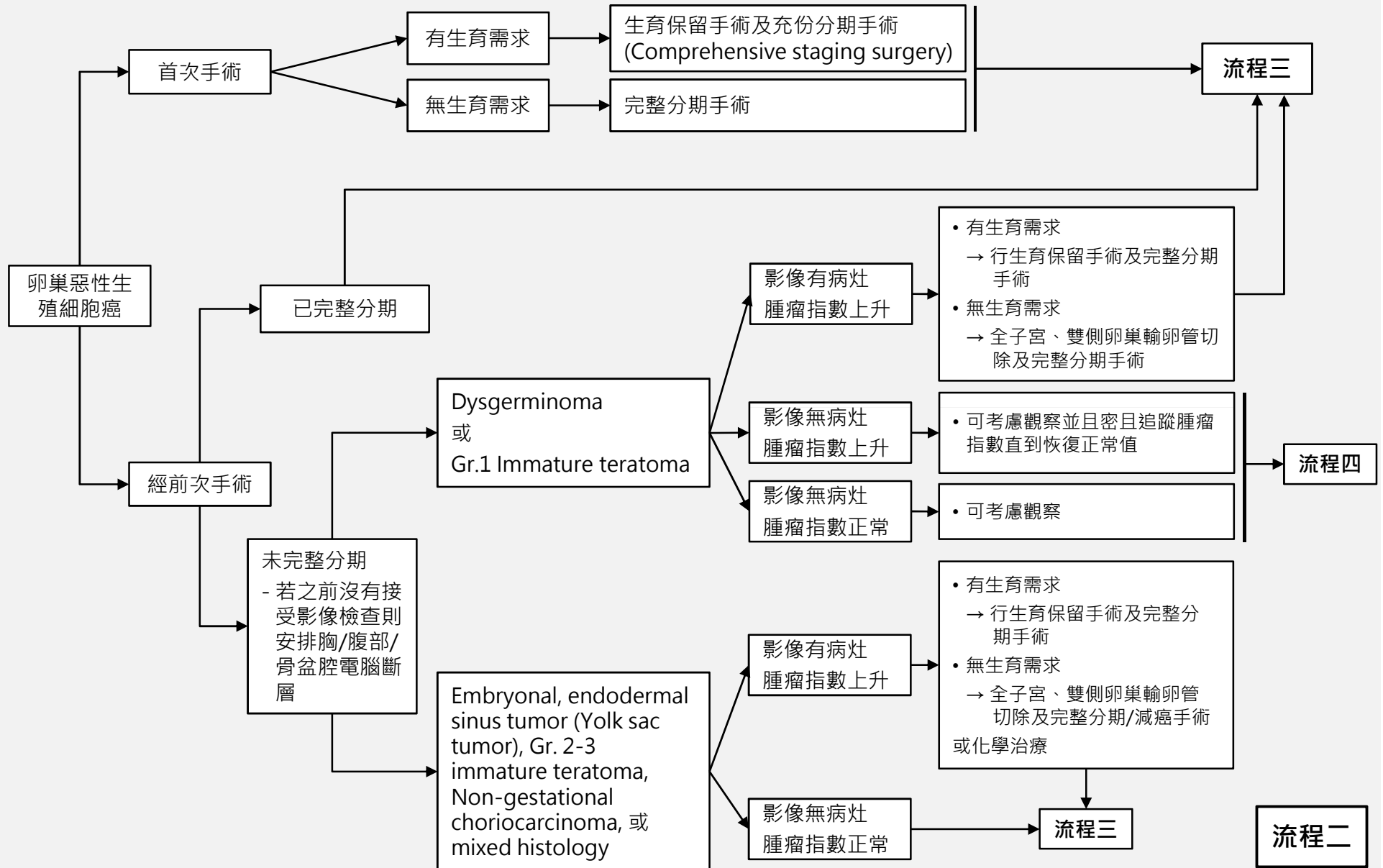
初步治療 (建議由婦癌醫師執行) (18-20)



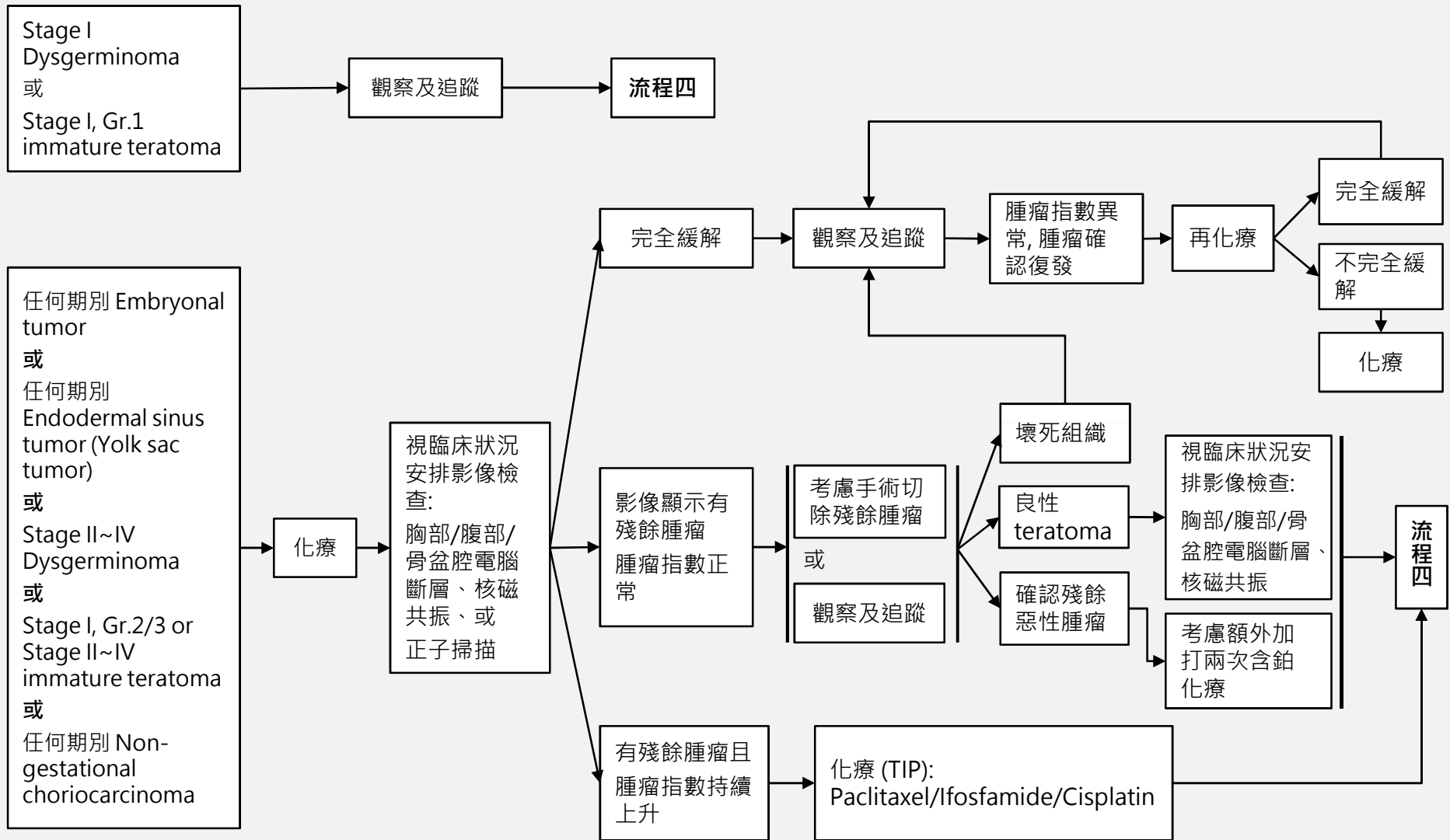
#: 疑似有卵巢惡性腫瘤的35歲以下年輕女性患者，在開始治療之前，建議檢查CA-125, AFP、hCG、LDH、CEA、CA-199

流程一

高雄榮總婦癌團隊 卵巢惡性生殖細胞癌 臨床治療指引



高雄榮總婦癌團隊 卵巢惡性生殖細胞癌 臨床治療指引



卵巢惡性生殖細胞癌追蹤及監測

1. 前兩年每2-4個月追蹤一次，第三-五年每3-6個月追蹤一次，之後每年追蹤一次。
2. 理學檢查及骨盆腔檢查
3. 每年胸部X光檢查
4. 必要時行婦科超音波檢查
5. 必要時行全血分析及生化檢查
6. 如臨床上有懷疑，可加做肺部、腹部或骨盆腔之電腦斷層、核磁共振掃描或正子攝影

流程四

第一線化學治療：

建議處方：

1. BEP (Bleomycin + Etoposide + Cisplatin) Q21 days, 3~4 cycles 【適合台灣人使用的配方及劑量】 (Ref 42, 48)
 - Cisplatin 100 mg/m² on D1
 - Etoposide 100 mg/m² on D1~3
 - Bleomycin 15 mg/m² on D1-3 (每天總劑量不超過25mg)

重要副作用

※ Pulmonary fibrosis

【危險因子】

- a. Bleomycin 終身累積劑量450 mg以上
- b. Bleomycin 單次劑量超過15 mg/m²
- c. 年紀超過70歲
- d. 肺氣腫
- e. 肺部曾經接受放射線治療

※ Acute myelogenous leukemia(AML)

【危險因子】

- a. Etoposide 累積劑量2000 mg/m²以上

※ 卵巢傷害

可能有益之預防措施：在化學治療開始之前與進行期間，考慮使用GnRH agonists或口服避孕藥

復發時化學治療：

建議處方 (有機會治癒)：

1. TIP (Paclitaxel 175 mg/m² + Ifosfamide + Mesna) 4gm/m² + Cisplatin 50mg/m²) Q3W, 6 cycles (Ref. 24)
2. 高劑量化療 (#)

其他處方 (緩和性)

1. VeIP (Vinblastine 0.11 mg/kg/d x 2d + Ifosfamide + Mesna) 4gm/m² + Cisplatin 50mg/m²) Q3W, 6 cycles (Ref.26)
2. Etoposide + Ifosfamide + Cisplatin (VIP) (Ref. 49)
3. Paclitaxel + carboplatin (Ref.51)
4. Paclitaxel+ ifosfamide (Ref.24)
5. Paclitaxel+ gemcitabine (Ref.50)

#: **High-dose chemotherapy**包含(Vinblastine + Ifosfamide + Cisplatin) x1 cycle + (Carboplatin 700 mg/m² + Etoposide 750 mg/m²) x 3d, followed by stem-cell infusion. 待 3-4 週 hematopoietic 恢復，進行第二個 course。(Ref.47)

治療應注意事項

- 患者的染色體若含有46,XY
 - 雙側的性腺應及早切除者
若為45,X/46,XY鑲嵌型或是46,XY，而且腹腔內的性腺呈發育不良(dysgenesis)者
 - 考慮等到青春期之後再摘除性腺者
若為46,XY，罹患雄性素反應不良症候群，而腹腔內性腺(即睪丸)的組織型態正常者
- 對側卵巢若外觀正常，則除了 dysgerminoma 或含有 dysgerminoma 成份的mixed germ cell tumor 以外，不宜做不必要的切片，以免造成卵巢提早衰竭或沾黏，損及日後的生育能力。
- 放射線治療僅限於：
 - 身體狀況不適合化學治療的dysgerminoma 患者，或
 - 經過多種化學治療後，仍有腫瘤相關之局部症狀者
 - 各種原因無法化學治療者，可考慮放射治療

REFERENCES

1. Badawy, A., A. Elnashar, et al. (2009). "Gonadotropin-releasing hormone agonists for prevention of chemotherapy-induced ovarian damage: prospective randomized study." *Fertil Steril* 91(3): 694-697.
2. Bjorkholm, E., M. Lundell, et al. (1990). "Dysgerminoma. The Radiumhemmet series 1927-1984." *Cancer* 65(1): 38-44.
3. Blum, R. H., S. K. Carter, et al. (1973). "A clinical review of bleomycin--a new antineoplastic agent." *Cancer* 31(4): 903-914.
4. Blumenfeld, Z. and M. von Wolff (2008). "GnRH-analogues and oral contraceptives for fertility preservation in women during chemotherapy." *Hum Reprod Update* 14(6): 543-552.
5. Boice, J. D., Jr., G. Engholm, et al. (1988). "Radiation dose and second cancer risk in patients treated for cancer of the cervix." *Radiat Res* 116(1): 3-55.
6. Bonazzi, C., F. Peccatori, et al. (1994). "Pure ovarian immature teratoma, a unique and curable disease: 10 years' experience of 32 prospectively treated patients." *Obstet Gynecol* 84(4): 598-604.
7. Comerci, J. T., Jr., F. Licciardi, et al. (1994). "Mature cystic teratoma: a clinicopathologic evaluation of 517 cases and review of the literature." *Obstet Gynecol* 84(1): 22-28.
8. Cushing, B., R. Giller, et al. (1999). "Surgical resection alone is effective treatment for ovarian immature teratoma in children and adolescents: a report of the pediatric oncology group and the children's cancer group." *Am J Obstet Gynecol* 181(2): 353-358.
9. Dark, G. G., M. Bower, et al. (1997). "Surveillance policy for stage I ovarian germ cell tumors." *J Clin Oncol* 15(2): 620-624.
10. de Wit, R., G. Stoter, et al. (1997). "Importance of bleomycin in combination chemotherapy for good-prognosis testicular nonseminoma: a randomized study of the European Organization for Research and Treatment of Cancer Genitourinary Tract Cancer Cooperative Group." *J Clin Oncol* 15(5): 1837-1843.
11. Dimopoulos, M. A., C. Papadimitriou, et al. (2004). "Treatment of ovarian germ cell tumors with a 3-day bleomycin, etoposide, and cisplatin regimen: a prospective multicenter study." *Gynecol Oncol* 95(3): 695-700.
12. Dos Santos, L., E. Mok, et al. (2007). "Squamous cell carcinoma arising in mature cystic teratoma of the ovary: a case series and review of the literature." *Gynecol Oncol* 105(2): 321-324.
13. Fallat, M. E. and P. K. Donahoe (2006). "Intersex genetic anomalies with malignant potential." *Curr Opin Pediatr* 18(3): 305-311.
14. Geisler, J. P., R. Goulet, et al. (1994). "Growing teratoma syndrome after chemotherapy for germ cell tumors of the ovary." *Obstet Gynecol* 84(4 Pt 2): 719-721.
15. Gershenson, D. M. (1988). "Menstrual and reproductive function after treatment with combination chemotherapy for malignant ovarian germ cell tumors." *J Clin Oncol* 6(2): 270-275.

REFERENCES

16. Gershenson, D. M. (1993). "Update on malignant ovarian germ cell tumors." *Cancer* 71(4 Suppl): 1581-1590.
17. Gershenson, D. M., M. Morris, et al. (1990). "Treatment of malignant germ cell tumors of the ovary with bleomycin, etoposide, and cisplatin." *J Clin Oncol* 8(4): 715-720.
18. Goldiner, P. L., G. C. Carlon, et al. (1978). "Factors influencing postoperative morbidity and mortality in patients treated with bleomycin." *Br Med J* 1(6128): 1664-1667.
19. Gordon, A., D. Lipton, et al. (1981). "Dysgerminoma: a review of 158 cases from the Emil Novak Ovarian Tumor Registry." *Obstet Gynecol* 58(4): 497-504.
20. Hart, W. R. and D. M. Burkons (1979). "Germ cell neoplasms arising in gonadoblastomas." *Cancer* 43(2): 669-678.
21. Horwich, A., D. T. Sleijfer, et al. (1997). "Randomized trial of bleomycin, etoposide, and cisplatin compared with bleomycin, etoposide, and carboplatin in good-prognosis metastatic nonseminomatous germ cell cancer: a Multiinstitutional Medical Research Council/European Organization for Research and Treatment of Cancer Trial." *J Clin Oncol* 15(5): 1844-1852.
22. Howell, S. and S. Shalet (1998). "Gonadal damage from chemotherapy and radiotherapy." *Endocrinol Metab Clin North Am* 27(4): 927-943.
23. Kanazawa, K., T. Suzuki, et al. (2000). "Treatment of malignant ovarian germ cell tumors with preservation of fertility: reproductive performance after persistent remission." *Am J Clin Oncol* 23(3): 244-248.
24. Kondagunta, G. V., J. Bacik, et al. (2005). "Combination of paclitaxel, ifosfamide, and cisplatin is an effective second-line therapy for patients with relapsed testicular germ cell tumors." *J Clin Oncol* 23(27): 6549-6555.
25. Loehrer, P. J., Sr., D. Johnson, et al. (1995). "Importance of bleomycin in favorable-prognosis disseminated germ cell tumors: an Eastern Cooperative Oncology Group trial." *J Clin Oncol* 13(2): 470-476.
26. Loehrer, P. J., Sr., R. Lauer, et al. (1988). "Salvage therapy in recurrent germ cell cancer: ifosfamide and cisplatin plus either vinblastine or etoposide." *Ann Intern Med* 109(7): 540-546.
27. Mann, J. R., F. Raafat, et al. (2000). "The United Kingdom Children's Cancer Study Group's second germ cell tumor study: carboplatin, etoposide, and bleomycin are effective treatment for children with malignant extracranial germ cell tumors, with acceptable toxicity." *J Clin Oncol* 18(22): 3809-3818.
28. Marina, N. M., B. Cushing, et al. (1999). "Complete surgical excision is effective treatment for children with immature teratomas with or without malignant elements: A Pediatric Oncology Group/Children's Cancer Group Intergroup Study." *J Clin Oncol* 17(7): 2137-2143.
29. McKeage, M. J., B. D. Evans, et al. (1990). "Carbon monoxide diffusing capacity is a poor predictor of clinically significant bleomycin lung. New Zealand Clinical Oncology Group." *J Clin Oncol* 8(5): 779-783.
30. Messing, M. J., D. M. Gershenson, et al. (1992). "Primary treatment failure in patients with malignant ovarian germ cell neoplasms." *Int J Gynecol Cancer* 2(6): 295-300.

REFERENCES

31. Motzer, R. J., N. L. Geller, et al. (1991). "Salvage chemotherapy for patients with germ cell tumors. The Memorial Sloan-Kettering Cancer Center experience (1979-1989)." *Cancer* 67(5): 1305-1310.
32. Nichols, C. R., E. S. Breeden, et al. (1993). "Secondary leukemia associated with a conventional dose of etoposide: review of serial germ cell tumor protocols." *J Natl Cancer Inst* 85(1): 36-40.
33. Norris, H. J., H. J. Zirkin, et al. (1976). "Immature (malignant) teratoma of the ovary: a clinical and pathologic study of 58 cases." *Cancer* 37(5): 2359-2372.
34. O'Connor, D. M. and H. J. Norris (1994). "The influence of grade on the outcome of stage I ovarian immature (malignant) teratomas and the reproducibility of grading." *Int J Gynecol Pathol* 13(4): 283-289.
35. Peccatori, F., C. Bonazzi, et al. (1995). "Surgical management of malignant ovarian germ-cell tumors: 10 years' experience of 129 patients." *Obstet Gynecol* 86(3): 367-372.
36. Pfannenber, C., P. Aschoff, et al. (2010). "PET/CT with 18F-FLT: does it improve the therapeutic management of metastatic germ cell tumors?" *J Nucl Med* 51(6): 845-853.
37. Pui, C. H. (1991). "Epipodophyllotoxin-related acute myeloid leukaemia." *Lancet* 338(8780): 1468.
38. Rim, S. Y., S. M. Kim, et al. (2006). "Malignant transformation of ovarian mature cystic teratoma." *Int J Gynecol Cancer* 16(1): 140-144.
39. Rogers, P. C., T. A. Olson, et al. (2004). "Treatment of children and adolescents with stage II testicular and stages I and II ovarian malignant germ cell tumors: A Pediatric Intergroup Study--Pediatric Oncology Group 9048 and Children's Cancer Group 8891." *J Clin Oncol* 22(17): 3563-3569.
40. Slayton, R. E., M. M. Hreshchyshyn, et al. (1978). "Treatment of malignant ovarian germ cell tumors: response to vincristine, dactinomycin, and cyclophosphamide (preliminary report)." *Cancer* 42(2): 390-398.
41. Tangjitgamol, S., S. Manusirivithaya, et al. (2003). "Squamous cell carcinoma arising from dermoid cyst: Case reports and review of literature." *Int J Gynecol Cancer* 13(4): 558-563.
42. Williams, S., J. A. Blessing, et al. (1994). "Adjuvant therapy of ovarian germ cell tumors with cisplatin, etoposide, and bleomycin: a trial of the Gynecologic Oncology Group." *J Clin Oncol* 12(4): 701-706.
43. Williams, S. D., J. A. Blessing, et al. (1994). "Second-look laparotomy in ovarian germ cell tumors: the gynecologic oncology group experience." *Gynecol Oncol* 52(3): 287-291.
44. Williams, S. D., J. A. Blessing, et al. (1989). "Cisplatin, vinblastine, and bleomycin in advanced and recurrent ovarian germ-cell tumors. A trial of the Gynecologic Oncology Group." *Ann Intern Med* 111(1): 22-27.

REFERENCES

45. Williams, S. D., J. Kauderer, et al. (2004). "Adjuvant therapy of completely resected dysgerminoma with carboplatin and etoposide: a trial of the Gynecologic Oncology Group." *Gynecol Oncol* 95(3): 496-499.
46. Zanetta, G., C. Bonazzi, et al. (2001). "Survival and reproductive function after treatment of malignant germ cell ovarian tumors." *J Clin Oncol* 19(4): 1015-1020.
47. Natraj Reddy Ammakkanavar, Daniela Matei, Rafat Abonour, Lawrence H Einhorn. (2015). High-dose chemotherapy for recurrent ovarian germ cell tumors. *J Clin Oncol*. 2015 Jan 10;33(2):226-7
48. 國家衛生研究院 婦癌臨床診療指引 (2011).
49. Stuart Hinton, Paul J Catalano, Lawrence H Einhorn, Craig R Nichols, E David Crawford, Nicholas Vogelzang, Donald Trump, Patrick J Loehrer Sr. (2003). Cisplatin, etoposide and either bleomycin or ifosfamide in the treatment of disseminated germ cell tumors: final analysis of an intergroup trial. *Cancer*. 2003 Apr 15;97(8):1869-75
50. Stuart Hinton, Paul Catalano, Lawrence H Einhorn, Patrick J Loehrer Sr, Timothy Kuzel, David Vaughn, George Wilding. (2002). Phase II study of paclitaxel plus gemcitabine in refractory germ cell tumors (E9897): a trial of the Eastern Cooperative Oncology Group. *J ClinOncol*. 2002 Apr 1;20(7):1859-63
51. M K B Parmar, J A Ledermann, N Colombo, A du Bois, J-F Delaloye, G B Kristensen, S Wheeler, A M Swart, W Qian, V Torri, I Floriani, G Jayson, A Lamont, C Tropé, ICON and AGO Collaborators. (2003) Paclitaxel plus platinum-based chemotherapy versus conventional platinum-based chemotherapy in women with relapsed ovarian cancer: the ICON4/AGO-OVAR-2.2 trial. *Lancet*. 2003 Jun 21;361(9375):2099-106