

# SURGICAL PATHOLOGY CONFERENCE

Presentation : R3 張道安 / 袁倫祥

2016/05/19

# Patient Profile

- Name: 簡 OO
- Gender: Female
- Age: 47
- Occupation: 家庭主婦
- Marital status: Married

# Chief Complaint

---

- RUQ fullness was noted for about 1 year

# Present Illness

- Abdominal fullness for about 1 year, RUQ palpable mass was noted in recent 2 months
- She denied any symptoms, such as
  - Fever, flank pain, hematuria, abdominal pain, body weight loss, diarrhea, malaise, constipation, hematochezia, jaundice

# Physical examination

- Vital signs: BP: 117/74 mmHg, PR: 72/min, RR: 18/min, BT: 36.2°C
- Sclera: not icteric
- No lymphadenopathy
- Liver
  - 10cm below right costal margin
  - Firm, nontender, moves with respiration

# Past history

---

- Denied history of hepatitis B or C
- Denied other systemic disease
- Denied operation history

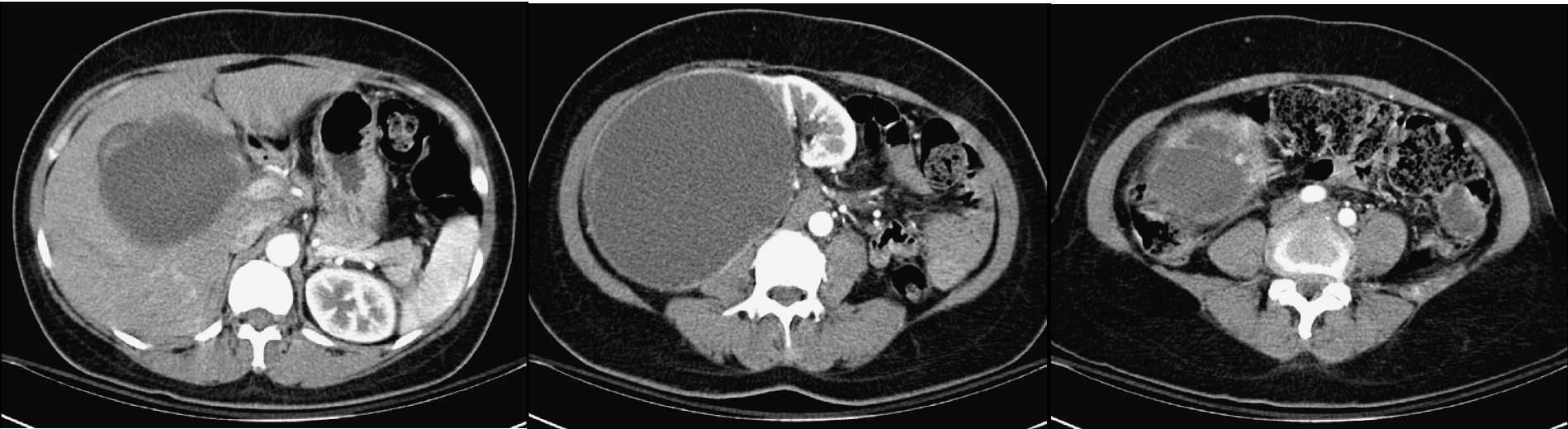
# Lab data

---

- CBC: within normal range
- Liver function: within normal range
- Renal function: within normal range
- Electrolyte: within normal range

# CT

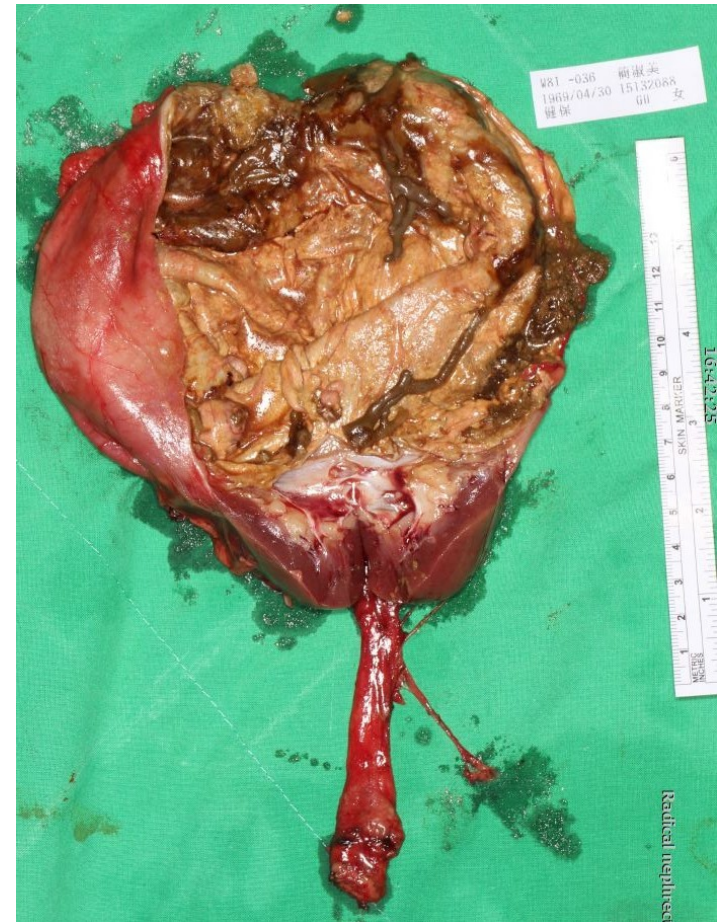
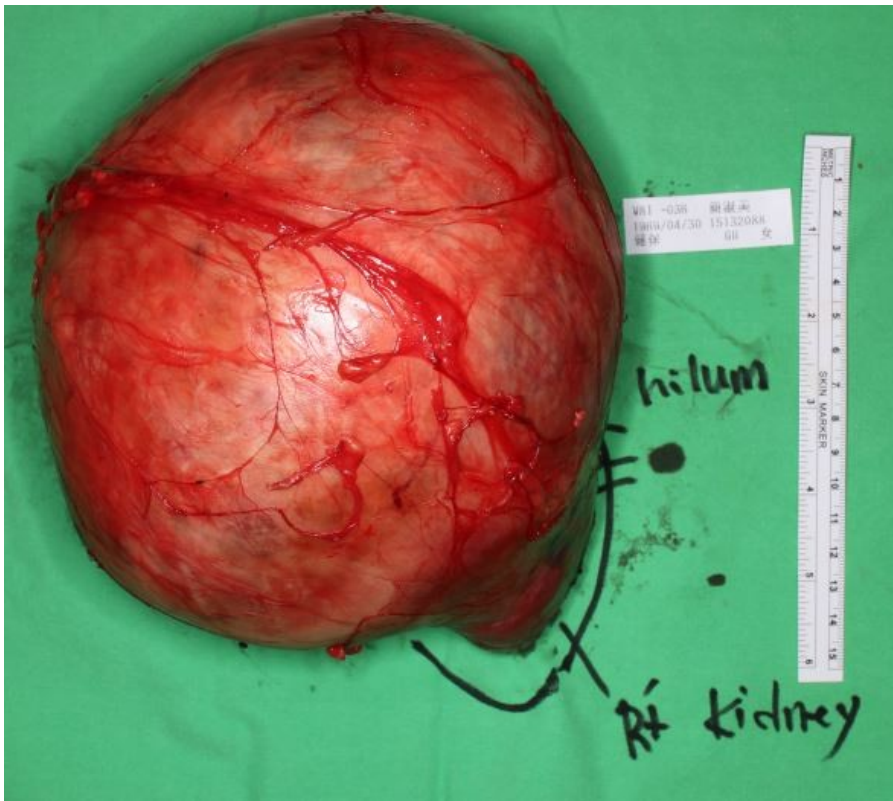
- RT huge cystic tumor, 15 cm, dorsal cortex, in favor of RCC, limited to kidney (T2bN0M0)





# Surgery and specimen

- Radical nephrectomy, right on 2015/08/03



# Final diagnosis

- MITF/TFE family translocation-associated carcinoma of kidney, right, pT2bN0M0 (Furman grade 3)

# Follow up

---

- 2015/09/23 Abd CT
  - No evidence of recurrence
  
- 2016/03/28 Abd Sonography
  - No evidence of recurrence