

高雄榮民總醫院

下咽癌診療原則

2024年05月01日 第一版

頭頸癌醫療團隊擬訂

注意事項：這個診療原則主要作為醫師和其他保健專家診療癌症病人參考之用。假如你是一個癌症病人，直接引用這個診療原則並不恰當，只有你的醫師才能決定給你最恰當的治療。

會議討論

上次會議:2023/3/22

本共識與上一版的差異

上一版	新版
<ol style="list-style-type: none">1. Multidisciplinary team adjunctive service增加pain management。Supportive service增加Physical therapy (lymphedema management)。2. Most T1,N0, selected T2,N0 (amenable to larynx preserving [conservation] surgery)，將adverse feature(-)分成N0 without adverse feature Follow up，N1 without adverse feature Consider RT。3. Response after I/C，for T4a,N0-3，在Primary site PR and stable or improved disease in Neck的治療選項中加入surgery。4. 針對Initial M1且PS3，新增single-agent systemic therapy。5. 針對Recurrent or persistent disease with M1，建議NGS。6. CCRT/RT後有response，且8-12wks後Imaging positive，可做PET(≥ 12wk)，或者ND(if confirmed residual/persistent/progression)。	<ol style="list-style-type: none">1. 診斷後應screening HBV(業已列為本院guideline)2. 多數T1N0及selected T2N0的患者，手術時不一定要同時接受同側甲狀腺切除3. T1-4a, N1-3的患者，可視情況做單側或雙側頸部淋巴結廓清手術(Bil ND was recommended in post-cricoid and posterior pharyngeal wall; however,bilateral ND was still suggested in patients with pyriform sinus tumor)4. Oral UFUR(2#BID or 1#TID)可作為取代iv-formed 5-FU之替代藥物5. Nutrition support應優先考慮腸道營養(NG, PEG)

Carcinoma of Hypopharynx

高雄榮民總醫院 臨床診療指引 Ver.1 修訂於 2024.05.01 Page 1 (Ref. 1,2)

WORK-UP

- History & PE
- Biopsy & Pathology
- Image
 - MRI* or CT of H&N* or PET
 - WBBS* (if PET/CT not done)/ Abd.Sono*/CXR*
 - PES
 - ± Chest CT(upper med.) (*if PET/CT not done)
 - ± Neck sono
- Dental evaluation
 - Panorex ± teeth extraction
- Multidisciplinary consultation (Fertility/reproductive, smoking cessation)
- ± Swallowing/speech
- ± p16 status
- ± Pulmonary function if conservation surgery
- **HBV/HCV screening**
(* 期別之相關之主要檢查)

STAGING & TREATMENT

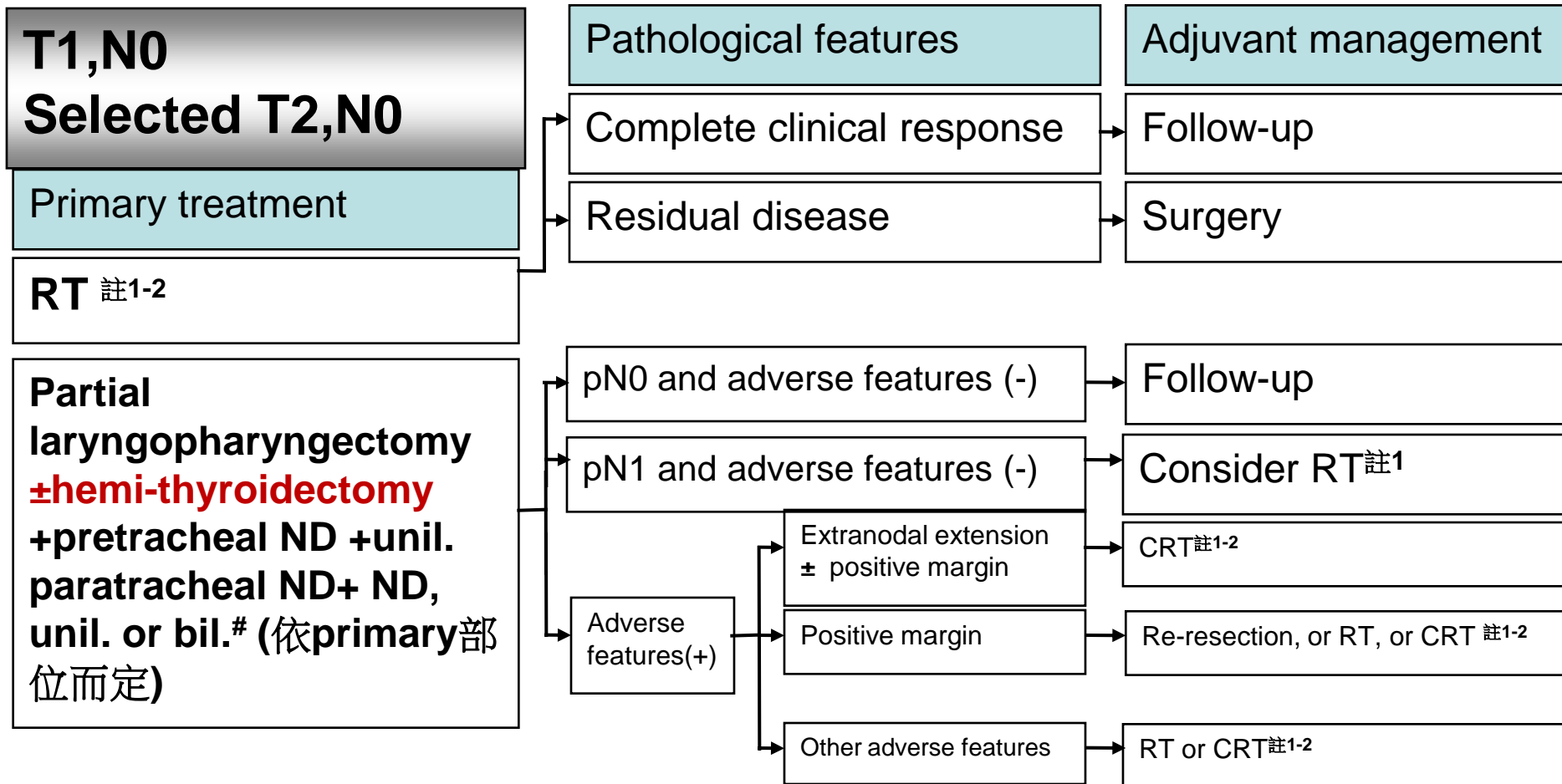
- [T1, N0 or Selected T2, N0, M0]
詳見 Page 2
- [T2-3, any N; T1, N1-3, M0]
詳見 Page 3
- [T4a, any N, M0]
詳見 Page 5
- [T4b, any N, M0 or Inoperable status]
詳見 Page 6
- M1
詳見 Page 7

FOLLOW-UP

- [Post-Tx within 3-6 months]
 - Baseline MRI or CT (PET)
 - Every 1-2 months: PE
- [2nd year after Tx]
 - Every 2-3 months: PE
- [3-5 years after Tx]
 - Every 4-8 months: PE
- [5 years after Tx]
 - Every 12 months: PE
- Every year:
H & N MRI or CT, CxR, Bone scan & Abd. Sono, Neck Sono, PES, TSH, free T4(if RT, 6-12 months) As clinically indicated

Carcinoma of Hypopharynx

高雄榮民總醫院 臨床診療指引 Ver.1 修訂於 2024.05.01 Page 2 (Ref. 1,2)

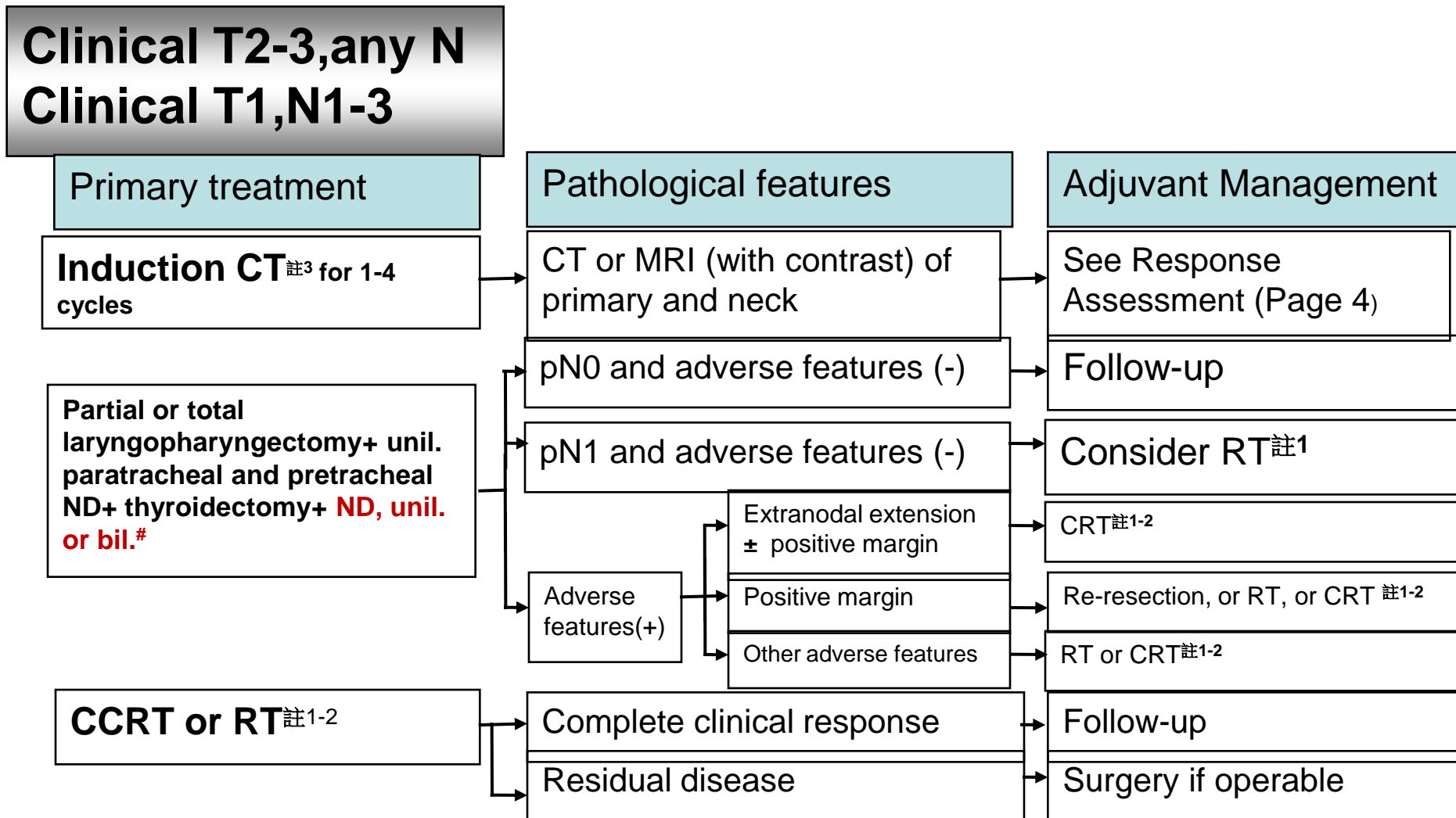


Bil ND was recommended in post-cricoid and posterior pharyngeal wall; however, bilateral ND was still suggested in patients with pyriform sinus tumor

* Adverse features : Extranodal extension, positive or close margins, pT3 or pT4 primary, pN2 or pN3 nodal disease, perineural invasion, lymphovascular invasion

Carcinoma of Hypopharynx

高雄榮民總醫院 臨床診療指引 Ver.1 修訂於 2024.05.01 Page 3 (Ref. 1,2)

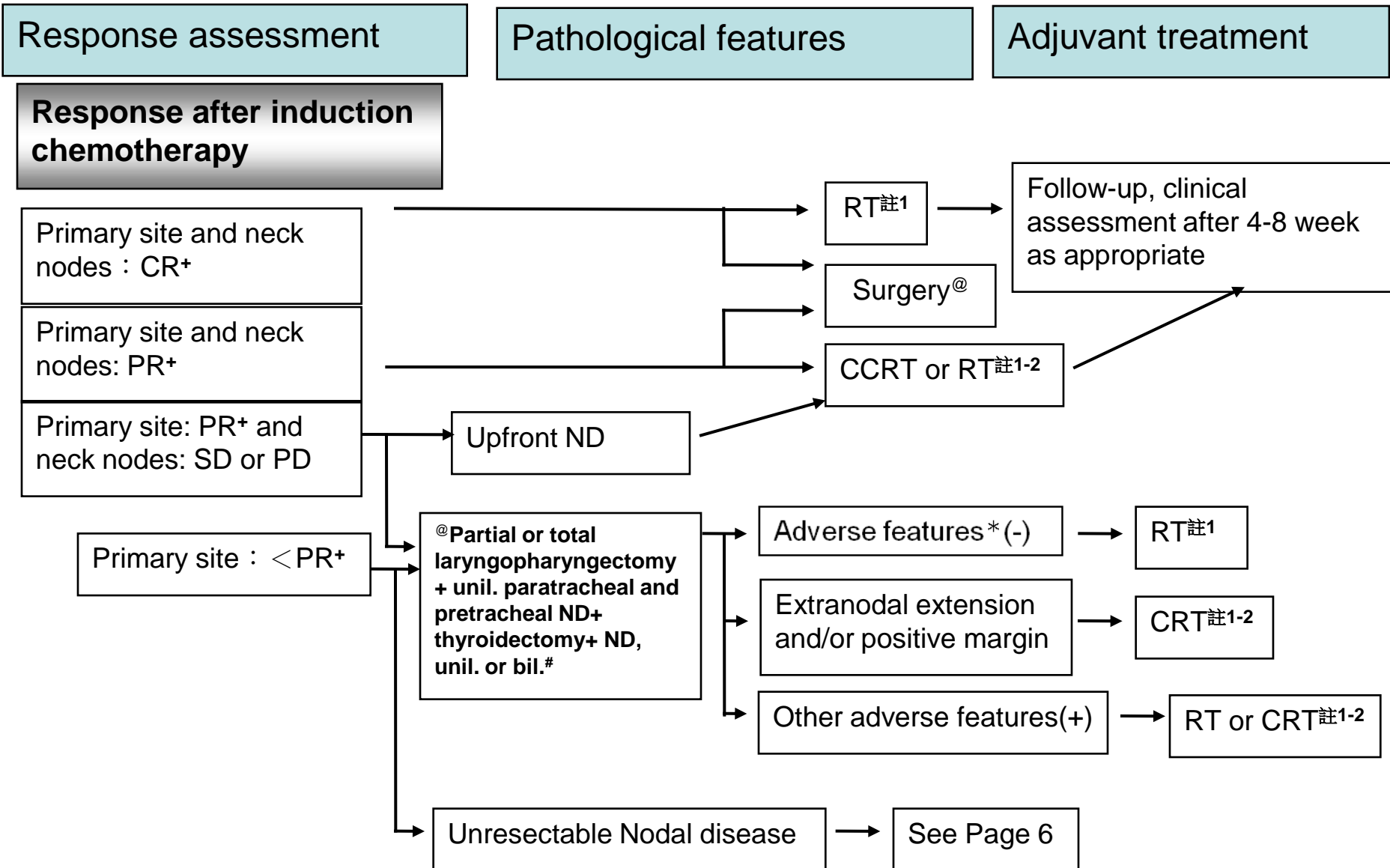


Bil ND was recommended in post-cricoid and posterior pharyngeal wall; however, bilateral ND was still suggested in patients with pyriform sinus tumor

* Adverse features : Extranodal extension, positive or close margins, pT3 or pT4 primary, N2 or N3 nodal disease, perineural invasion, lymphovascular invasion

Carcinoma of Hypopharynx

高雄榮民總醫院 臨床診療指引 Ver.1 修訂於 2024.05.01 Page 4 (Ref. 1,2)



+ Primary site evaluated by CT or MRI(with contrast) of primary head and neck

* Adverse features : extranodal extension, positive margins, close margins, pT4 primary, pN2 or pN3 nodal disease, perineural invasion, vascular invasion, lymphatic invasion

Carcinoma of Hypopharynx

高雄榮民總醫院 臨床診療指引 Ver.1修訂於 2024.05.01 Page 5 (Ref. 1,2)

Clinical T4a, any N

Primary treatment

Total laryngopharyngectomy+
hemi- or total thyroidectomy,
ND, unil. or bil.# + paratracheal
ND, unil. or bil.

Pathological features

Extranodal extension and/or
positive margin

Other adverse features

Adjuvant Management

CRT or RT^{註1-2}

RT or CRT^{註1-2}

Select T4a patients (high PS, multiple comorbidity or decline surgery)

Induction CT^{註3} for 1-4
cycles

CT or MRI (with contrast) of
primary and neck

See Response
Assessment (Page 4)

CCRT or RT^{註1-2}

Complete clinical response

Follow-up

Residual disease

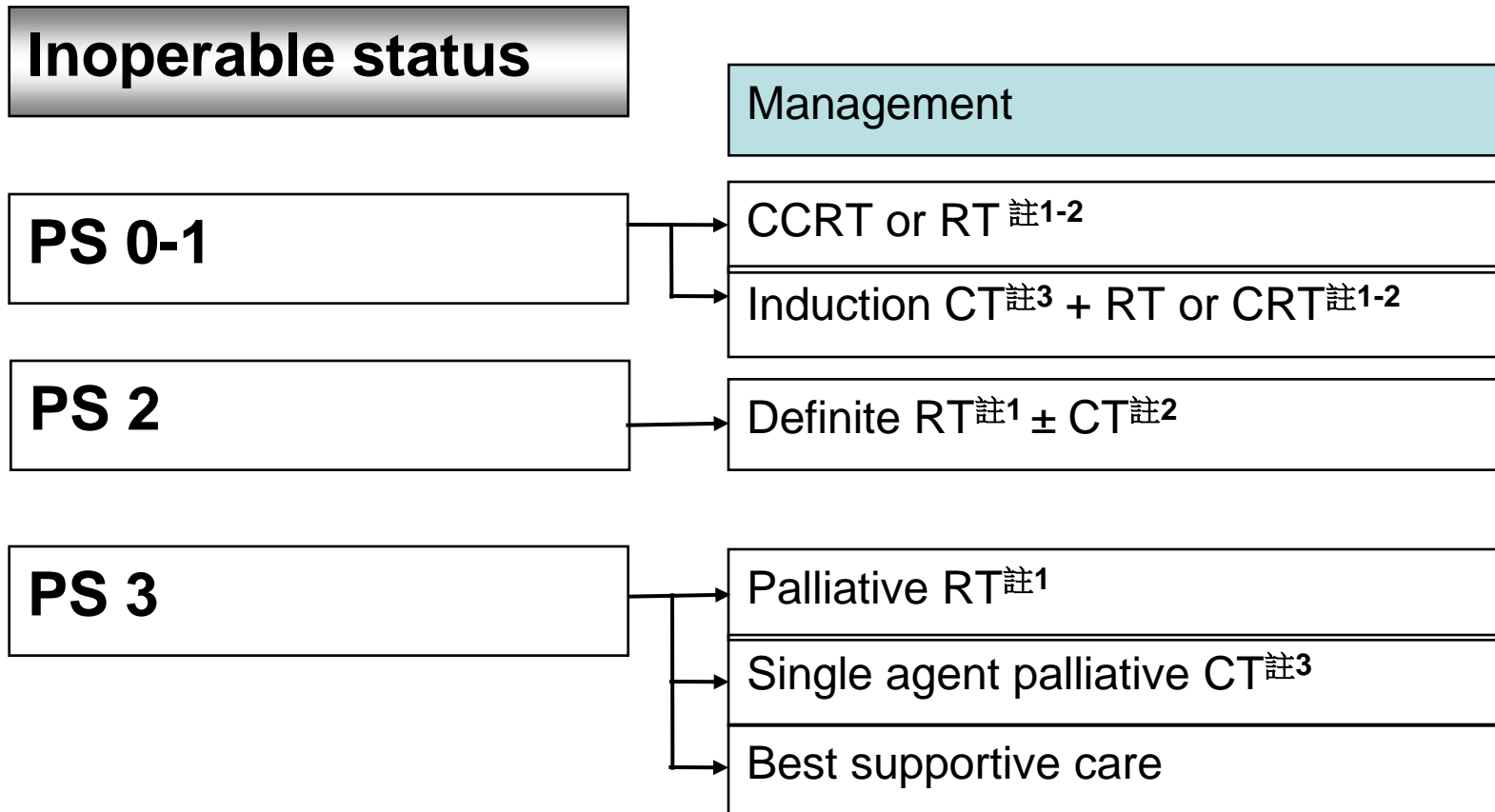
Surgery if operable

Neck dissection level 依primary部位及cN status而定。

* Adverse features : Extranodal extension, positive or close margins, pT3 or pT4 primary, N2 or N3 nodal disease, perineural invasion, lymphovascular invasion

Carcinoma of Hypopharynx

高雄榮民總醫院 臨床診療指引 Ver.1修訂於 2024.05.01 Page 6 (Ref. 1,2)



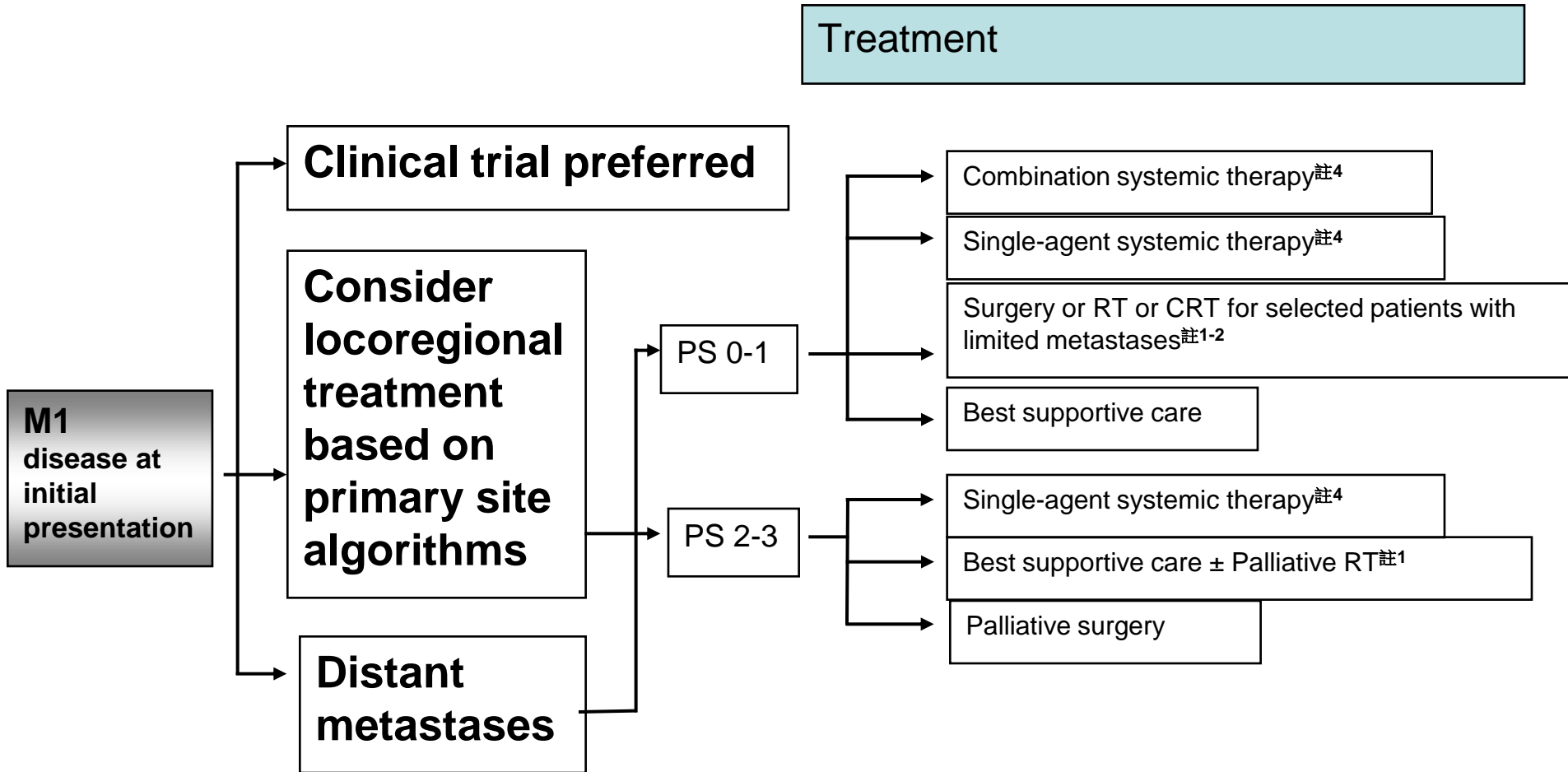
ECOG Performance Status 0-1^{註6}

ECOG Performance Status 2

ECOG Performance Status 3

Carcinoma of the Hypopharynx

高雄榮民總醫院 臨床診療 Ver.1 修訂於 2024.05.01 Page 7 (Ref. 15-17)



1. PS 0-1若治療無效，除 best supportive care 外可再考慮systemic therapy, clinical trial or palliative RT
2. PS 2-3 single agent systemic therapy 若治療無效，除 best supportive care 外可再考慮 alternate single agent systemic therapy or palliative RT

Carcinoma of Hypopharynx

高雄榮民總醫院 臨床診療指引 Ver.1 修訂於 2024.05.01 Page 8 (Ref. 3-5)

註1

Principles of Radiotherapy

Definitive Radiotherapy

- Primary and gross adenopathy : 66 - 74Gy (2.0-2.2 Gy/fraction)
- Low to intermediate risk : 44 - 64 Gy (2.0 Gy/fractions) in 3D RT, 54- 63 Gy (1.6-1.8 Gy/fractions)

Postoperative Radiotherapy

- Preferred interval between operation and radiotherapy is ≤ 6 weeks.
- High risk(adverse feature) : 60 - 66 Gy (2.0 Gy/fraction)
- Low to intermediate risk : 44 - 64 Gy (2.0 Gy/fractions) in 3D RT, 54- 63 Gy (1.6-1.8 Gy/fractions)

CCRT or RT

- RT alone if old age, impaired renal function, poor condition or refused chemotherapy

Palliative RT

- Indicated in : relieve local symptoms, prevent debilitation such as spinal cord compression and pathological fracture, achieve durable locoregional control.

Carcinoma of Hypopharynx

註2

高雄榮民總醫院 臨床診療指引 Ver.1修訂於 2024.05.01 Page 9 (Ref. 6-10)

Principles of Chemotherapy

Concurrent with RT

Regimen 1: q3w CDDP ± Cetuximab^{註5} + RT

- Cisplatin (80-100mg/ m²) q3w during R/T
- Cetuximab(400mg/ m²) loading dose first week, then Cetuximab(250mg/ m²) maintain dose D1 + Cisplatin (80-100mg/ m²) q3w D2 during R/T

Regimen 2: Weekly CDDP ± Cetuximab^{註5} + RT

- Cisplatin (30-40mg/ m²) weekly during R/T
- Cetuximab(400mg/ m²) loading dose first week, and then Cisplatin (30-40mg/ m²) weekly D1 + Cetuximab(250mg/ m²) maintain dose D2 during R/T

Regimen 3: q3w Carboplatin^{註5} ± Cetuximab^{註5} + RT

- Carboplatin (AUC x 5mg) q3w during R/T
- Cetuximab(400mg/ m²) loading dose first week, then Cetuximab(250mg/ m²) maintain dose D1 + Carboplatin (AUC x 5mg) q3w D2 during R/T

Regimen 4: Weekly Cetuximab^{註5} + RT

- Cetuximab(400mg/ m²) loading dose first week, then Cetuximab(250mg/ m²) maintain dose during RT

Regimen5: Carboplatin + 5-FU + Hydroxyurea (CCr < 60) + RT

- Carboplatin (AUC x 1.25mg) D1-D4
- Fluorouracil (5-FU) (850mg/m²) D1-D4
- Hydroxyurea 1CAP BID D1-D5

Regimen6: Cisplatin + 5-FU + Hydroxyurea + RT

- Cisplatin(20mg/ m²) D1-D4
- Fluorouracil (5-FU) (850mg/m²) D1-D4
- Hydroxyurea 1CAP BID D1-D5

Regimen 7: Doxetaxel + RT

- Doxetaxel (60g/m²) D1, if cisplatin not eligible

Carcinoma of Hypopharynx

註3

高雄榮民總醫院 臨床診療指引 Ver.1修訂於 2024.05.01 Page 10 (Ref. 11-15)

Regimens of Chemotherapy

Induction, adjuvant, 建議1-4cycles

Regimen 1 : q3-4 weeks T^{註5} + P ± F (5-FU or UFUR) ± weekly Cetuximab^{註5}

- Taxotere(60 mg/ m²) D1
- Cisplatin(60-75 mg/ m²) D1
- Fluorouracil (5-FU) (600-750mg/m²) D2-D5 or **UFUR**
- Cetuximab (400mg/ m²) loading dose first week, then Cetuximab (250mg/ m²) maintain dose

Regimen 2: q3-4 weeks Platinum ± F (5-FU or UFUR) ± weekly Cetuximab^{註5}

- Cisplatin(80-100mg/ m²) D1 or Cisplatin (20mg/ m²) D1-D5 or Carboplatin (AUC x 5mg) D1
- Fluorouracil (5-FU) (600-1000mg/m²) or **UFUR** D2-D5
- Cetuximab(400mg/m²) loading dose first week, then weekly Cetuximab (250mg/ m²)

Carcinoma of Hypopharynx

註3

高雄榮民總醫院 臨床診療指引 Ver.1修訂於 2024.05.01 Page 11 (Ref. 11-15)

Regimens of Chemotherapy

Induction, adjuvant, 建議1-4cycles

Regimen 3: weekly Cetuximab^{註5}

- Cetuximab (400mg/ m²) loading dose first week, then Cetuximab (250mg/ m²) maintain dose

Regimen 4: oral Fluorouracil

- Ufur cap (tegafur 100mg+uracil 224mg) 2# BID-TID
(可作為取代iv-formed 5-FU之替代藥物)

Regimen 5: weekly Methotrexate

- Methotrexate (40-60mg/ m²)

Carcinoma of Hypopharynx

註4

高雄榮民總醫院 臨床診療指引 Ver.1修訂於 2024.05.01 Page 12 (Ref. 16,17)

Regimens of Chemotherapy

Recurrent, unresectable, metastatic *

Regimen 1 (First line): q3 weeks Pembrolizumab^{註5} ± Platinum ± F

- Pembrolizumab(200mg) D1
- Cisplatin(80-100mg/m²) D1 or Cisplatin (20mg/ m²) D1-D5 or Carboplatin (AUC x 5mg) D1
- Fluorouracil (5-FU) (600-1000 mg/m²) D2-D5

Regimen 2 (First line): q3 weeks Pembrolizumab^{註5}

- Pembrolizumab(200mg) D1 (if CPS ≥ 1)

Regimen 3 (Subsequent line): q2 weeks Nivolumab^{註5}

- Nivolumab(3mg/kg) D1

Regimen 4 (Subsequent line): q3 weeks Pembrolizumab^{註5}

- Pembrolizumab(200mg) D1 (if disease progression on or after platinum therapy)

Regimen 5: q3-4 weeks Platinum ± F ± weekly Cetuximab^{註5}

- Cisplatin(80-100mg/ m²) D1 or Cisplatin (20mg/ m²) D1-D5 or Carboplatin (AUC x 5mg) D1
- Fluorouracil (5-FU) (600-1000 mg/m²) D2-D5
- Cetuximab(400mg/ m²) loading dose first week, then weekly Cetuximab (250mg/ m²)

Regimen 6: q3 weeks Pembrolizumab^{註5} + Platinum + Doxetacel

- Pembrolizumab(200mg) D1
- Cisplatin(80-100mg/ m²) D1 or Cisplatin (20mg/ m²) D1-D5 or Carboplatin (AUC x 5mg) D1
- Taxotere(60 mg/ m²)

*針對Recurrent or persistent disease with M1，建議NGS

Carcinoma of Hypopharynx

註4

高雄榮民總醫院 臨床診療指引 Ver.1修訂於 2024.05.01 Page 13 (Ref. 16,17)

Regimens of Chemotherapy

Recurrent, unresectable, metastatic *

Regimen 7: q3-4 weeks T ± Platinum ± weekly Cetuximab^{註5}

- Taxotere (60 mg/ m²) D1
- Cisplatin (60-75 mg/ m²) D1 or Carboplatin (AUC x 5mg) D1
- Cetuximab (400mg/ m²) loading dose first week, then weekly Cetuximab (250mg/ m²)

Regimen 8: cisplatin+ epirubicin+ 5-FU+ Leucovorin

- Cisplatin (60 mg/ m²) D1
- Epirubicin (50 mg/ m²) D1
- Fluorouracil (5-FU) (2000 mg/m²) D1

Regimen 9: q2 weeks Bevacizumab

- Bevacizumab (200 mg/ m²) D1

Regimen 10: weekly Gemcitabine

- Gemcitabine (1000 mg/m²) D1

* 針對 Recurrent or persistent disease with M1，建議 NGS

Carcinoma of Hypopharynx

註5

高雄榮民總醫院 臨床診療指引 Ver.1修訂於 2024.05.01 Page 14

特殊用藥健保給付規定

Taxotere

- 頭頸部癌，限局部晚期且無遠端轉移之頭頸部鱗狀細胞癌且無法手術切除者。
- 與Cisplatin 及5-FU 併用，作為放射治療前的引導治療，限使用四個療程。

Cetuximab

- 限與放射線療法合併使用於局部晚期之口咽癌、下咽癌及喉癌患者，使用總療程以接受8次輸注為上限，需經事前審查核准後使用，且符合下列條件之一：
 - 1.年齡 ≥ 70 歲
 - 2.Ccr < 50 ml/min
 - 3.聽力障礙者 (聽力障礙定義為500Hz、1000Hz、2000Hz 平均聽力損失大於25 分貝)
 - 4.無法耐受platinum-based 化學治療
- 限無法接受局部治療之復發及/或轉移性頭頸部鱗狀細胞癌，且未曾申報 cetuximab 之病患使用。使用總療程以18週為限，每9週申請一次，需無疾病惡化情形方得繼續使用。

Carboplatin

- 限腎功能不佳 (CCr < 60) 或曾作單側或以上腎切除之惡性腫瘤患者使用。

Carcinoma of Hypopharynx

註5

高雄榮民總醫院 臨床診療指引 Ver.1修訂於 2024.05.01 Page 15

特殊用藥健保給付規定

Pembrolizumab、Nivolumab

• 先前已使用過 platinum 類化學治療失敗後，又有疾病惡化的復發或轉移性頭頸部鱗狀細胞癌成人患者。本類藥品與 cetuximab 僅能擇一使用，且治療失敗時不可互換。

• 符合下列條件：

1. 病人身體狀況良好(ECOG \leq 1)
2. NYHA (the New York Heart Association) Functional Class I 或 II
3. GOT < 60U/L 及 GPT < 60U/L，且 T-bilirubin < 1.5mg/dL；Creatinine < 1.5mg/dL，且 eGFR > 60mL/min/1.73m²
4. PD-L1 表現量 TPS \geq 50%

• 初次申請以 12 週為限，申請時需檢附以下資料：病理或細胞檢查報告、生物標記(PD-L1)表現量檢測報告、病人身體狀況良好(ECOG \leq 1) 及心肺與肝腎功能之評估資料、符合 i-RECIST 定義之影像檢查及報告(上述影像檢查之給付範圍不包括 PET)、先前已接受過之治療與完整用藥資料、使用免疫檢查點抑制劑之治療計畫(treatment protocol)。

• 用藥後每 12 週評估一次，以 i-RECIST 或 mRECIST 標準評定反應，依下列原則給付：

- I. 有療效反應者(PR 及 CR)得繼續使用；
- II. 出現疾病惡化(PD)或出現中、重度或危及生命之藥物不良反應時，應停止使用；
- III. 疾病呈穩定狀態者(SD)，可持續再用藥 4 週，並於 4 週後再次評估，經再次評估若為 PR、CR 者，得再繼續使用 12 週。若仍為 SD 或已 PD 者，應停止使用。

Carcinoma of Hypopharynx

註6

高雄榮民總醫院 臨床診療指引 Ver.1 修訂於 2024.05.01 Page 16

Eastern Cooperative Oncology Group (ECOG) Performance Status

Grade	Description	Suggestion
0	Normal activity fully ambulatory (無症狀)	按照標準化療評估及療程。
1	Symptoms, but nearly fully ambulatory (有症狀，完全步行，但對生活無影響)	按照標準化療評估及療程。
2	Some bed time, but needs to be in bed less than 50% of normal daytime (躺在床上的時間<50%)	按照標準化療評估及療程。
3	Needs to be in bed more than 50% of normal daytime (躺在床上的時間>50%)	可視情況考慮停止化學治療。
4	Unable to get out of bed (長期完全臥床)	建議停止化學治療。
5	Dead	

Carcinoma of Hypopharynx

References

高雄榮民總醫院 臨床診療指引 Ver.1修訂於 2024.05.01 Page 17

1. NCCN Clinical Practice Guidelines in Oncology – Head and Neck Cancers Version 1. 2024
2. Hsieh MC, Wang CC, Yang CC, Lien CF, Wang CC, Shih YC, Yeh SA, Hwang TZ. Tegafur-Uracil versus 5-Fluorouracil in Combination with Cisplatin and Cetuximab in Elderly Patients with Recurrent or Metastatic Head and Neck Squamous Cell Carcinoma: A Propensity Score Matching Analysis. *Biology (Basel)*. 2021 Oct 8;10(10):1011. doi: 10.3390/biology10101011. PMID: 34681110; PMCID: PMC8533478.
3. AJCC (American Joint Committee on Cancer) Manual for Staging of Cancer, 8th ed, Amin M, Edge S, Greene F, et al. (Eds), Springer-Verlag, New York 2017.
4. Peter AP, Michael EC, Greg D, et al. Up-front neck dissection followed by concurrent chemoradiation in patients with regionally advanced head and neck cancer. *Head Neck*. 2012;34:1798-1803
5. Bradley, PJ, MacLennan, K, Brakenhoff, RH, Leemans, CR. Status of primary tumour surgical margins in squamous head and neck cancer: prognostic implications. *Curr Opin Otolaryngol Head Neck Surg* 2007; 15:74.
6. Vermorken JB, Remenar E, van Herpen C, Gorlia T, Mesia R, Degardin M, Stewart JS, Jelic S, Betka J, Preiss JH, et al. Cisplatin, fluorouracil, and docetaxel in unresectable head and neck cancer. *N Engl J Med*. 2007 Oct 25; 357(17):1695-704
7. Forastiere AA, Zhang Q, Weber RS, et al. Long-term results of RTOG 91-11: a comparison of three nonsurgical treatment strategies to preserve the larynx in patients with locally advanced larynx cancer. *J Clin Oncol* 2013;31:845-852.
8. Adelstein DJ, Li Y, Adams GL, et al. An intergroup phase III comparison of standard radiation therapy and two schedules of concurrent chemoradiotherapy in patients with unresectable squamous cell head and neck cancer. *J Clin Oncol* 2003;21(1):92-98.
9. Bonner JA, Harari PM, Giralt J, et al. Radiotherapy plus cetuximab for locoregionally advanced head and neck cancer: 5-year survival data from a phase 3 randomised trial, and relation between cetuximab-induced rash and survival. *Lancet Oncol* 2010;11:21-28
10. Denis F, Garaud P, Bardet E, et al. Final results of the 94-01 French Head and Neck Oncology and Radiotherapy Group randomized trial comparing radiotherapy alone with concomitant radiochemotherapy in advanced-stage oropharynx carcinoma. *J Clin Oncol* 2004;22:69-76
11. Bourhis J, Sire C, Graff P, et al. Concomitant chemoradiotherapy versus acceleration of radiotherapy with or without concomitant chemotherapy in locally advanced head and neck carcinoma (GORTEC 99-02): an open-label phase 3 randomised trial. *Lancet Oncol* 2012;13:145-153.
12. Forastiere AA, Zhang Q, Weber RS, et al. Long-term results of RTOG 91-11: a comparison of three nonsurgical treatment strategies to preserve the larynx in patients with locally advanced larynx cancer. *J Clin Oncol* 2013;31:845-852.
13. Adelstein DJ, Li Y, Adams GL, et al. An intergroup phase III comparison of standard radiation therapy and two schedules of concurrent chemoradiotherapy in patients with unresectable squamous cell head and neck cancer. *J Clin Oncol* 2003;21(1):92-98.
14. Bonner JA, Harari PM, Giralt J, et al. Radiotherapy plus cetuximab for locoregionally advanced head and neck cancer: 5-year survival data from a phase 3 randomised trial, and relation between cetuximab-induced rash and survival. *Lancet Oncol* 2010;11:21-28. Denis F, Garaud P, Bardet E, et al. Final results of the 94-01 French Head and Neck Oncology and Radiotherapy Group randomized trial comparing radiotherapy alone with concomitant radiochemotherapy in advanced-stage oropharynx carcinoma. *J Clin Oncol* 2004;22:69-76.
15. Bourhis J, Sire C, Graff P, et al. Concomitant chemoradiotherapy versus acceleration of radiotherapy with or without concomitant chemotherapy in locally advanced head and neck carcinoma (GORTEC 99-02): an open-label phase 3 randomised trial. *Lancet Oncol* 2012;13:145-153.
16. Posner MR, Hershock DM, Blajman CR, Mickiewicz E, Winquist E, Gorbounova V, Tjulandin S, Shin DM, Cullen K, Ervin TJ, et al. Cisplatin and fluorouracil alone or with docetaxel in head and neck cancer. *N Engl J Med*. 2007 Oct 25; 357(17):1705-1
17. Vermorken JB, Mesia, R, Rivera F, Platinum-Based Chemotherapy plus Cetuximab in Head and Neck Cancer *N Engl J Med*. 2008 Sep 11; 359:1116-27