

高雄榮民總醫院

上喉癌診療原則

2025年02月19日第一版

頭頸癌醫療團隊擬訂

注意事項：這個診療原則主要作為醫師和其他保健專家診療癌症病人參考之用。假如你是一個癌症病人，直接引用這個診療原則並不恰當，只有你的醫師才能決定給你最恰當的治療。

會議討論

上次會議日期:2024/05/29

本共識與上一版的差異

上一版	新版
<ol style="list-style-type: none">1. 診斷後應screening HBV(業已列為本院 guideline)2. 在可接受喉保留手術的病患(分期為 T1,T2,selected T3)，手術建議由partial supraglottic laryngectomy 改為 partial laryngectomy3. Oral UFUR(2#BID or 1#TID)可作為取代 iv-formed 5-FU之替代藥物4. Nutrition support應優先考慮腸道營養(NG, PEG)	<p>2025 ver.1 無更改</p>

Carcinoma of the Supraglottic Larynx

高雄榮民總醫院 臨床診療指引 Ver.1.2025 Page 1 (Ref. 1-2)

WORK-UP

- History(pack yr smoked) & PE; fiberoptic exam
- Biopsy of primary site or FNA of the neck
- Contrast and thin angled cuts **CT of larynx* and/or MRI with contrast of primary and neck***
- **Bone scan*** (若有PET，可不做此項)
- **Abd. Sono***
(*與期別相關之主要檢查)

- 臨床需求時安排以下檢查
- ✓Chest CT (with or without contrast)
- ✓Consider FDG PET/CT

- ✓Preanesthesia studies
- ✓Pulmonary function evaluation for conservation surgery candidates
- ✓Consider videostrobe for select patients
- ✓EUA with endoscopy
- ✓Neck Sono
- ✓Panendoscopy
- ✓Dental evaluation
Panorex ± teeth extraction
- ✓Nutrition, Speech and Swallowing evaluation/therapy
- ✓Audiogram
- ✓Smoking cessation counseling
- ✓Fertility/reproductive counseling
- HBV/HCV screening

STAGING & TREATMENT

- [Amenable to larynx-preserving (conservation) surgery (Most T1-2, N0; Select T3)] 詳見 Page 2
- [Requiring (amenable to) total laryngectomy (T3,N0)] 詳見 Page 3
- [Node-positive disease] 詳見 Page 5
- [Amenable to larynx-preserving (conservation) surgery (T1-2, N+ and selected T3,N1)] 詳見 Page 6
- [Requiring (amenable to) total laryngectomy (Most T3, N1-3)]
詳見 Page 7
- [T4a, N0-3] 詳見 Page 8
- [T4b, N1-3 or Unresectable nodal disease or Unfit for surgery]
詳見 Page 9
- [M1] 詳見Page 10

FOLLOW-UP

(base on risk of relapse, second primaries. Treatment sequelae, and toxicities)

- [Post-Tx within 1 year]
 - Every 1-3 months: complete head and neck exam + fiberoptic examination
 - Baseline CT or MRI
 - ± Neck Sono
- [1-2 years after Tx]
 - Every 2-6 months: complete head and neck exam + fiberoptic examination
 - Clinical indicated every 1 year: Larynx CT or MRI, CXR, Bone scan & Abd. Sono ± Neck Sono ±TSH, free T4*
- [3-5 years after Tx]
 - Every 4-8 months: complete head and neck exam + fiberoptic examination
- [5 years later after Tx]
 - Every 12 months: complete head and neck exam + fiberoptic examination
(*if RT, every 6-12 months)

Carcinoma of the Supraglottic Larynx

高雄榮民總醫院 臨床診療指引 Ver.1.2025 Page 2 (Ref. 3-7)

Amenable to larynx-preserving (conservation) surgery (Most T1-2, N0; Select T3)

Primary treatment

Endoscopic resection + neck dissection

Open partial supraglottic laryngectomy + neck dissection

Definite RT^{註1}

Pathological features

Adjuvant Treatment

Node negative (T1-2, N0)

Follow-up

Extranodal extension

CRT or RT (for select p'ts)^{註1,3}

Positive node, Positive margin

Re-resection, if feasible in highly selected patients or RT^{註1} or consider CRT^{註1,3}

One positive node, Adverse features*(-)

Consider RT^{註1}

Positive node, Other adverse features*(+)

RT or consider CRT^{註1,3}

Node negative (T3-4a, N0)

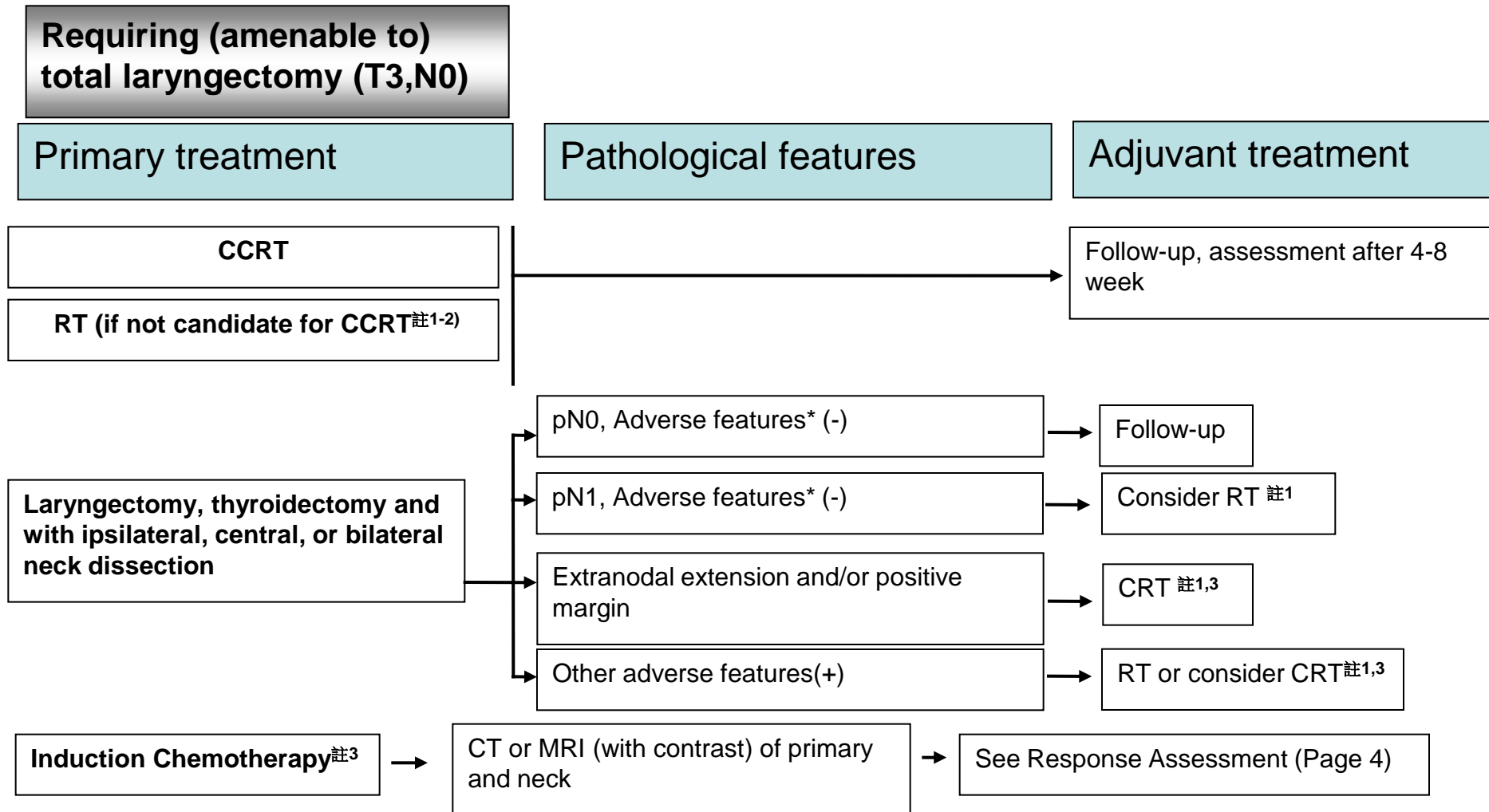
See Page 3,6,7,8

Follow-up

*Adverse features: extranodal extension, positive margins, close margins, pT3 or pT4 primary, pN2 or pN3 nodal disease, perineural invasion, vascular invasion, lymphatic invasion

Carcinoma of the Supraglottic Larynx

高雄榮民總醫院 臨床診療指引 Ver.1.2025 Page 3 (Ref. 8-12)

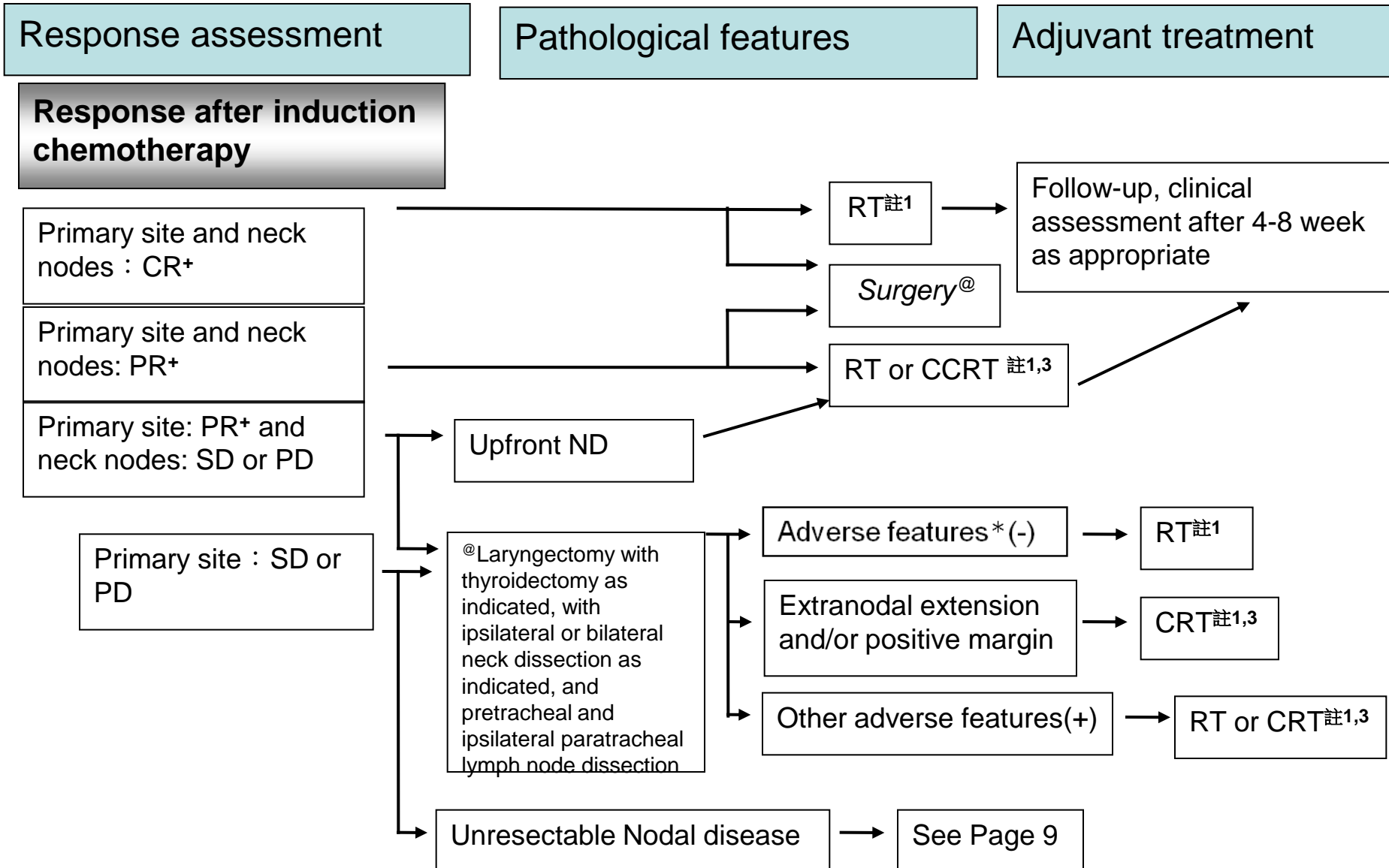


+ Primary site evaluated by CT or MRI(with contrast) of primary head and neck

* Adverse features : Extranodal extension, positive or close margins, pT3 or pT4 primary, N2 or N3 nodal disease, nodal disease in levels IV or V, perineural invasion, lymphovascular invasion

Carcinoma of the Supraglottic Larynx

高雄榮民總醫院 臨床診療指引 Ver.1.2025 Page 4 (Ref. 12-15)



+ Primary site evaluated by CT or MRI(with contrast) of primary head and neck

* Adverse features : extranodal extension, positive margins, close margins, pT4 primary, pN2 or pN3 nodal disease, perineural invasion, vascular invasion, lymphatic invasion

Carcinoma of the Supraglottic Larynx

高雄榮民總醫院 臨床診療指引 Ver.1.2025 Page 5

Node-positive disease

Clinical stage

Treatments

Amenable to larynx-preserving (conservation) surgery (T1-2, N+ and selected T3,N1)

See Page 6

Requiring (amenable to) total laryngectomy (Most T3, N1-3)

See Page 7

T4a, N1-3

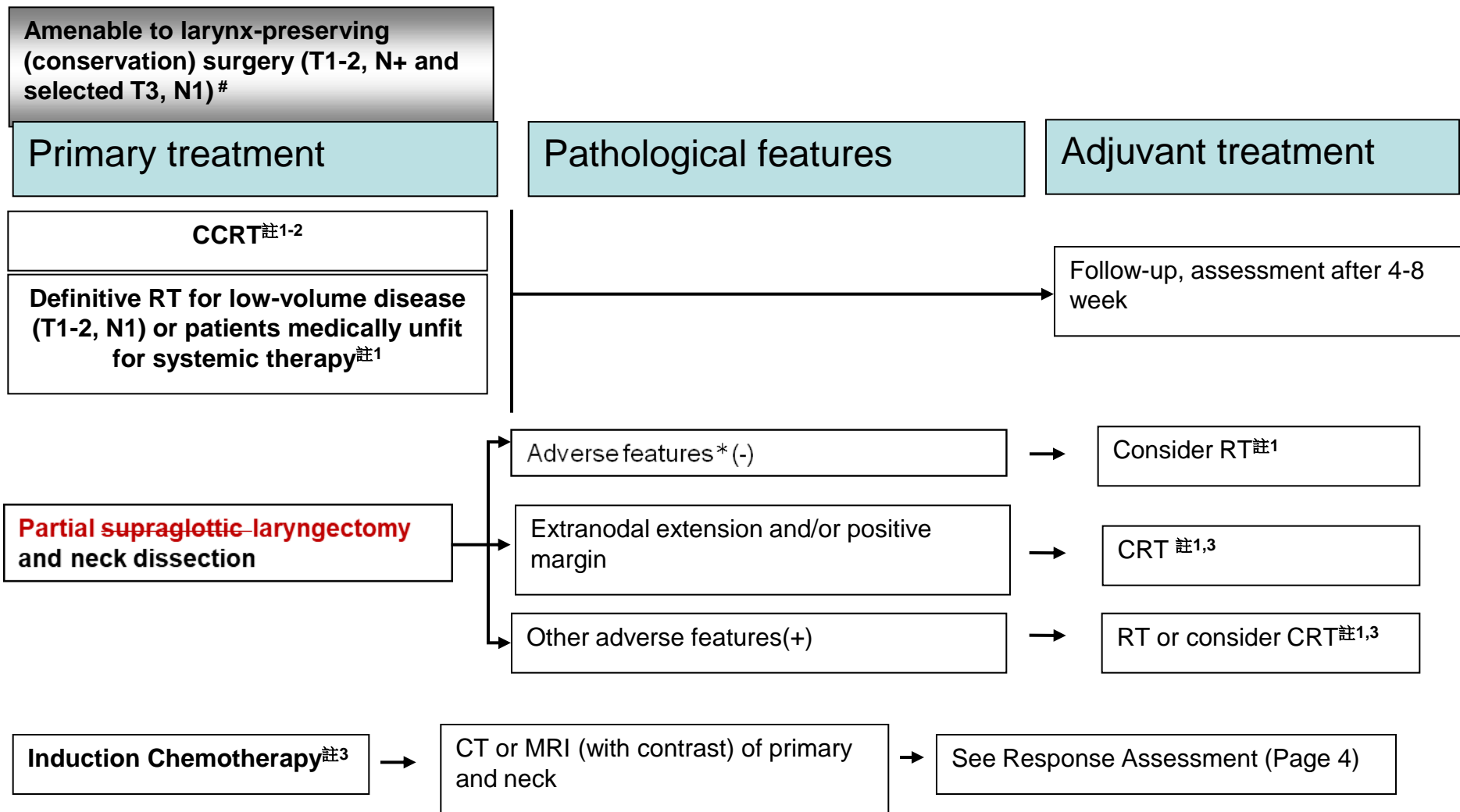
See Page 8

T4b, N1-3 or
Unresectable nodal disease or
Unfit for surgery

See Page 9

Carcinoma of the Supraglottic Larynx

高雄榮民總醫院 臨床診療指引 Ver.1.2025 Page 6 (Ref. 8-12)



+ Primary site evaluated by CT or MRI(with contrast) of primary head and neck

* Adverse features : Extranodal extension, positive or close margins, pT3 or pT4 primary, N2 or N3 nodal disease, nodal disease in levels IV or V, perineural invasion, lymphovascular invasion

Carcinoma of the Supraglottic Larynx

高雄榮民總醫院 臨床診療指引 Ver.1.2025 Page 7 (Ref. 8-12)

Requiring (amenable to) total laryngectomy (most T3, N1-3)

Primary treatment

Pathological features

Adjuvant treatment

Concurrent CRT^{註1,3}

Follow-up, assessment after 4-8 week

Laryngectomy with ipsilateral thyroidectomy, and neck dissection

Adverse features* (-)

RT^{註1}

Extranodal extension and/or positive margin

CRT^{註1,3}

Other adverse features(+)

RT or consider CRT^{註1,3}

Induction Chemotherapy^{註3}

CT or MRI (with contrast)^{註3} of primary and neck

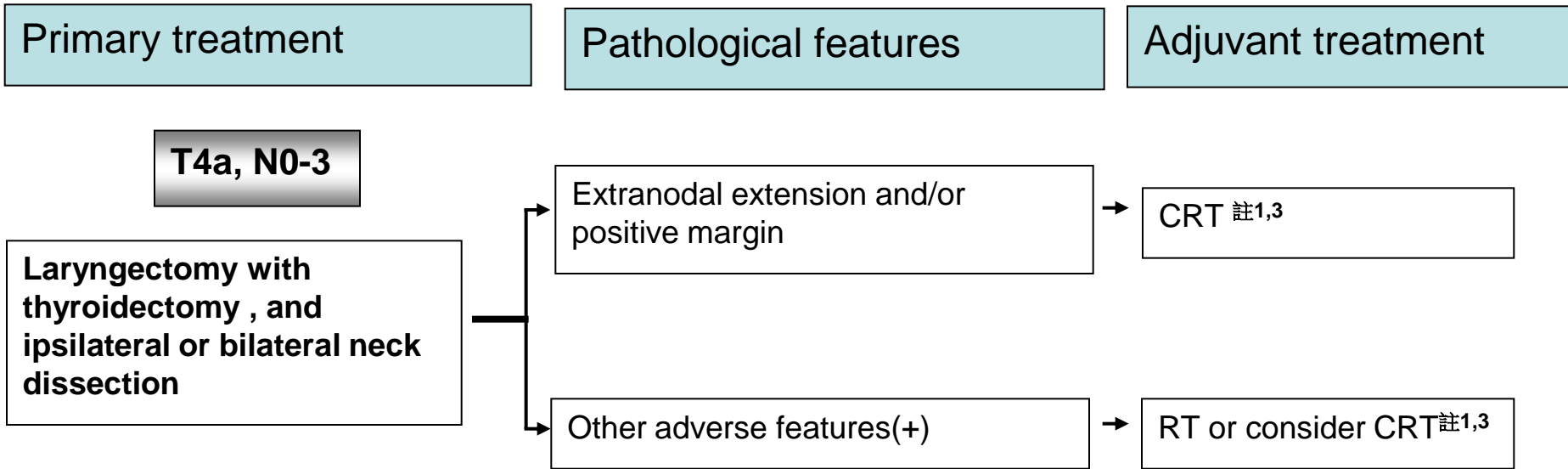
See Response Assessment (Page 4)

+ Primary site evaluated by CT or MRI(with contrast) of primary head and neck

* Adverse features : Extranodal extension, positive or close margins, pT3 or pT4 primary, N2 or N3 nodal disease, nodal disease in levels IV or V, perineural invasion, lymphovascular invasion

Carcinoma of the Supraglottic Larynx

高雄榮民總醫院 臨床診療指引 Ver.1.2025 Page 8 (Ref. 10-13)



T4a, N0-3

Laryngectomy with thyroidectomy, and ipsilateral or bilateral neck dissection

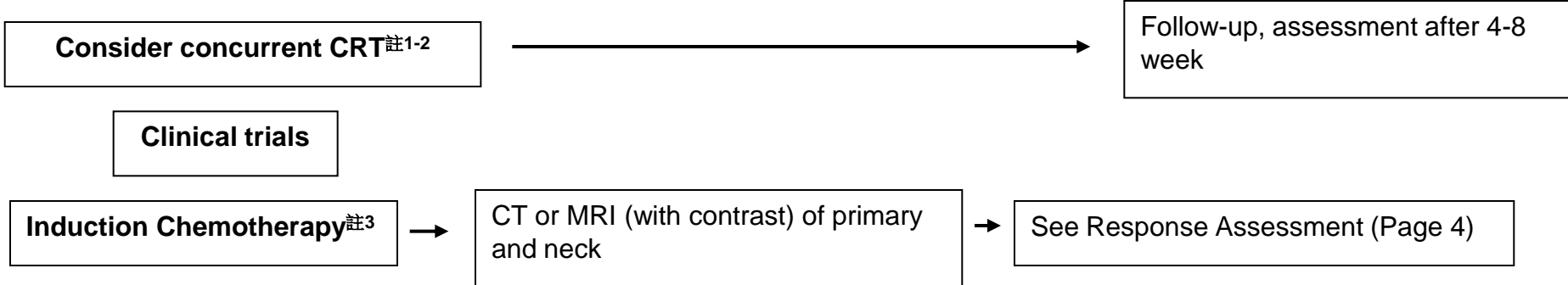
Extranodal extension and/or positive margin

CRT 註1,3

Other adverse features(+)

RT or consider CRT 註1,3

Select T4a patients (high PS, multiple comorbidity or decline surgery)



+ Primary site evaluated by CT or MRI(with contrast) of primary head and neck
* Adverse features : Extranodal extension, positive or close margins, pT3 or pT4 primary, N2 or N3 nodal disease, nodal disease in levels IV or V, perineural invasion, lymphovascular invasion

Carcinoma of the Supraglottic Larynx

高雄榮民總醫院 臨床診療指引 Ver.1.2025 Page 9 (Ref. 14-15)

Newly diagnosed (M0)T4b, N0-3;
Unresectable nodal disease;
Unfit for surgery

Treatment

Clinical trial preferred

PS 0-1 #

Concurrent CRT^{註1-2}

Induction C/T^{註3} as indicated followed by RT or CRT^{註1,3}

PS 2*

RT^{註1}

Concurrent CRT^{註1-2}

PS 3\$

Palliative RT^{註1}

Single-agent systemic therapy^{註4}

Best supportive care

ECOG Performance Status 0-1^{註6}

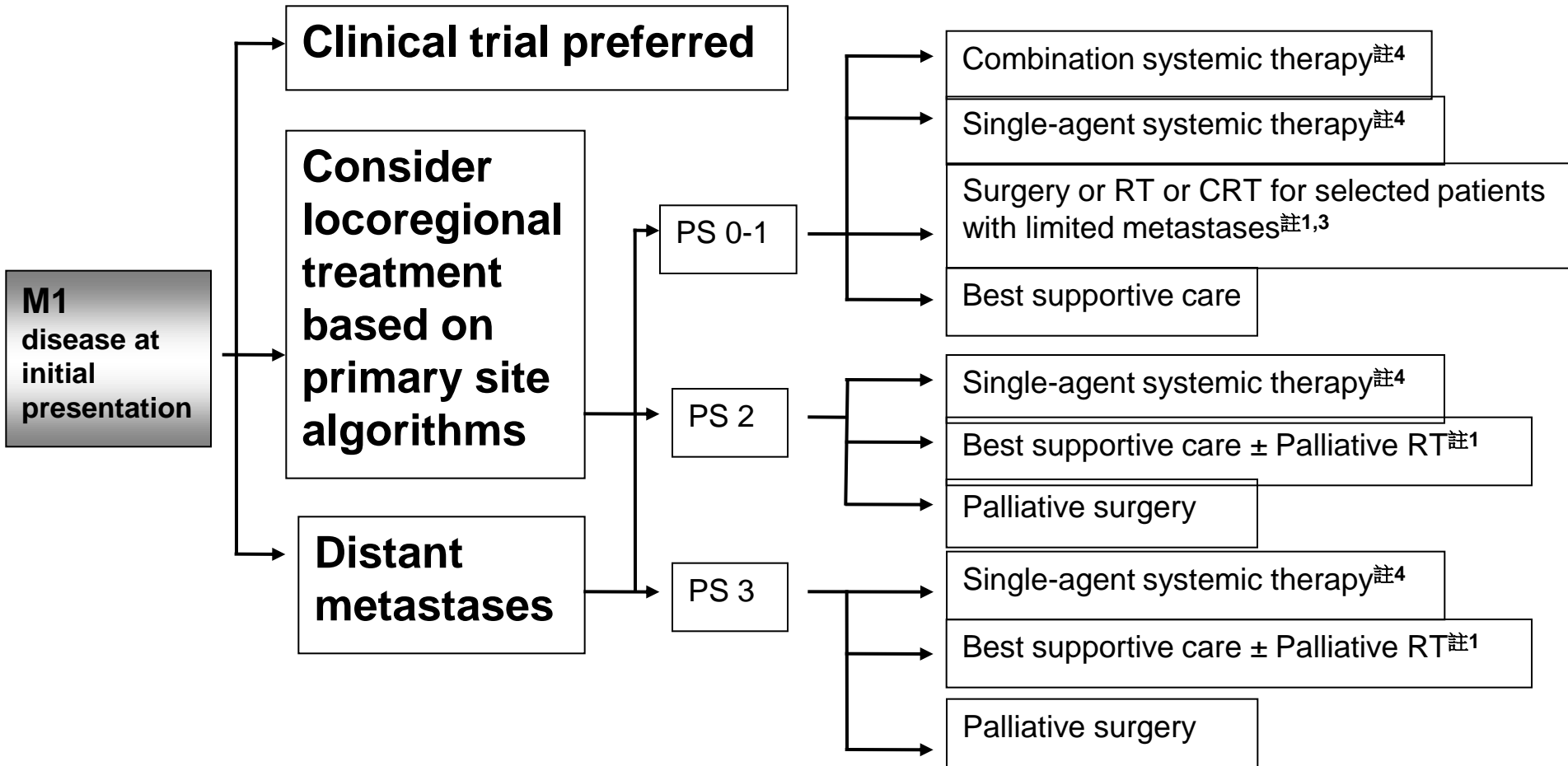
* ECOG Performance Status 2

\$ ECOG Performance Status 3

Carcinoma of the Supraglottic Larynx

高雄榮民總醫院 臨床診療 Ver.1.2025 Page 10 (Ref. 16-18)

Treatment



1. PS 0-1若治療無效，除 best supportive care 外可再考慮systemic therapy, clinical trial or palliative RT
2. PS 2 single agent systemic therapy 若治療無效，除 best supportive care 外可再考慮 alternate single agent systemic therapy or palliative RT
3. Recurrent or persistent disease with distant metastases病人建議做NGS genomic profiling

Carcinoma of the Supraglottic Larynx

註1 高雄榮民總醫院 臨床診療 Ver.1.2025 Page 11 (Ref. 19)

Principles of Radiotherapy

Definitive (RT alone)

- T1-3, N0-1 : 66 - 70 Gy conventional (2.0 Gy/fraction)
- PTV :

- ✓ **High risk** : Primary tumor and involved lymph nodes [this includes possible local subclinical infiltration at the primary site and at the high-risk level lymph node(s)]
 - Fractionation : 66 Gy (2.2 Gy/fraction) - 70 Gy (2.0 Gy/fraction) ; daily Monday-Friday in 6-7 weeks
 - Concomitant boost accelerated RT
 - ◆ 72 Gy /6 weeks (1.8 Gy/fraction, large field ; 1.5 Gy boost as second daily fraction during last 12 treatment days)
 - ◆ 66–70 Gy (2.0 Gy/fraction; 6 fractions/wk accelerated)
 - Hyperfractionation : 79.2 – 81.6 Gy /7 weeks (1.2 Gy/fraction, twice daily)
- ✓ **Low to intermittent risk** : Sites of suspected subclinical spread
 - 44 - 50 Gy (2.0 Gy/fraction) to 54 – 63 Gy (1.6-1.8 Gy/fraction)

Postoperative (RT or Concurrent CRT)

- Preferred interval between resection and postoperative RT is ≤6 weeks
- High risk: Adverse features such as positive margins
 - ✓ 60–66 Gy (2.0 Gy/fraction); daily Monday–Friday in 6–6.5 weeks
- Low to intermediate risk: sites of suspected subclinical spread
 - ✓ 44–50 Gy (2.0 Gy/fraction) to 54–63 Gy (1.6–1.8 Gy/fraction)

Concurrent CRT

- High-risk: typically 70 Gy (2.0 Gy/fraction)
- Low to intermediate risk: 44–50 Gy (2.0 Gy/fraction) to 54–63 Gy (1.6–1.8 Gy/fraction)

Either IMRT or 3D conformal RT is recommended. Use of proton therapy is an area of active investigation. Proton therapy may be considered when normal tissue constraints cannot be met by photon-based therapy.

Carcinoma of the Supraglottic Larynx

註2 高雄榮民總醫院 臨床診療 Ver.1.2025 Page 12 (Ref. 20-25)

Principles of Chemotherapy

Concurrent with RT

Regimen 1: q3w CDDP ± Cetuximab^{註5} + RT

- Cisplatin (80-100mg/ m²) q3w during R/T
- Cetuximab(400mg/ m²) loading dose first week, then Cetuximab(250mg/ m²) maintain dose D1 + Cisplatin (80-100mg/ m²) q3w D2 during R/T

Regimen 2: Weekly CDDP ± Cetuximab^{註5} + RT

- Cisplatin (30-40mg/ m²) weekly during R/T
- Cetuximab(400mg/ m²) loading dose first week, and then Cisplatin (30-40mg/ m²) weekly D1 + Cetuximab(250mg/ m²) maintain dose D2 during R/T

Regimen 3: q3w Carboplatin^{註5} ± Cetuximab^{註5} + RT

- Carboplatin (AUC x 5mg) q3w during R/T
- Cetuximab(400mg/ m²) loading dose first week, then Cetuximab(250mg/ m²) maintain dose D1 + Carboplatin (AUC x 5mg) q3w D2 during R/T

Regimen 4: Weekly Cetuximab^{註5} + RT

- Cetuximab(400mg/ m²) loading dose first week, then Cetuximab(250mg/ m²) maintain dose during RT

Regimen5 : Carboplatin + 5-FU + Hydroxyurea (CCr < 60) + RT

- Carboplatin (AUC x 1.25mg) D1-D4
- Fluorouracil (5-FU) (850mg/m²) D1-D4
- Hydroxyurea 1CAP BID D1-D5

Regimen6 : Cisplatin + 5-FU + Hydroxyurea + RT

- Cisplatin(20mg/ m²) D1-D4
- Fluorouracil (5-FU) (850mg/m²) D1-D4
- Hydroxyurea 1CAP BID D1-D5

Regimen 7: Doxetaxel + RT

- Doxetaxel (60g/m²) D1, if cisplatin not eligible

Carcinoma of the Supraglottic Larynx

註3 高雄榮民總醫院 臨床診療 Ver.1.2025 Page 13 (Ref. 20-25)

Regimens of Chemotherapy

Induction, adjuvant, 建議1-4 cycles

Regimen 1: q3-4 weeks T + P ± F (5-FU or UFUR) ± weekly Cetuximab^{註5}

- Taxotere(60 mg/ m²) D1
- Cisplatin(60-75 mg/ m²) D1
- Fluorouracil (5-FU) (600-750mg/m²) D2-D5 or **UFUR**
- Cetuximab (400mg/ m²) loading dose first week, then Cetuximab (250mg/ m²) maintain dose

Regimen 2: q3-4 weeks Platinum ± F (5-FU or UFUR) ± weekly Cetuximab^{註5}

- Cisplatin(80-100mg/ m²) D1 or Cisplatin (20mg/ m²) D1-D5 or Carboplatin (AUC x 5mg) D1
- Fluorouracil (5-FU) (600-1000mg/m²) D2-D5 or **UFUR**
- Cetuximab(400mg/m²) loading dose first week, then weekly Cetuximab (250mg/ m²)

Carcinoma of the Supraglottic Larynx

註3 高雄榮民總醫院 臨床診療Ver.1.2025 Page 14 (Ref. 20-25)

Regimens of Chemotherapy

Induction, adjuvant, 建議 1-4 cycles

Regimen 3: weekly Cetuximab^{註5}

- Cetuximab (400mg/ m²) loading dose first week, then Cetuximab (250mg/ m²) maintain dose

Regimen 4: oral Fluorouracil

- Ufur cap (tegafur 100mg+uracil 224mg) 2# BID-TID
(可作為取代iv-formed 5-FU之替代藥物)

Regimen 5: weekly Methotrexate

- Methotrexate (40-60mg/ m²)

Carcinoma of the Supraglottic Larynx

註4 高雄榮民總醫院 臨床診療Ver.1.2025 Page 15 (Ref. 20-25)

Regimens of Chemotherapy

Salvage or Metastasis

Regimen 1: q3 weeks Pembrolizumab ± Platinum ± F

- Pembrolizumab(200mg) D1 (if CPS \geq 1)
- Cisplatin(80-100mg/ m²) D1 or Cisplatin (20mg/ m²) D1-D5 or Carboplatin (AUC x 5mg) D1
- Fluorouracil (5-FU) (600-1000 mg/m²) D2-D5

Regimen 2: q2 weeks Nivolumab

- Nivolumab(3mg/kg) D1

Regimen 3: q3-4 weeks Platinum ± F ± weekly Cetuximab^{註5}

- Cisplatin(80-100mg/ m²) D1 or Cisplatin (20mg/ m²) D1-D5 or Carboplatin (AUC x 5mg) D1
- Fluorouracil (5-FU) (600-1000 mg/m²) D2-D5
- Cetuximab(400mg/ m²) loading dose first week, then weekly Cetuximab (250mg/m²)

Carcinoma of the Supraglottic Larynx

註4 高雄榮民總醫院 臨床診療Ver.1.2025 Page 16 (Ref. 20-25)

Regimens of Chemotherapy

Salvage or Metastasis

Regimen 4: q3-4 weeks T ± Platinum ± weekly Cetuximab^{註5}

- Taxotere(60 mg/ m²) D1
- Cisplatin(60-75 mg/ m²) D1 or Carboplatin (AUC x 5mg) D1
- Cetuximab(400mg/ m²) loading dose first week, then weekly Cetuximab (250mg/ m²)

Regimen 5: cisplatin+ epirubicin+ 5-FU+ Leucovorin

- Cisplatin (60 mg/ m²) D1
- Epirubicin (50 mg/ m²) D1
- Fluorouracil (5-FU) (2000 mg/m²) D1

Regimen 6: q2 weeks Bevacizumab

- Bevacizumab (200 mg/ m²) D1

Regimen 7: weekly Gemcitabine

- Gemcitabine (1000 mg/m²) D1

Regimen 8: q3 weeks Pembrolizumab^{註5} + Platinum + Doxetacel

- Pembrolizumab(200mg) D1
- Cisplatin(80-100mg/ m²) D1 or Cisplatin (20mg/ m²) D1-D5 or Carboplatin (AUC x 5mg) D1
- Taxotere(60 mg/ m²)

Carcinoma of the Supraglottic Larynx

註5

高雄榮民總醫院 臨床診療指引 Ver.1.2025 Page 17

特殊用藥健保給付規定

Taxotere

- 頭頸部癌，限局部晚期且無遠端轉移之頭頸部鱗狀細胞癌且無法手術切除者。
- 與Cisplatin 及5-FU 併用，作為放射治療前的引導治療，限使用四個療程。

Cetuximab

- 限與放射線療法合併使用於局部晚期之口咽癌、下咽癌及喉癌患者，使用總療程以接受8次輸注為上限。需經事前審查核准後使用。

符合下列條件之一：

1. 年齡 ≥ 70 歲
 2. $Ccr < 50ml/min$
 3. 聽力障礙者 (聽力障礙定義為500Hz、1000Hz、2000Hz 平均聽力損失大於25 分貝)
 4. 無法耐受platinum-based 化學治療。
- 限無法接受局部治療之復發及/或轉移性頭頸部鱗狀細胞癌，且未曾申報 cetuximab 之病患使用。需經事前審查核准後使用，使用總療程以18週為限，每9週申請一次，需無疾病惡化情形方得繼續使用。(106/4/1)

Carboplatin

- 限腎功能不佳 ($CCr < 60$) 或曾作單側或以上腎切除之惡性腫瘤患者使用。

Carcinoma of the Supraglottic Larynx

註5

高雄榮民總醫院 臨床診療指引 Ver.1.2025 Page 18

特殊用藥健保給付規定

Pembrolizumab、Nivolumab

• 先前已使用過 platinum 類化學治療失敗後，又有疾病惡化的復發或轉移性頭頸部鱗狀細胞癌成人患者。本類藥品與 cetuximab 僅能擇一使用，且治療失敗時不可互換。

• 符合下列條件：

1. 病人身體狀況良好(ECOG \leq 1)
2. NYHA (the New York Heart Association) Functional Class I 或 II
3. GOT < 60U/L 及 GPT < 60U/L，且 T-bilirubin < 1.5mg/dL；Creatinine < 1.5mg/dL，且 eGFR > 60mL/min/1.73m²
4. PD-L1 表現量 TPS \geq 50%

• 初次申請以 12 週為限，申請時需檢附以下資料：病理或細胞檢查報告、生物標記(PD-L1)表現量檢測報告、病人身體狀況良好(ECOG \leq 1) 及心肺與肝腎功能之評估資料、符合 i-RECIST 定義之影像檢查及報告(上述影像檢查之給付範圍不包括 PET)、先前已接受過之治療與完整用藥資料、使用免疫檢查點抑制劑之治療計畫(treatment protocol)。

• 用藥後每 12 週評估一次，以 i-RECIST 或 mRECIST 標準評定反應，依下列原則給付：

- I. 有療效反應者(PR 及 CR)得繼續使用；
- II. 出現疾病惡化(PD)或出現中、重度或危及生命之藥物不良反應時，應停止使用；
- III. 疾病呈穩定狀態者(SD)，可持續再用藥 4 週，並於 4 週後再次評估，經再次評估若為 PR、CR 者，得再繼續使用 12 週。若仍為 SD 或已 PD 者，應停止使用。

Carcinoma of the Supraglottic Larynx

註6

高雄榮民總醫院 臨床診療指引 Ver.1. 2025 Page 19

Eastern Cooperative Oncology Group (ECOG) Performance Status

Grade	Description	Suggestion
0	Normal activity fully ambulatory (無症狀)	按照標準化療評估及療程。
1	Symptoms, but nearly fully ambulatory (有症狀，完全步行，但對生活無影響)	按照標準化療評估及療程。
2	Some bed time, but needs to be in bed less than 50% of normal daytime (躺在床上的時間<50%)	按照標準化療評估及療程。
3	Needs to be in bed more than 50% of normal daytime (躺在床上的時間>50%)	可視情況考慮停止化學治療。
4	Unable to get out of bed (長期完全臥床)	建議停止化學治療。
5	Dead	

Carcinoma of the Supraglottic Larynx

高雄榮民總醫院 臨床診療指引 Ver.1 修訂於 2025.02.19 Page 20

References

1. NCCN Clinical Practice Guidelines in Oncology – Head and Neck Cancers Version 1. 2025
2. Kodaira T, Kagami Y, Machida R, et al. Long-term follow-up of a randomized controlled trial on accelerated radiation therapy versus standard fractionated radiation therapy for early glottic cancer (JCOG0701A3). *Int J Radiat Oncol Biol Phys* 2023;117:1118-1124
3. Hsieh MC, Wang CC, Yang CC, Lien CF, Wang CC, Shih YC, Yeh SA, Hwang TZ. Tegafur-Uracil versus 5-Fluorouracil in Combination with Cisplatin and Cetuximab in Elderly Patients with Recurrent or Metastatic Head and Neck Squamous Cell Carcinoma: A Propensity Score Matching Analysis. *Biology (Basel)*. 2021 Oct 8;10(10):1011. doi: 10.3390/biology10101011. PMID: 34681110; PMCID: PMC8533478.
4. AJCC (Amin M, Edge S, Greene F, et al. AJCC Cancer Staging Manual, 8th ed. New York: Springer; 2017
5. Rodell RM, Steiner W, Muller RM, et al. Endoscopic laser surgery of early glottic cancer: involvement of the anterior commissure. *Head Neck* 2009;31:583-592. Available at: <http://www.ncbi.nlm.nih.gov/pubmed/19132720>.
6. Zouhair A, Azria D, Coucke P, et al. Decreased local control following radiation therapy alone in early-stage glottic carcinoma with anterior commissure extension. *Strahlenther Onkol* 2004;180:84-90. Available at: <http://www.ncbi.nlm.nih.gov/pubmed/14762660>.
7. Silver CE, Beitler JJ, Shaha AR, et al. Current trends in initial management of laryngeal cancer: the declining use of open surgery. *Eur Arch Otorhinolaryngol* 2009;266:1333-1352. Available at: <http://www.ncbi.nlm.nih.gov/pubmed/19597837>.
8. Warner L, Chudasama J, Kelly CG, et al. Radiotherapy versus open surgery versus endolaryngeal surgery (with or without laser) for early laryngeal squamous cell cancer. *Cochrane Database Syst Rev* 2014:Cd002027. Available at: <https://www.ncbi.nlm.nih.gov/pubmed/25503538>.
9. Warner L, Lee K, Homer JJ. Transoral laser microsurgery versus radiotherapy for T2 glottic squamous cell carcinoma: a systematic review of local control outcomes. *Clin Otolaryngol* 2017;42:629-636. Available at: <https://www.ncbi.nlm.nih.gov/pubmed/27863075>.
10. Mo HL, Li J, Yang X, et al. Transoral laser microsurgery versus radiotherapy for T1 glottic carcinoma: a systematic review and metaanalysis. *Lasers Med Sci* 2017;32:461-467. Available at: <https://www.ncbi.nlm.nih.gov/pubmed/27966051>.
11. Yoo J, Lacchetti C, Hammond JA, Gilbert RW. Role of endolaryngeal surgery (with or without laser) versus radiotherapy in the management of early (T1) glottic cancer: a systematic review. *Head Neck* 2014;36:1807-1819. Available at: <https://www.ncbi.nlm.nih.gov/pubmed/24115131>.
12. Forastiere AA, Zhang Q, Weber RS, et al. Long-term results of RTOG 91-11: a comparison of three nonsurgical treatment strategies to preserve the larynx in patients with locally advanced larynx cancer. *J Clin Oncol* 2013;31:845-852. Available at: <http://www.ncbi.nlm.nih.gov/pubmed/23182993>.
13. Forastiere AA, Goepfert H, Maor M, et al. Concurrent chemotherapy and radiotherapy for organ preservation in advanced laryngeal cancer. *N Engl J Med* 2003;349:2091-2098. Available at: <http://www.ncbi.nlm.nih.gov/pubmed/14645636>.
14. Janoray G, Pointreau Y, Garaud P, et al. Long-term results of a multicenter randomized phase III trial of induction chemotherapy with cisplatin, 5-fluorouracil, +/- docetaxel for larynx preservation. *J Natl Cancer Inst* 2016;108. Available at: <https://www.ncbi.nlm.nih.gov/pubmed/26681800>.
15. Pointreau Y, Garaud P, Chapet S, et al. Randomized trial of induction chemotherapy with cisplatin and 5-fluorouracil with or without docetaxel for larynx preservation. *J Natl Cancer Inst* 2009;101:498-506. Available at: <http://www.ncbi.nlm.nih.gov/pubmed/19318632>.
16. Semrau S, Schmidt D, Lell M, et al. Results of chemoselection with short induction chemotherapy followed by chemoradiation or surgery in the treatment of functionally inoperable carcinomas of the pharynx and larynx. *Oral Oncol* 2013;49:454-460. Available at: <https://www.ncbi.nlm.nih.gov/pubmed/23321550>.

Carcinoma of the Supraglottic Larynx

高雄榮民總醫院 臨床診療指引 Ver.1 修訂於 2025.02.19 Page 21

References

17. Stokes WA, Jones BL, Bhatia S, et al. A comparison of overall survival for patients with T4 larynx cancer treated with surgical versus organ-preservation approaches: A National Cancer Data Base analysis. *Cancer* 2017;123:600-608. Available at: <https://www.ncbi.nlm.nih.gov/pubmed/27727461>.
18. Forastiere AA, Zhang Q, Weber RS, et al. Long-term results of RTOG 91-11: a comparison of three nonsurgical treatment strategies to preserve the larynx in patients with locally advanced larynx cancer. *J Clin Oncol* 2013;31:845-852. Available at: <http://www.ncbi.nlm.nih.gov/pubmed/23182993>.
19. Adelstein DJ, Li Y, Adams GL, et al. An intergroup phase III comparison of standard radiation therapy and two schedules of concurrent chemoradiotherapy in patients with unresectable squamous cell head and neck cancer. *J Clin Oncol* 2003;21:92-98. Available at: <http://www.ncbi.nlm.nih.gov/pubmed/12506176>.
20. Sun XS, Michel C, Babin E, et al. Approach to oligometastatic disease in head and neck cancer, on behalf of the GORTEC. *Future Oncol* 2018;14:877-889. Available at: <https://www.ncbi.nlm.nih.gov/pubmed/29578359>.
21. Bonomo P, Greto D, Desideri I, et al. Clinical outcome of stereotactic body radiotherapy for lung-only oligometastatic head and neck squamous cell carcinoma: Is the deferral of systemic therapy a potential goal? *Oral Oncol* 2019;93:1-7. Available at: <https://www.ncbi.nlm.nih.gov/pubmed/31109688>.
22. Bates JE, De Leo AN, Morris CG, et al. Oligometastatic squamous cell carcinoma of the head and neck treated with stereotactic body ablative radiotherapy: single-institution outcomes. *Head Neck* 2019;41:2309-2314. Available at: <https://www.ncbi.nlm.nih.gov/pubmed/30788878>.
23. Yamazaki H, Nishiyama K, Tanaka E, et al. Radiotherapy for early glottic carcinoma (T1N0M0): results of prospective randomized study of radiation fraction size and overall treatment time. *Int J Radiat Oncol Biol Phys* 2006;64:77-82. Available at: <http://www.ncbi.nlm.nih.gov/pubmed/16169681>.
24. Ang KK, Harris J, Wheeler R, et al. Human papillomavirus and survival of patients with oropharyngeal cancer. *N Engl J Med* 2010;363:24-35. Available at: <http://www.ncbi.nlm.nih.gov/pubmed/20530316>.
25. Fakhry C, Westra WH, Li S, et al. Improved survival of patients with human papillomavirus-positive head and neck squamous cell carcinoma in a prospective clinical trial. *J Natl Cancer Inst* 2008;100:261-269. Available at: <http://www.ncbi.nlm.nih.gov/pubmed/18270337>.
26. Rischin D, Young RJ, Fisher R, et al. Prognostic significance of p16INK4A and human papillomavirus in patients with oropharyngeal cancer treated on TROG 02.02 phase III trial. *J Clin Oncol* 2010;28:4142-4148. Available at: <http://www.ncbi.nlm.nih.gov/pubmed/20697079>.
27. Fakhry C, Zhang Q, Nguyen-Tan PF, et al. Human papillomavirus and overall survival after progression of oropharyngeal squamous cell carcinoma. *J Clin Oncol* 2014;32:3365-3373. Available at: <http://www.ncbi.nlm.nih.gov/pubmed/24958820>.
28. Posner MR, Lorch JH, Goloubeva O, et al. Survival and human papillomavirus in oropharynx cancer in TAX 324: a subset analysis from an international phase III trial. *Ann Oncol* 2011;22:1071-1077. Available at: <https://www.ncbi.nlm.nih.gov/pubmed/21317223>.
29. Sritippho T, Chotjumlong P, Iamaroon A. Roles of human papillomaviruses and p16 in oral cancer. *Asian Pac J Cancer Prev* 2015;16:6193-6200. Available at: <https://www.ncbi.nlm.nih.gov/pubmed/26434816>.