

高雄榮民總醫院

食道癌診療原則

癌症中心食道癌醫療團隊共同擬定

Reference: NCCN Clinical Practice Guidelines in Oncology™, Esophageal cancer, V.1.2015

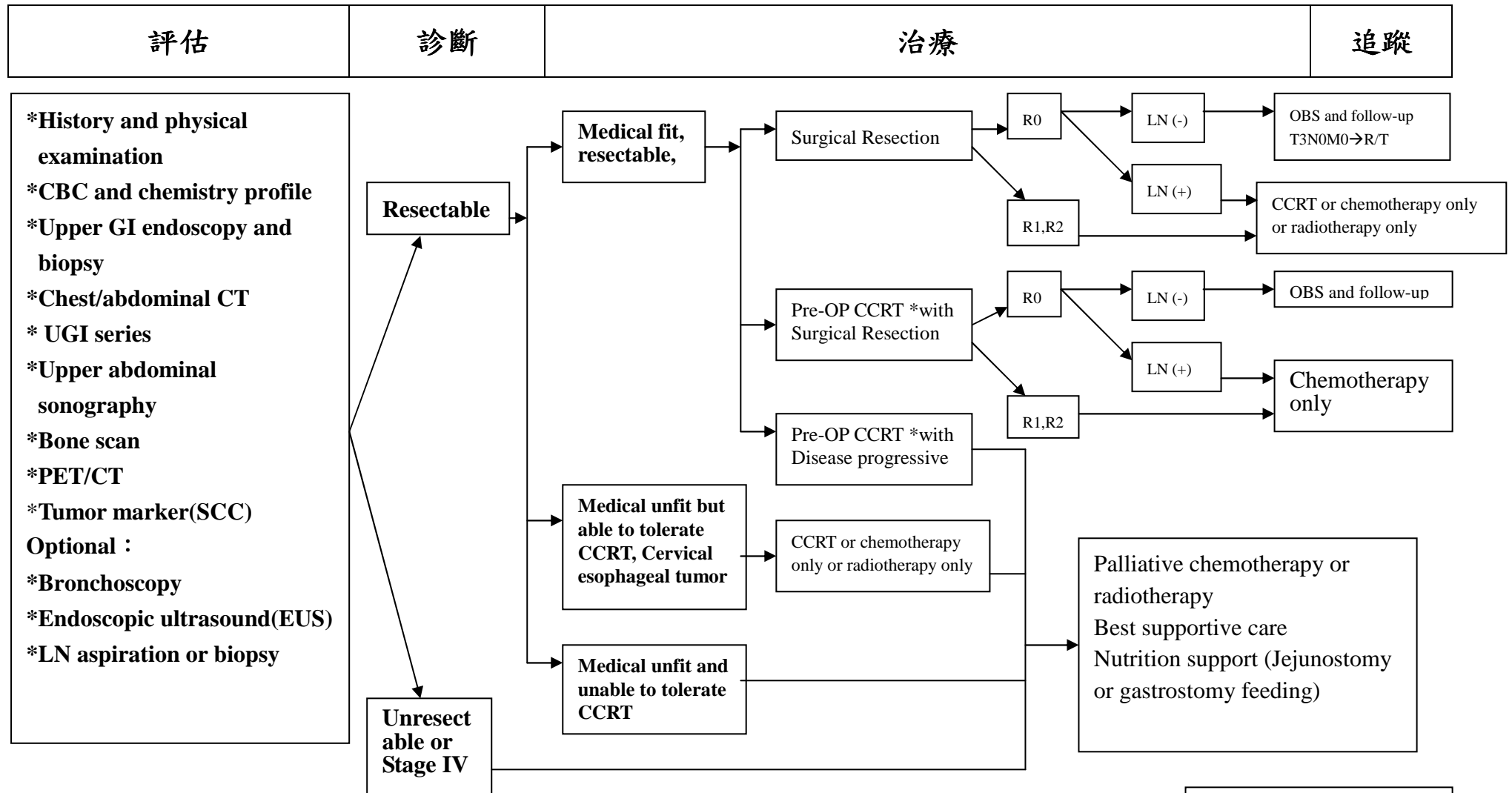
注意事項：這個診療準則主要作為醫師和其他保健專家診療癌症病人參考之用。假如你是一個癌症病人，直接引用這個研究資訊及診療準則並不恰當。只有你的醫師才能決定給你最恰當的治療。

Summary of the Guidelines Updates (與上一版差異)

2015/1/13 審視後將診斷 Medical fit, resectable 個案後續治療方向區分成 Surgical Resection、Pre-OP CCRT with Surgical Resection、Pre-OP CCRT with Disease progressive 3 個方向進行。

食道癌 (總表)

高雄榮民總醫院
臨床診療指引 2015.01. 第一版



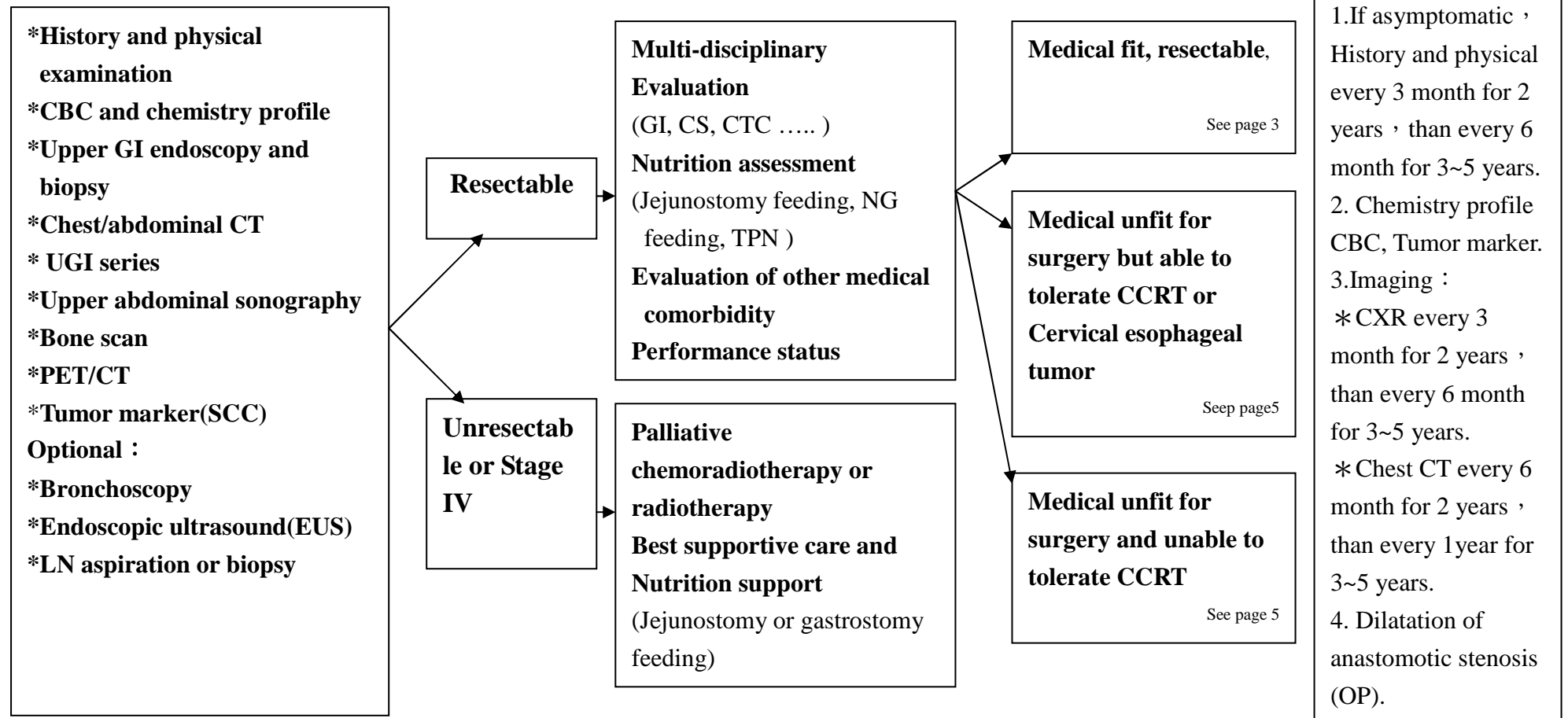
* Criteria : T3-4 or N+

食道癌

高雄榮民總醫院

臨床診療指引 2015. 01. 第一版

評估	診斷	治療	追蹤
----	----	----	----

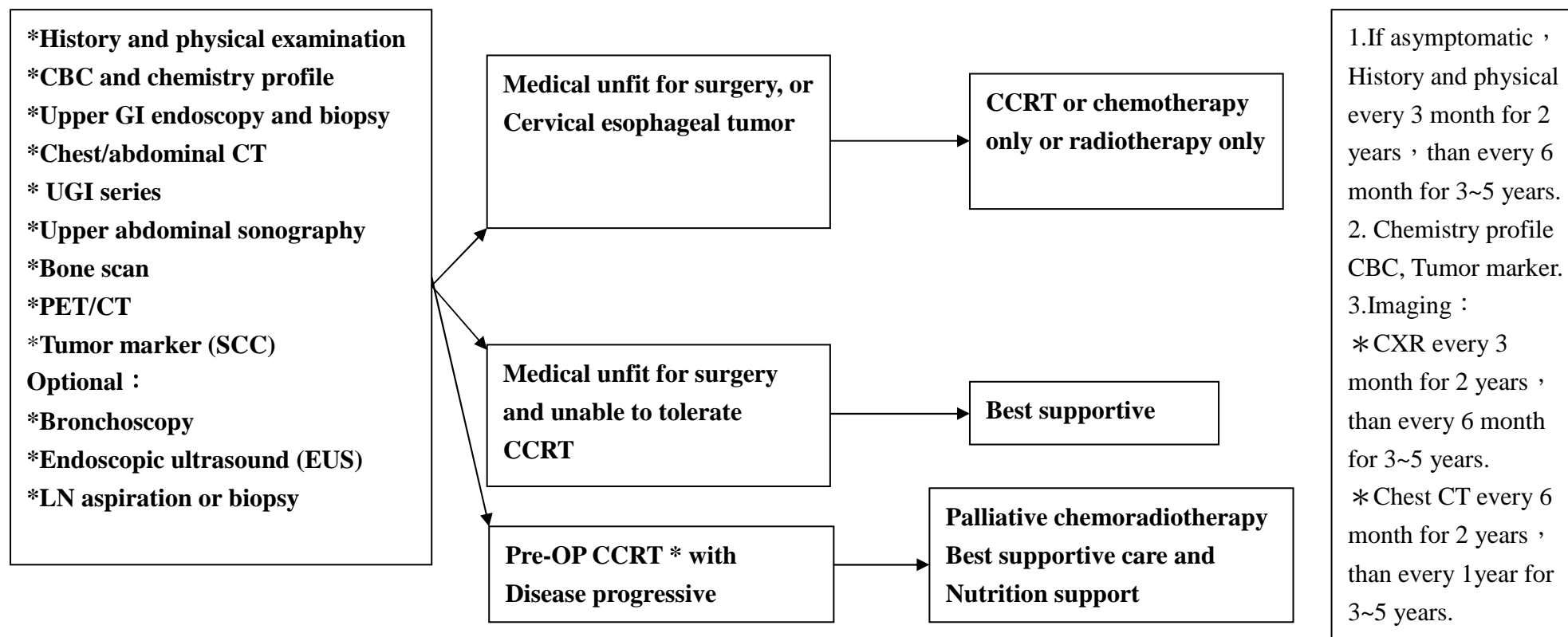


食道癌

高雄榮民總醫院

臨床診療指引 2015. 01. 第一版

評估	診斷	治療	追蹤
----	----	----	----

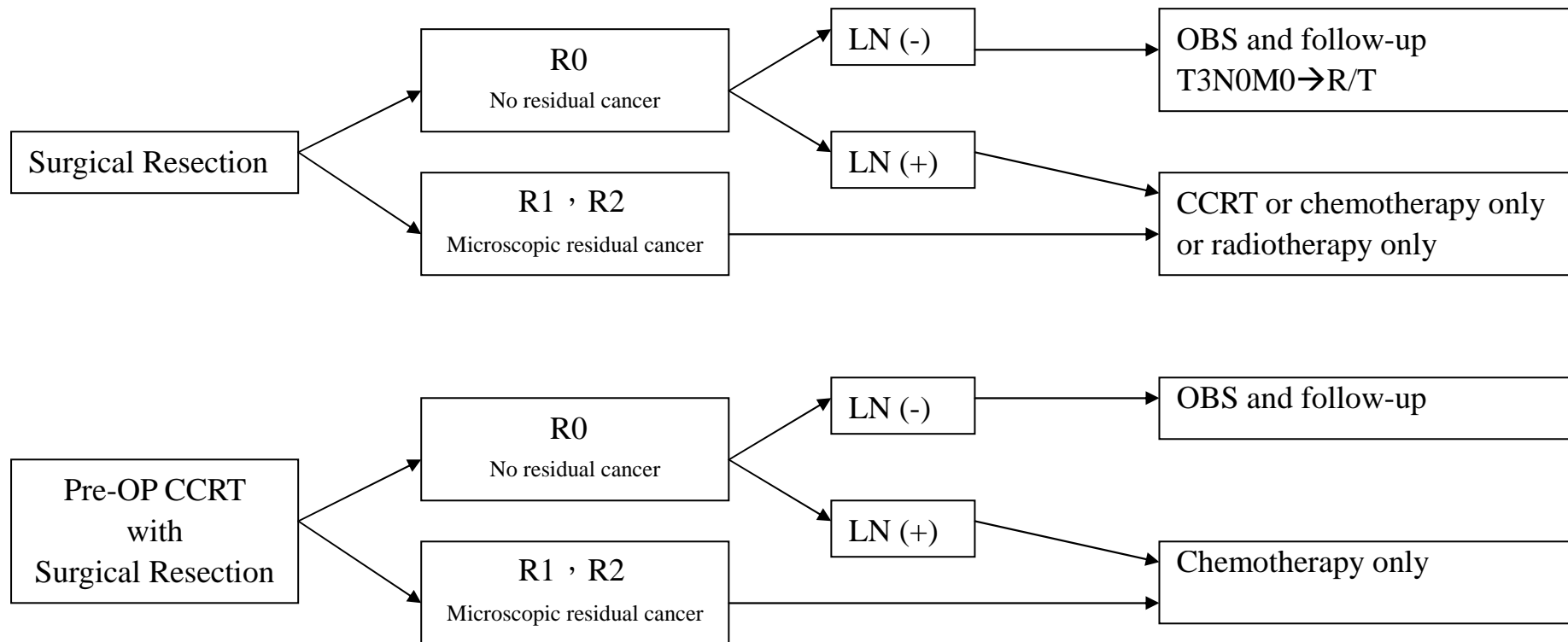


食道癌

高雄榮民總醫院

臨床診療指引 2015. 01. 第一版

Surgical outcomes after esophagectomy/ Clinical pathologic findings	Tumor classification	Postoperative treatment
--	----------------------	-------------------------



食道癌

高雄榮民總醫院

臨床診療指引 2015. 01. 第一版

Follow-up

Recurrence

Palliative therapy

1.If asymptomatic , History and physical every 3 month for 2 years , than every 6 month for 3~5 years.
2. Chemistry profile CBC, Tumor marker.
3.Imaging :
* CXR every 3 month for 2 years , than every 6 month for 3~5 years.
* Chest CT every 6 month for 2 years , than every 1year for 3~5 years.

Local or regional recurrence
Prior surgery
No CCRT

Local or regional recurrence
Prior CCRT
No surgery

Distant metastases

CCRT and/or
best supportive care

Resectable and
medical fit

Unresectable or
medical unfit

Palliative
surgery

Recurrence

Chemotherapy and/or best
supportive care

食道癌

高雄榮民總醫院

臨床診療指引 2015. 01. 第一版

化學治療處方

Published C/T regimens	Schedule	
Cisplatin 60-75mg/m ² , IV ,D1/ Carboplatin AUC 4-6 mg, IV ,D1 (Ccr <60) Fluorouracil, 600-1000 mg/m ² , IV ,D1-4 (Reference No.22)	Q28 D x 4-6 cycles	Performance status (ECOG) ≤ 2 or Kamofsky Performance score ≥ 60
Cisplatin 60-75 mg/m ² , IV ,D1/ Carboplatin AUC 4-6 mg, IV ,D1 (Ccr <60) Etoposide 60-100 mg/m ² , IV ,D1-3 (Reference No.23)	Q21 D x 4-6 cycles	Performance status (ECOG) ≤ 2 or Kamofsky Performance score ≥ 60
Taxol 140-175 mg/m ² , IV ,D1 Cisplatin 20 mg/m ² , IV ,D1-5/ Carboplatin AUC 1mg, IV ,D1-5 (Ccr <60) Fluorouracil,600-750 mg/m ² , IV ,D1-5 (Reference No.24)	Q14D x 4-6 cycles	Performance status (ECOG) ≤ 2 or Kamofsky Performance score ≥ 60
Cisplatin 60 mg/m ² , IV ,D1/ Carboplatin AUC 4-6 mg, IV ,D1 (Ccr <60) Xeloda 2.5TAB/ m ² , PO,D1-14 (Reference No.27)	Q21 D x 4-6 cycles	Performance status (ECOG) ≤ 2 or Kamofsky Performance score ≥ 60
Ufur 3CAP/m ² , PO,D1-14	Q28D x6 cycles	Performance status (ECOG) ≤ 2 or Kamofsky Performance score ≥ 60
Mitomycin 5- 7 mg/m ² , IV ,D1 Cisplatin 50-60 mg/m ² , IV ,D1/ Carboplatin AUC 4-6 mg, IV ,D1 (Ccr <60) Fluorouracil,480~600 mg/m ² , IV ,D1 (Reference No.28)	MitomycinQ42D Cisplatin Q21D 5-FU QD MCF x 4-6 cycles	Performance status (ECOG) ≤ 2 or Kamofsky Performance score ≥ 60

<p>Mitomycin 5- 7 mg/m², IV ,D1 Cisplatin 45-60 mg/m², IV ,D1/ Carboplatin AUC 4-6 mg, IV ,D1 (Ccr <60) Ufur 3CAP/m², PO,D1-14</p> <p>(Reference No.28)</p>	<p>MitomycinQ42D Cisplatin Q21D Ufur QD MCU x 4-6 cycles</p>	<p>Performance status (ECOG) ≤ 2 or Kamofsky Performance score ≥ 60</p>
<p>Tarceva 150mg 1TAB, PO</p> <p>(Reference No.29)</p>	<p>QD (to disease progression)</p>	<p>Performance status (ECOG) ≤ 2 or Kamofsky Performance score ≥ 60</p>

食道癌

高雄榮民總醫院
臨床診療指引 2015.01. 第一版

Radiotherapy (Reference No.15-21)

Dose prescription

Combination with operation (Pre-operative or post operative RT)	1.8-2 Gy, total 45-50.4 Gy, 25-28 fraction
Concurrent CCRT without operation	1.8-2 Gy, total 50.4-59.4 Gy, 28-33 fractions
RT alone	1.8-2 Gy, total 54-64 Gy, 27-35 fractions

When the radiation dosage reach 45 Gy , the stomach area should be blocked.

Field design

Preoperative RT or CCRT :

GTV = primary lesion and involved LN; CTV = GTV + subclinical disease (regional LN and submucosal), 4 cm proximal/distal and 1 cm radial;
PTV = CTV + 1 - 2 cm.

Tumors above the carina: treat SCV and mediastinal LN.

Tumors at or below the carina: treat mediastinal LN, and include celiac LN for lower 1/3 and gastroesophageal junction tumors.

Postoperative RT : depended by operative findings and pathological report.

Dose limitation :

Spinal cord : $D_{max} \leq 46$ Gy at 1.8-2 Gy/fraction

Lung : V_{20} (volume receiving ≥ 20 Gy) < 35% .

Heart : V_{40} < 50% .

Reference :

1. NCCN Clinical Practice Guidelines in Oncology™, Esophageal cancer , V.2.2013.
2. Steyerberg EW, Neville BA, Kopper LB, Lemmens VE, et al. Surgical mortality in patients with esophageal cancer: development and validation of a simple risk score. *J Clin Oncol* 2006;24 (26):4277-4284.
3. Fujita H, Sueyoshi S, Yamana H, Shinozaki K et al., Optimum treatment strategy for superficial esophageal cancer: Endoscopic mucosal resection versus radical esophagectomy. *World Journal of Surgery*; 2001; 25: 424-431.
4. Ell C, May A, Gossner L, Pech O, et al., Endoscopic mucosal resection of early cancer and high-grade dysplasia in Barrett's esophagus. *Gastroenterology* 2000; 118: 670-677.
5. Conio M, Repici A, Cestari R, Blanchi S, et al., Endoscopic mucosal resection for high-grade dysplasia and intramucosal carcinoma in Barrett's esophagus: An Italian experience. *World Journal of Gastroenterology* 2005; 11(42): 6650-6655.
6. Larghi A, Lightdale CJ, Ross AS, Fedi P, et al., Long-term follow-up of complete Barrett's eradication endoscopic mucosal resection (CBE-EMR) for the treatment of high-grade dysplasia and intramucosal carcinoma. *Endoscopy* 2007;39: 1086-1091.
7. Lopes CV, Hela M, Pesenti C, Bories E, et al., Circumferential endoscopic resection of Barrett's esophagus with high-grade dysplasia or early adenocarcinoma. *Surgical Endoscopy* 2007; 21: 820-824.
8. Overholt BF, Wang KK, Burdick S, Lightdale CJ, et al., Five-year efficacy and safety of photodynamic therapy with Photofrin in Barrett's high-grade dysplasia. *Gastrointestinal Endoscopy* 2007; 66(3): 460-468.
9. de Hoyos A, Litle VR, and Luketich JD. Minimally invasive esophagectomy. *Surg Clin North Am* 2005;85 (3): 631-647.
10. Hofstetter WL. Lymph Node Dissection in Esophageal Cancer. *Current Therapies in Thoracic and Cardiovascular Surgery*, edited by SC Yang and DE Cameron. Mosby, Inc., Philadelphia, Pennsylvania, pp. 360-363, 2004.
11. Swisher SG, Wynn P, Putnam JB, Mosheim MB, et al. Salvage esophagectomy for recurrent tumors after definitive chemotherapy and radiotherapy. *J Thorac Cardiovasc Surg* 2002;123:175-183.
12. Birkmeyer JD, Siewers AE, Finlayson EVA, Stukel TA, et al. Hospital volume and surgical mortality in the United States. *N Engl J Med* 2002;346(15):1128-1137.
13. Hulscher JBF, van Sandick JW, de Boer AG, et al. Extended transthoracic resection compared with limited transhiatal resection for adenocarcinoma of the esophagus. *N Engl J Med*, 2002;347(21):1662-1669
14. AJCC 7th edition

Reference for Radiotherapy :

15. Herskovic A; Martz K; al-Sarraf M et al.: Combined chemotherapy and radiotherapy compared with radiotherapy alone in patients with cancer of the esophagus. *N Engl J Med* 1992;326(24):1593-8.
16. Al-Sarraf M; Martz K; Herskovic A et al.: Progress report of combined chemoradiotherapy versus radiotherapy alone in patients with esophageal cancer: an intergroup study. *J Clin Oncol* 1997;15(1):277-84.
17. Cooper JS; Guo MD; Herskovic A et al.: Chemoradiotherapy of locally advanced esophageal cancer: long-term follow-up of a prospective randomized trial (RTOG 85-01). Radiation Therapy Oncology Group. *JAMA* 1999;281(17):1623-7.
18. Minsky BD; Pajak TF; Ginsberg RJ et al.: INT 0123 (Radiation Therapy Oncology Group 94-05) phase III trial of combined-modality therapy for esophageal cancer: high-dose versus standard-dose radiation therapy. *J Clin Oncol* 2002;20(5):1167-74.
19. Shioyama Y; Nakamura K; Sasaki T et al.: Clinical results of radiation therapy for stage I esophageal cancer: a single institutional experience. *Am J Clin Oncol* 2005;28(1):75-80.
20. Chen J; Zhu J; Pan J et al: Postoperative radiotherapy improved survival of poor prognostic squamous cell carcinoma esophagus. *Ann thorac surg* 2010;90(2):435-42
21. Chen J; Pan J; Zheng X et al: Number and location of positive nodes, postoperative radiotherapy and survival after esophagectomy with three field lymph node dissection for thoracic esophageal squamous cell carcinoma. *Int. J. Radiation Oncology Biol. Phys.* 2012; 82 (1):475–82

Reference for Chemotherapy :

22. Phase III Trial of Trimodality Therapy With Cisplatin, Fluorouracil, Radiotherapy, and Surgery Compared With Surgery Alone for Esophageal Cancer: CALGB 9781. *J Clin Oncol* 26:1086-1092.
23. Chemotherapy with cisplatin or carboplatin in combination with etoposide for small-cell esophageal cancer: a systemic analysis of case series. *Diseases of the Esophagus* 9 OCT 2013, DOI: 10.1111/dote.12149.
24. Phase II trial of paclitaxel, fluorouracil, and cisplatin in patients with advanced carcinoma of the esophagus. *JCO* 1998, 16(5),p 1826-1834.
25. Phase III Study of Docetaxel and Cisplatin Plus Fluorouracil Compared With Cisplatin and Fluorouracil As First-Line Therapy for Advanced Gastric Cancer: A Report of the V325 Study Group. *J Clin Oncol* 24:4991-4997.
26. Perioperative Chemotherapy versus Surgery Alone for Resectable Gastroesophageal Cancer. *N Engl J Med* 2006; 355:11-20.
27. Definitive Chemoradiotherapy with Capecitabine and Cisplatin in Patients with Esophageal Cancer: A Pilot Study. *J Korean Med Sci* 2009; 24:

120-5.

28. Prospective Randomized Trial Comparing Mitomycin, Cisplatin, and Protracted Venous-Infusion Fluorouracil (PVI 5-FU) With Epirubicin, Cisplatin, and PVI 5-FU in Advanced Esophagogastric Cancer. *J Clin Oncol* 20:1996-2004.
29. A Phase 2 Trial of Erlotinib in Patients With Previously Treated Squamous Cell and Adenocarcinoma of the Esophagus. *Cancer* 2011;117:1409–14.

附件：

DEFINITIONS OF TNM	
Primary Tumor (T)	
TX	Primary tumor cannot be assessed
T0	No evidence of primary tumor
Tis	High-grade dysplasia
T1	Tumor invades lamina propria, muscularis mucosae, or submucosa
T1a	Tumor invades lamina propria or muscularis mucosae
T1b	Tumor invades submucosa
T2	Tumor invades muscularis propria
T3	Tumor invades adventitia
T4	Tumor invades adjacent structures
T4a	Resectable tumor invading pleura, perivardium, or diaphragm
T4b	Unresectable tumor invading other adjacent structures, such as aorta, vertebral body, trachea, etc.
Regional Lymph Nodes (N)	
NX	Regional lymph nodes cannot be assessed
N0	No regional lymph node metastasis
N1	Metastasis in 1-2 regional lymph nodes
N2	Metastasis in 3-6 regional lymph nodes
N3	Metastasis in seven or more regional lymph nodes
Distant Metastasis (M)	
M0	No distant metastasis
M1	Distant metastasis

ANATOMIC STAGE/PROGNOSTIC GROUPS					
Squamous Cell Carcinoma (Figure 10.6)					
Stage	T	N	M	Grade	Tumor Location
0	Tis (HGD)	N0	M0	1, X	Any
IA	T1	N0	M0	1, X	Any
IB	T1	N0	M0	2-3	Any
	T2-3	N0	M0	1, X	Lower, X
IIA	T2-3	N0	M0	1, X	Upper, middle
	T2-3	N0	M0	2-3	Lower, X
IIB	T2-3	N0	M0	2-3	Upper, middle
	T1-2	N1	M0	Any	Any
IIIA	T1-2	N2	M0	Any	Any
	T3	N1	M0	Any	Any
	T4a	N0	M0	Any	Any
IIB	T3	N2	M0	Any	Any
IIIC	T4a	N1-2	M0	Any	Any
	T4b	Any	M0	Any	Any
	Any	N3	M0	Any	Any
IV	Any	Any	M1	Any	Any

Or mixed histology including a squamous component or NOS.

Location of the primary cancer site is defined by the position of the upper (proximal) edge of the tumor in the esophagus.

Adenocarcinoma (Figure 10.7)

Stage	T	N	M	Grade
0	Tis (HGD)	N0	M0	1,X
IA	T1	N0	M0	1-2, X
IB	T1	N0	M0	3
	T2	N0	M0	1-2, X
IIA	T2	N0	M0	3
IIB	T3	N0	M0	Any
	T1-2	N1	M0	Any
IIIA	T1-2	N2	M0	Any
	T3	N1	M0	Any
	T4a	N0	M0	Any
IIB	T3	N2	M0	Any
IIIC	T4a	N1-2	M0	Any
	T4b	Any	M0	Any
	Any	N3	M0	Any
IV	Any	Any	M1	Any

T	<p>Tis high-grade dysplasia</p> <p>T1 lamina propria, muscularis mucosae, or submucosa</p> <p>T1a lamina propria or muscularis mucosae</p> <p>T1b submucosa</p> <p>T2 muscularis propria</p> <p>T3 adeventitia</p> <p>T4 adjacent structures</p> <p>T4a resectable tumor invading pleura, pericardium, or diaphragm</p> <p>T4b unresectable tumor invading other adjacent structures, such as aorta, vertebral body, trachea, etc.</p>
N	<p>N0 0 No regional lymph node metastasis</p> <p>N1 1-2 positive regional lymph nodes</p> <p>N2 3-6 positive regional lymph nodes</p> <p>N3 ≥ 7 positive regional lymph nodes</p>
M	<p>M0 no distant metastasis</p> <p>M1 distant metastasis</p>
Cell type	Squamous cell carcinoma ; Adenocarcinoma
Grade of histology	<p>G1 well differentiated</p> <p>G2 moderately differentiated</p> <p>G3 poorly differentiated</p> <p>G4 Undifferentiated</p>
Location of cancer	<p>Proximal tumor margin (for squamous cell carcinoma only)</p> <p>Upper thoracic 15~24 cm</p> <p>Middle thoracic 24~32 cm</p> <p>Lower thoracic 32~40 cm</p> <p>Esophago-gastric junction : epicenter in esophagus, e-g junction, or within proximal 5 cm of the stomach</p>

Staging of esophageal carcinoma(AJCC 7th)

Stage grouping: Squamous cell carcinoma(AJCC 7th)

Stage	T	N	M	G	Location
0	is	0	0	1	Any
IA	1	0	0	1	Any
IB	1	0	0	2-3	Any
	2-3	0	0	1	Lower
IIA	2-3	0	0	1	U / M
	2-3	0	0	2-3	Lower
IIB	2-3	0	0	2-3	U / M
	1-2	1	0	Any	Any
IIIA	1-2	2	0	Any	Any
	3	1	0	Any	Any
	4a	0	0	Any	Any
IIB	3	2	0	Any	Any
IIC	4a	1-2	0	Any	Any
	4b	Any	0	Any	Any
	Any	3	0	Any	Any
IV	Any	any	1	Any	Any

Stage of grouping: Adenocarcinoma(AJCC 7th)

Stage	T	N	M	G
0	is	0	0	1
IA	1	0	0	1-2
IB	1	0	0	3
	2	0	0	1-2
IIA	2	0	0	3
IIB	3	0	0	Any
	1-2	1	0	Any
IIIA	1-2	2	0	Any
	3	1	0	Any
	4a	0	0	Any
IIIB	3	2	0	Any
IIIC	4a	1-2	0	Any
	4b	Any	0	Any
	Any	3	0	Any
IV	Any	Any	1	Any