

# 高雄榮民總醫院

## 膀胱癌診療原則

2018年05月22日 第一版

泌尿道癌醫療團隊擬訂

注意事項：這個診療原則主要作為醫師和其他保健專家診療癌症病人參考之用。假如你是一個癌症病人，直接引用這個診療原則並不恰當，只有你的醫師才能決定給你最恰當的治療。

# 會議討論

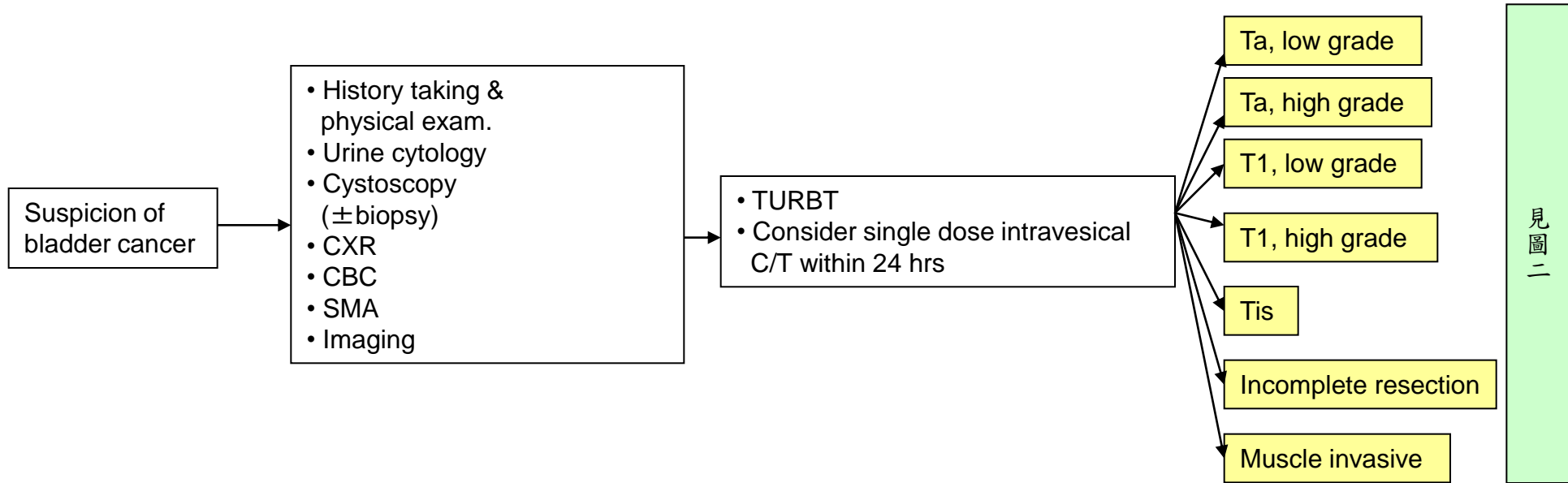
上次會議：2017/05/09

本共識與上一版的差異

上一版	新版
1.無免疫治療.	1.新增用於新輔助及第四期或化療無效可使用免疫治療選項. 2.新增參考文獻NO7-9.

# 膀胱癌(圖一)

臨床表徵	初期評估	診斷、治療	分期
------	------	-------	----

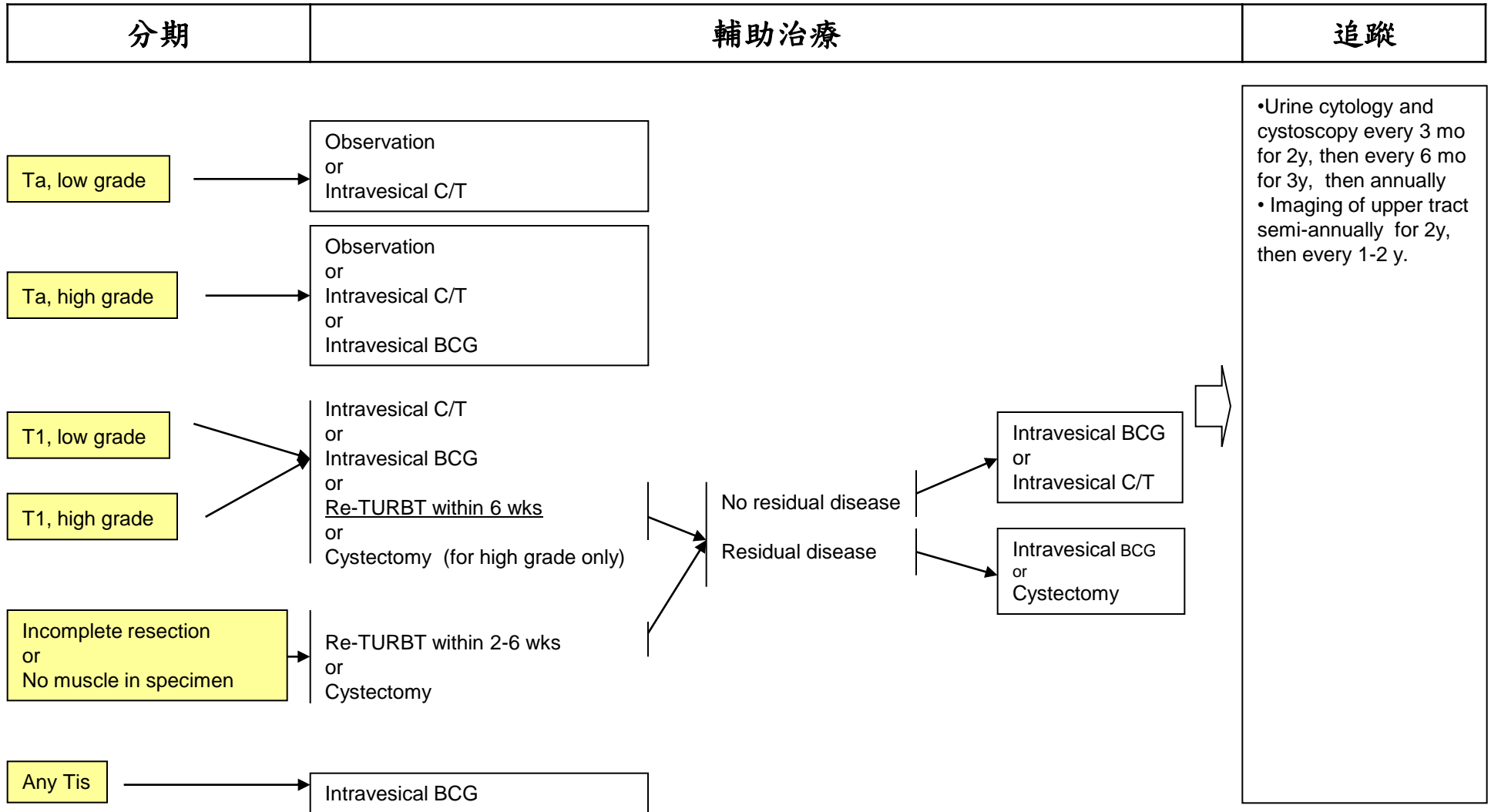


\* Imaging of upper tract may include IVP, ultrasonography, CT urography or MR urography.

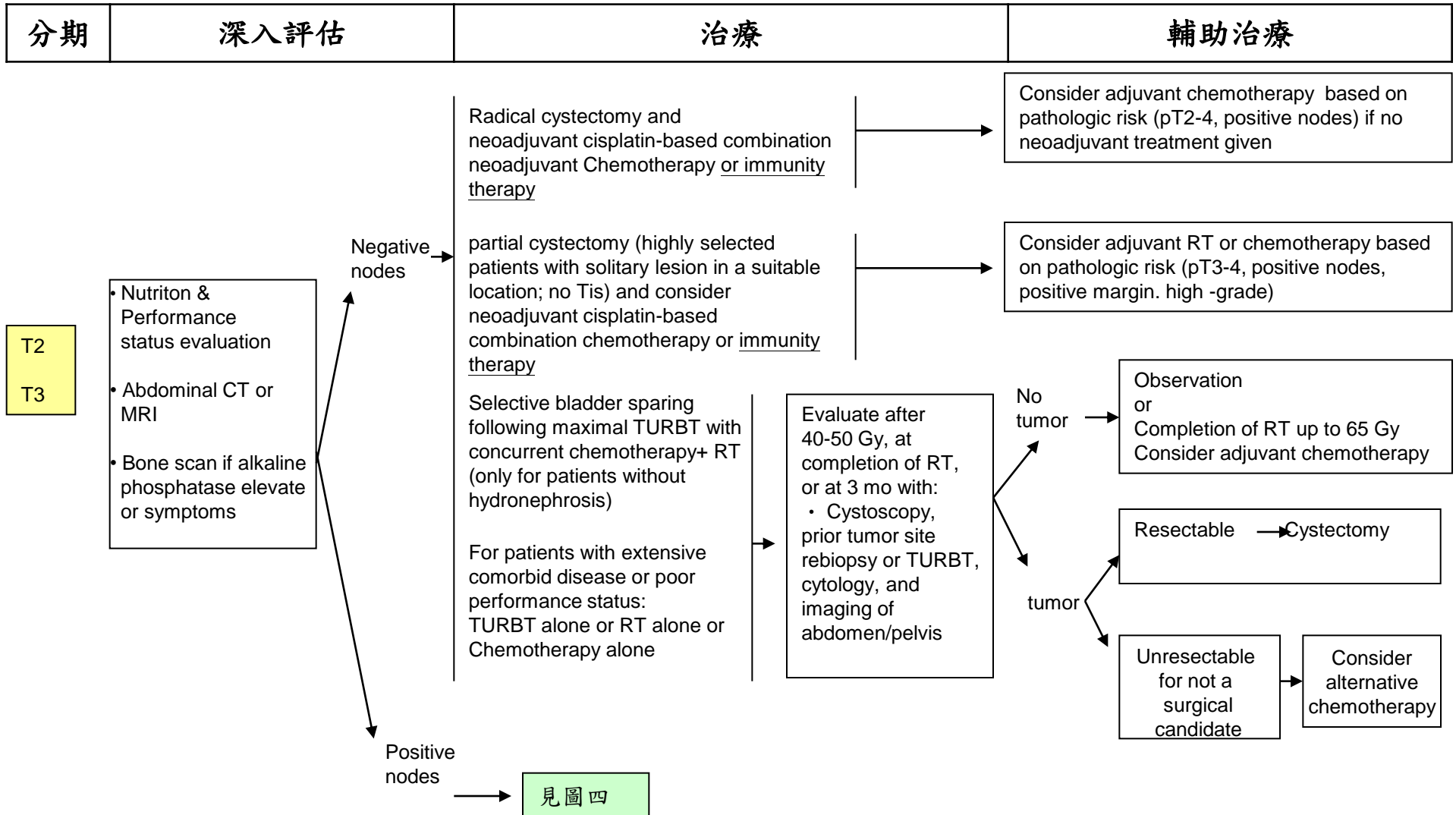
# 膀胱癌(圖二)

高雄榮民總醫院  
臨床診療指引

2018年第一版

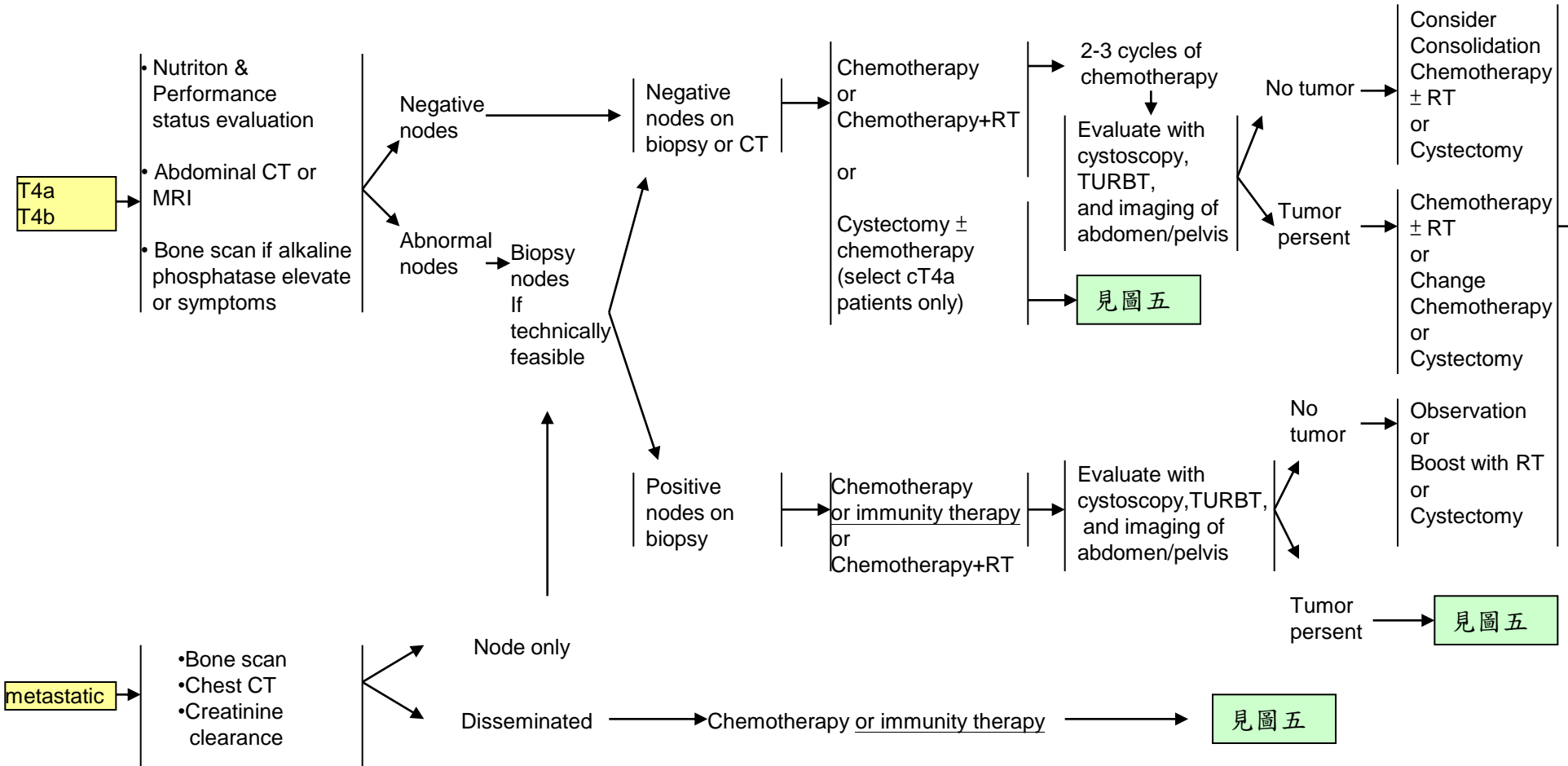


# 膀胱癌(圖三)



# 膀胱癌(圖四)

分期	深入評估	治療	輔助治療
----	------	----	------



見圖五

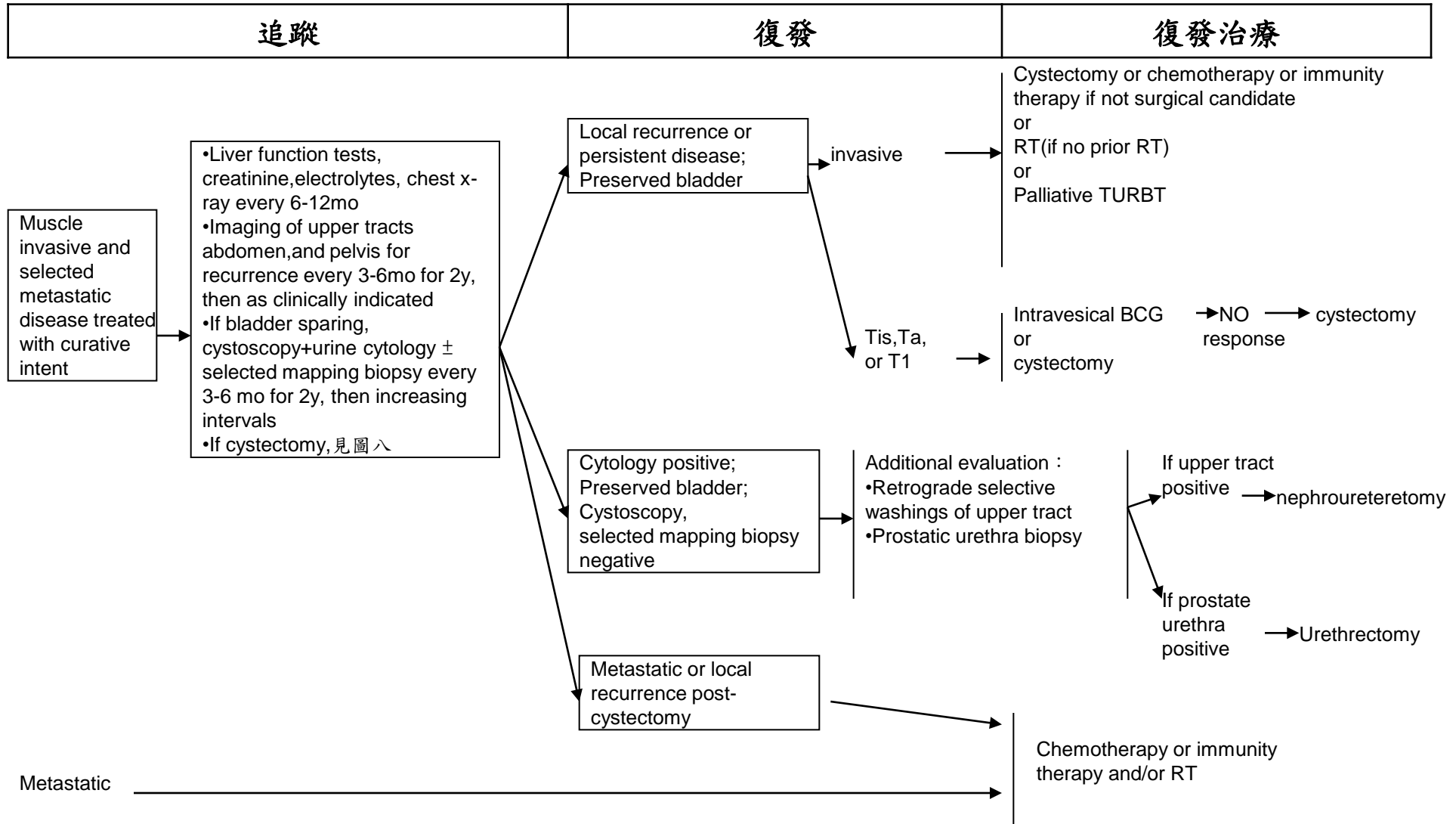
見圖五

見圖五

# 膀胱癌(圖五)

高雄榮民總醫院  
臨床診療指引

2018年第一版



## Principle of surgical management

### TURBT: Papillary

- Adequate resection with muscle If papillary high-grade lesion
- Re-resection If incomplete initial resection, no muscle in specimen or large lesion

### TURBT: Tis

- Multiple random biopsies
- Biopsy adjacent to tumor
- Prostate urethral biopsies

### TURBT: invasive

- Repeat re-resection:
  - ▶ If no muscle in biopsy
  - ▶ Small fragment of T2 insufficient to attribute risk
- Repeat TURBT should be considered if first TURBT does not allow adequate staging or attribution of risk factor for treatment selection or when using bladder-preserving treatment by chemotherapy and/or RT

### PARTIAL CYSTECTOMY

- Solitary lesion in location amenable to segmental resection with adequate margin, no Tis
- Pelvic lymphadenectomy should be performed in conjunction with the segmental cystectomy

### RADICAL CYSTECTOMY

- Radical cystectomy should include bilateral node dissection at a minimum including common, internal and external iliac nodes, and obturator nodes



## Non-Urothelial carcinoma of urinary bladder

Same as Urothelial cell carcinoma management with the following Issues:

### **Mixed Histology**

- Urothelial carcinoma plus pure squamous, glandular adenocarcinoma, micropapillary, nested, plasmacytoid, sarcomatoid should be identified because of the potential to have a more aggressive natural history.
- Follow Urothelial Carcinoma of the Bladder guidelines with complete response less likely if bladder sparing considered

### **Pure Squamous:**

- Cystectomy, RT, or other agents commonly used with squamous cell carcinoma of other sites such as 5-FU, taxanes, methotrexate, etc.

### **Adenocarcinoma**

- Radical cystectomy or partial cystectomy
- Conventional chemotherapy (eg, MVAC) for urothelial carcinoma is not effective, however, the use of chemotherapy or RT should be individualized and maybe of potential benefit in select patients.
- Consider alternative therapy or clinical trial

### **Any Small-cell component:**

- Neoadjuvant or adjuvant chemotherapy using small-cell regimens and local treatment (cystectomy or radiotherapy)
- Primary chemotherapy regimens similar to small cell lung cancer. see small cell lung cancer Guidelines

### **Urachal Carcinoma:**

- Requires complete urachal resection
- Conventional chemotherapy for urothelial carcinoma is not effective, however, the use of chemotherapy or RT should be individualized and maybe of potential benefit in select patients.

### **Primary Bladder Sarcoma**

- See Soft Tissue Sarcoma Guidelines

## Follow-up after cystectomy

### After a radical cystectomy

- Urine cytology, creatinine, electrolytes, every 3 to 6 months for 2 years and then as clinically indicated
- Imaging of the chest, abdomen, and pelvis every 3 to 12 months for 2 years based on risk of recurrence and then as clinically indicated
- Urethral wash cytology, every 6 to 12 month ; particularly if Tis was found within the bladder or prostatic urethra
- if a continent diversion was created, monitor for vitamin B12 deficiency annually

### After a partial cystectomy

- Same follow-up as above, in addition to the following:
  - ▶ Serial cytologic examinations and cystoscopies at 3-month intervals to monitor for relapse in the bladder

## Principle of intravesical treatment

### Intravesical chemotherapy:

Initiated within 24 hours after resection

Regimen: epirubicin 50mg or mitomycin-C 30mg in 50cc normal saline

Induction therapy: initiated 2 weeks after resection, weekly for 6 weeks

Maintenance therapy: role uncertain

### Intravesical BCG therapy:

- Induction therapy:
  - Initiated 2-4 weeks after resection
  - Once weekly for 6 weeks
  - Regimen: BCG in 50cc normal saline
- Maintenance therapy
  - 81 mg BCG intravesical instillation once weekly for 1-3weeks at 3<sup>rd</sup>, 6<sup>th</sup>, 12<sup>th</sup>, 18<sup>th</sup>, 24<sup>th</sup> month
  - Regimen: BCG in 50cc normal saline

# 膀胱癌

高雄榮民總醫院  
臨床診療指引

2018年第一版

\* Perioperative chemotherapy ( Neoadjuvant or Adjuvant )

Regimens :

Regimen	Dosage	
Dose-Dense MVEC	Methotrexate	30MG/M2 on D1 or D2 of a 14 day cycle
	vinblastine	3MG/M2 on D1 or D2
	Epirubicin	45MG/M2 on D1 or D2
	Cisplatin	70MG/M2 on D1 References:NO2
MVEC	Methotrexate	30MG/M2 on D1,15,22
	vinblastine	3MG/M2 on D2,15,22
	Epirubicin	45MG/M2 on D2 References:NO3
	Cisplatin/Carbopatin	70MG/M2 on D2/AUCx4~6MG
Gemcitabine/Cisplatin	Gemcitabine	1000MG/M2 on D1,8,15 of a 28 day cycle
	Cisplatin/Carbopatin	70MG/M2 on D2/AUCx4~6MG References:NO4

註：1.CCr < 60使用Carbopatin 2.This dose should not combined with radiation

# 膀胱癌

高雄榮民總醫院  
臨床診療指引

2018年第一版

\* chemotherapy for metastatic disease

Regimens :

Regimen	Dosage	
Dose-Dense MVEC	Methotrexate	30MG/M2 on D1 or D2 of a 14 day cycle
	vinblastine	3MG/M2 on D1 or D2
	Epirubicin	45MG/M2 on D1 or D2
	Cisplatin	70MG/M2 on D1 References:NO2
MVEC	Methotrexate	30MG/M2 on D1,15,22
	vinblastine	3MG/M2 on D2,15,22
	Epirubicin	45MG/M2 on D2 References:NO3
	Cisplatin/Carbopatin	70MG/M2 on D2/AUCx4~6MG
Gemcitabine/Cisplatin First-line	Gemcitabine	1000MG/M2 on D1,8,15 of a 28 day cycle
	Cisplatin/Carbopatin	70MG/M2 on D2/AUCx4~6MG References:NO4

註：1.CCr <60使用Carbopatin 2.This dose should not combined with radiation

# 膀胱癌

高雄榮民總醫院  
臨床診療指引

2018年第一版

\* Perioperative immunity therapy ( Neoadjuvant or metastatic disease )

Regimens :

Regimen	Dosage	
Aterolizumab	1200MG	in N/S 250ml IVD 60 min (3週一次)
Nivolumab	3MG/KG	in N/S 100ml drip 60 min (2週一次)
Pembrolizumab	200MG	in N/S 100ml drip 30 min (3週一次)

# 膀胱癌

高雄榮民總醫院

臨床診療指引

2018年第一版

## Principles of chemotherapy management

ΔDose-Dense MVEC regimen with growth factor support for 3 or 4 cycles

ΔMVEC regimen regimen for 6 cycles

Δ Gemcitabine/Cisplatin regimen for 6 cycles

# 膀胱癌

高雄榮民總醫院  
臨床診療指引

2018年第一版

\* CCRT Regimens :

Regimen	Dosage		
Cisplatin alone	Cisplatin	35MG/M2 weekly	References:NO3



## Reference

1. NCCN Clinical Practice Guideline in Oncology for Bladder Cancer ,Version 2,2018
2. Grossman HB, Natale RB, Tangen CM, et al Neoadjuvant chemotherapy plus cystectomy compared with cystectomy alone for locally advanced bladder cancer. N Engl J Med 2003;349:859-866.
3. Sternberg CN, de Mulder PH, Schornagel JH, et al. Randomized phase III trial of high-dose-intensity methotrexate, vinblastine, doxorubicin, and cisplatin(MVAC) chemotherapy and recombinant human granulocyte colony-stimulating factor versus classic MVAC in advanced urothelial tract tumors: European Organization for Research and Treatment of Cancer Protocol no. 30924. J Clin Oncol 2001;19:2638-2646.
4. Dash A, Pettus JA, Herr HW, et al. A role for neoadjuvant gemcitabine plus cisplatin in muscle-invasive urothelial carcinoma of the bladder: a retrospective experience. Cancer 2008;113:2471-2477.
5. Campbell-Walsh Urology, 9th edition, 2007
6. European Association of Urology Guideline, 2016
7. Balar AV, Galsky MD, Rosenberg JE, et al. Atezolizumab as first-line treatment in cisplatin ineligible patients with locally advanced and metastatic urothelial carcinoma: a single-arm, multicentre, phase 2 trial. Lancet 2018;389:67-76.
8. Balar AV, Castellano DE, O'Donnell PH, et al. Pembrolizumab as first-line treatment in cisplatin ineligible advanced urothelial carcinoma: Results from the total KEYNOTE-052 study population [abstract ]. J Clin Oncol 2018;36:Abstract 284.
9. Sharma P, Retz M, Siefker-Radtke A, et al. Nivolumab in metastatic urothelial carcinoma after platinum therapy(Checkmate 275):A multicentre, single-arm, phase 2 trial. Lancet Oncol 2018.