

# 高雄榮民總醫院

## 食道癌診療原則

2018年01月23日第一版

食道癌醫療團隊共同擬定

注意事項：這個診療準則主要作為醫師和其他保健專家診療癌症病人參考之用。假如你是一個癌症病人，直接引用這個研究資訊及診療準則並不恰當。只有你的醫師才能決定給你最恰當的治療。

# 修訂指引

- 本共識依下列參考資料修改版本

Reference: NCCN Clinical Practice Guidelines in Oncology<sup>TM</sup>,  
Esophageal cancer, V.1.2018

# 會議討論

上次會議：2017/05/09

## 本共識與上一版的差異

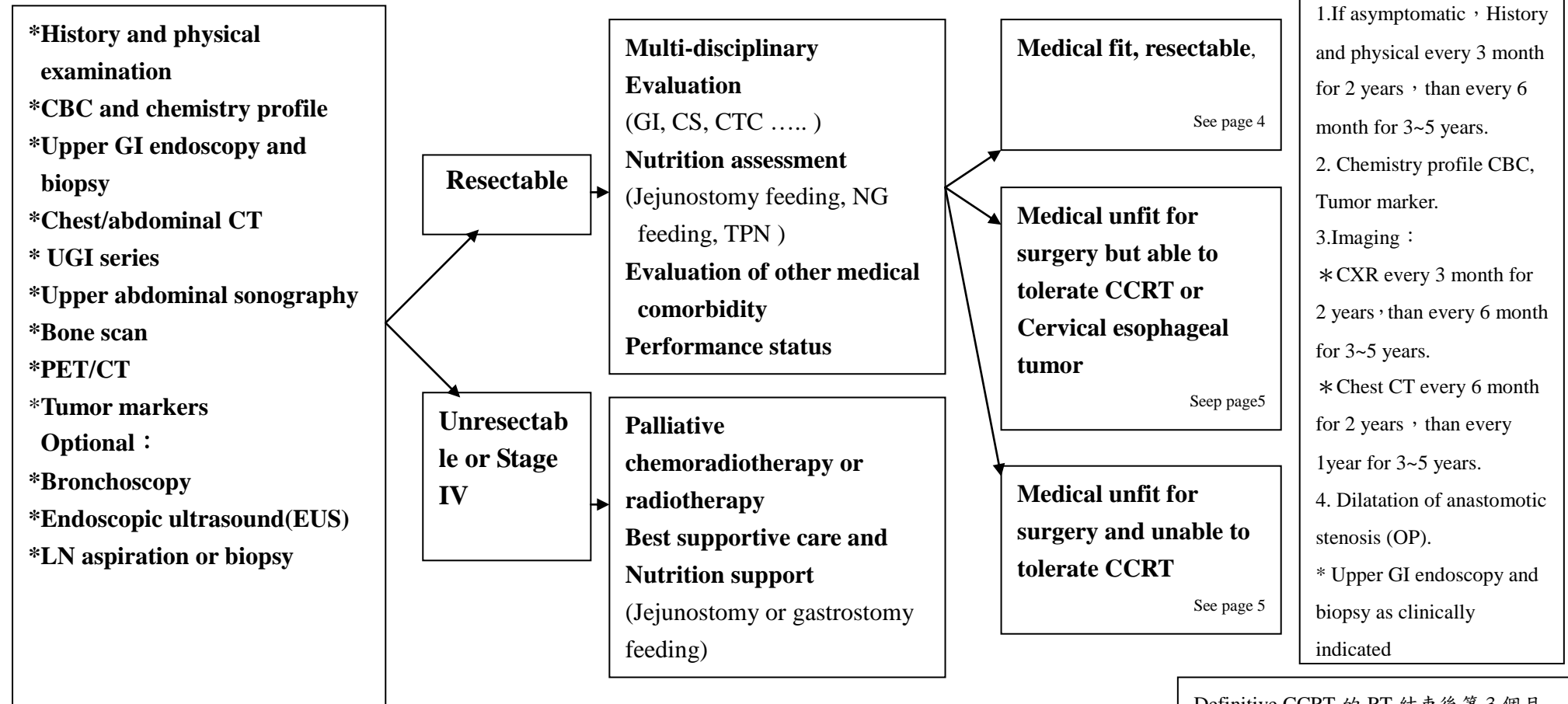
上一版	新版
1. Pre-OP CCRT *with Surgical Resection 2.化學治療處方 Published C/T regimens	1.Pre-OP CCRT*/chemotherapy* with surgical resection (page 5、7) 2. Published C/T regimens (neoadjuvant/adjuvant/CCRT/metastasis) (page 9)

# 食道癌(總表)

高雄榮民總醫院

臨床診療指引 2018.01 第一版

評估	診斷	治療	追蹤
----	----	----	----

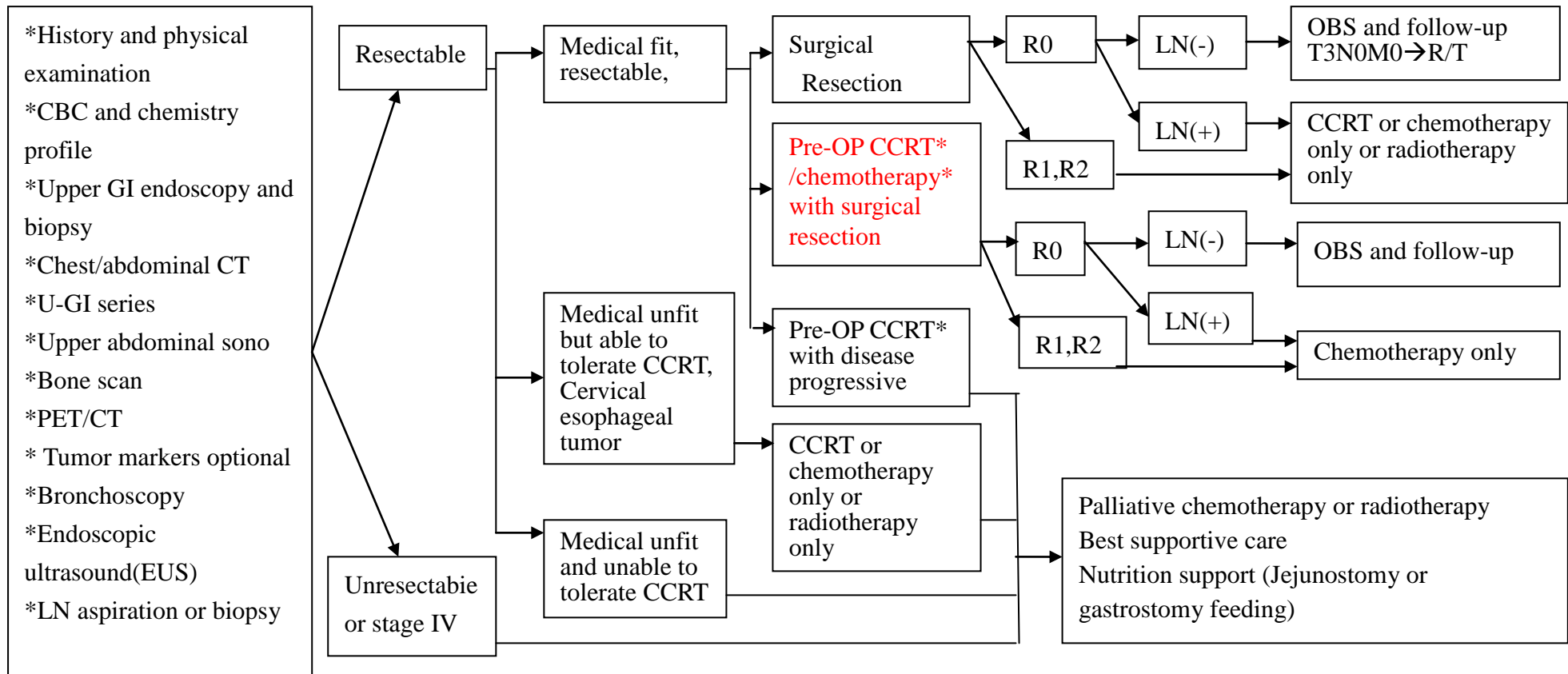


Definitive CCRT 的 RT 結束後第 3 個月 FOLLOW UP chest CT

# 食道癌

高雄榮民總醫院  
臨床診療指引 2018.01 第一版

評估	診斷	治療	追蹤
----	----	----	----



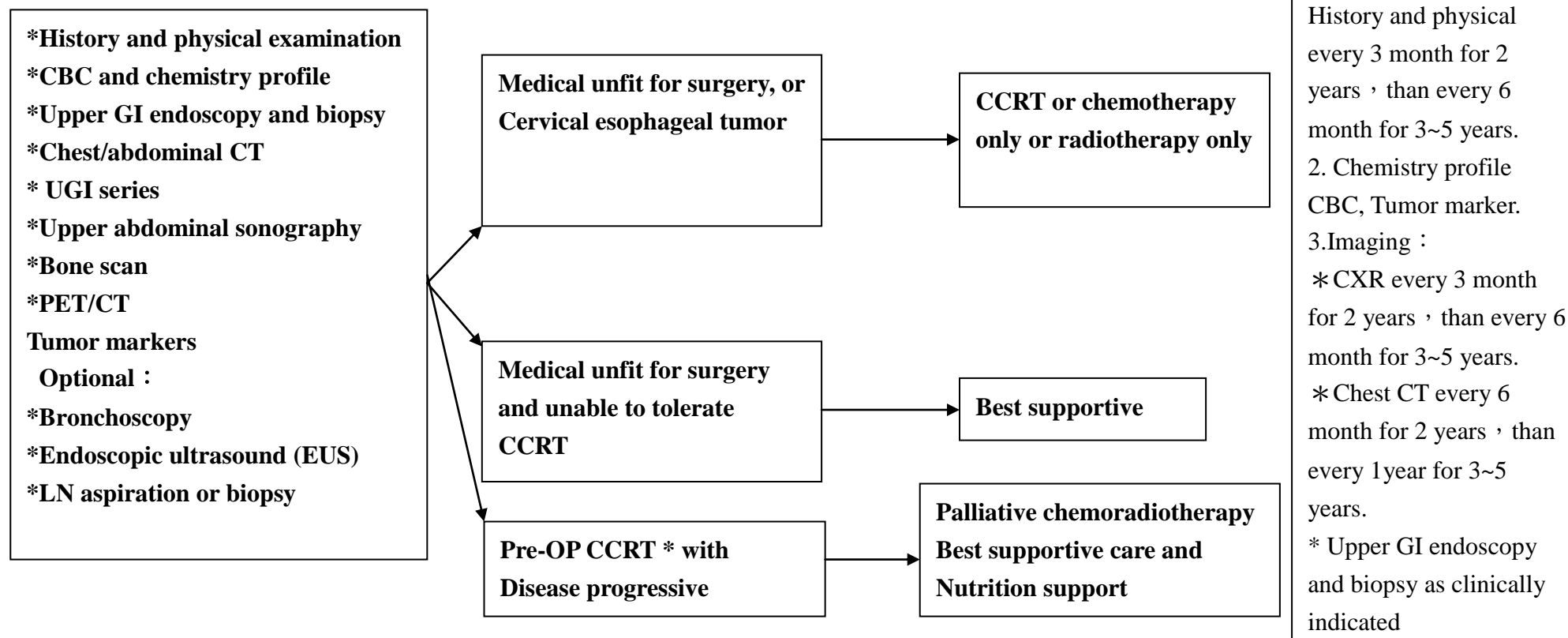
\* Criteria : T3-4 or N+

# 食道癌

高雄榮民總醫院

臨床診療指引 2018.01 第一版

評估	診斷	治療	追蹤
----	----	----	----



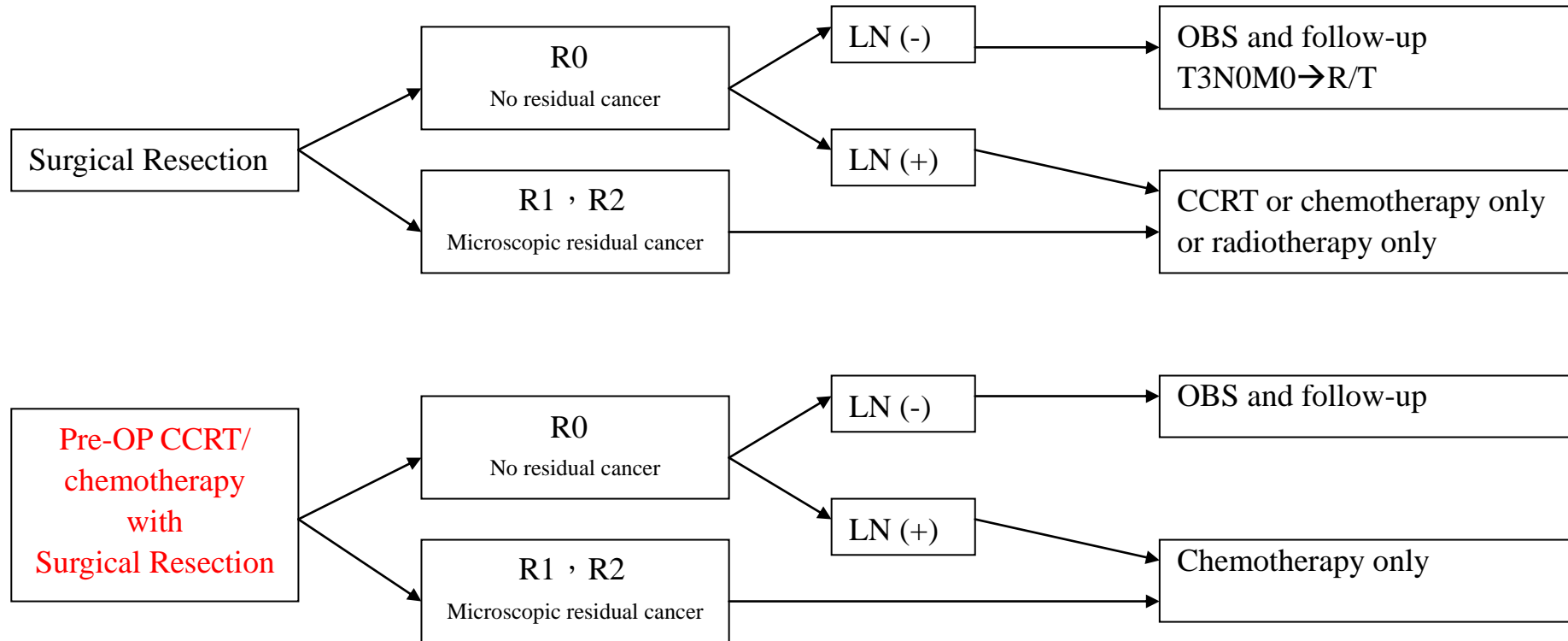
Definitive CCRT 的 RT 結束後第 3 個月  
FOLLOW UP chest CT

# 食道癌

高雄榮民總醫院

臨床診療指引 2018.01 第一版

Surgical outcomes after esophagectomy/ Clinical pathologic findings	Tumor classification	Postoperative treatment
--	----------------------	-------------------------

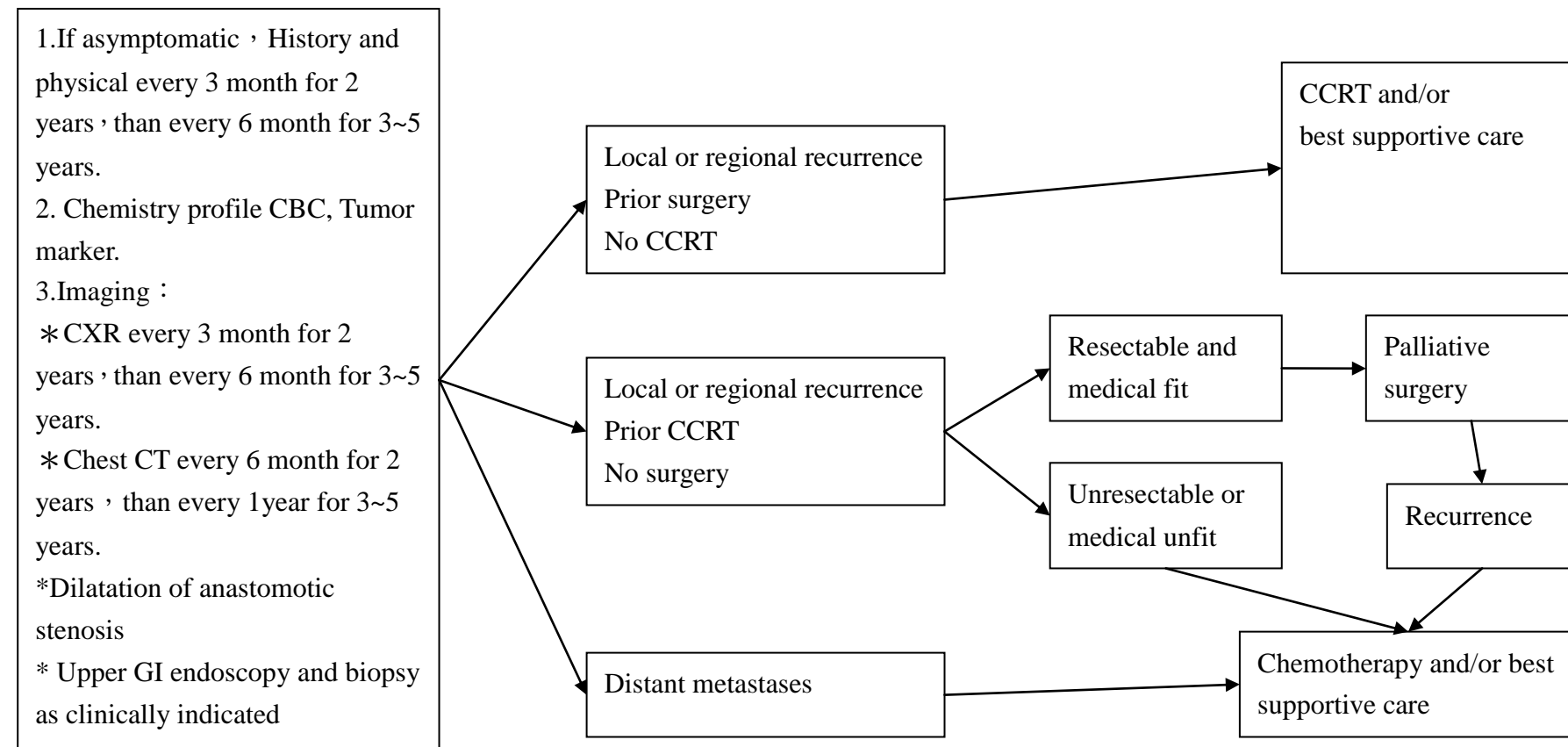


# 食道癌

高雄榮民總醫院

臨床診療指引 2018.01 第一版

Follow-up	Recurrence	Palliative therapy
-----------	------------	--------------------



Definitive CCRT 的 RT 結束後第 3 個月  
FOLLOW UP chest CT



# 食道癌

高雄榮民總醫院

臨床診療指引 2018.01 第一版

## 化學治療處方

Published C/T regimens(neoadjuvant/adjutant/CCRT/metastasis)	Schedule	
Cisplatin 60-75mg/m <sup>2</sup> , IV ,D1/ Carboplatin AUC 4-6 mg, IV ,D1 ( Ccr <60 ) Fluorouracil, 600-1000 mg/m <sup>2</sup> , IV ,D1-4 (Reference No.22)	Q28 D x 4-6 cycles	Performance status (ECOG) ≤ 2 or Kamofsky Performance score ≥ 60
Cisplatin 60-75 mg/m <sup>2</sup> , IV ,D1/ Carboplatin AUC 4-6 mg, IV ,D1 ( Ccr <60 ) Etoposide 60-100 mg/m <sup>2</sup> , IV ,D1-3 (Reference No.23)	Q21 D x 4-6 cycles	Performance status (ECOG) ≤ 2 or Kamofsky Performance score ≥ 60
Taxol 140-175 mg/m <sup>2</sup> , IV ,D1 Cisplatin 20 mg/m <sup>2</sup> , IV ,D1-5/ Carboplatin AUC 1mg, IV ,D1-5 ( Ccr <60 ) Fluorouracil,600-750 mg/m <sup>2</sup> , IV ,D1-5 (Reference No.24)	Q14D x 4-6 cycles	Performance status (ECOG) ≤ 2 or Kamofsky Performance score ≥ 60
Cisplatin 60 mg/m <sup>2</sup> , IV ,D1/ Carboplatin AUC 4-6 mg, IV ,D1 ( Ccr <60 ) Xeloda 2.5TAB/ m <sup>2</sup> , PO,D1-14 (Reference No.27)	Q21 D x 4-6 cycles	Performance status (ECOG) ≤ 2 or Kamofsky Performance score ≥ 60
Ufur 3CAP/m <sup>2</sup> , PO,D1-14	Q28D x6 cycles	Performance status (ECOG) ≤ 2 or Kamofsky Performance score ≥ 60
Mitomycin 5- 7 mg/m <sup>2</sup> , IV ,D1 Cisplatin 50-60 mg/m <sup>2</sup> , IV ,D1/ Carboplatin AUC 4-6 mg, IV ,D1 ( Ccr <60 ) Fluorouracil,480~600 mg/m <sup>2</sup> , IV ,D1 (Reference No.28)	MitomycinQ42D Cisplatin Q21D 5-FU QD MCF x 4-6 cycles	Performance status (ECOG) ≤ 2 or Kamofsky Performance score ≥ 60

Mitomycin 5- 7 mg/m <sup>2</sup> , IV ,D1 Cisplatin 45-60 mg/m <sup>2</sup> , IV ,D1/ Carboplatin AUC 4-6 mg, IV ,D1 ( Ccr <60 ) Ufur 3CAP/m <sup>2</sup> , PO,D1-14 (Reference No.28)	MitomycinQ42D Cisplatin Q21D Ufur QD MCU x 4-6 cycles	Performance status (ECOG) ≤ 2 or Kamofsky Performance score ≥ 60
Tarceva 150mg 1TAB, PO (Reference No.29)	QD (to disease progression)	Performance status (ECOG) ≤ 2 or Kamofsky Performance score ≥ 60

備註【1】依據影像學檢查發現疾病 progression disease 或【2】依據達到 Grade 3 : Severe or advance Side effect，即先停藥，再視病患情況決定繼續治療或改變處方。

# 食道癌

高雄榮民總醫院  
臨床診療指引 2018.01 第一版

## Radiotherapy (Reference No.15-21)

### Dose prescription

Combination with operation (Pre-operative or post operative RT)	1.8-2 Gy, total 45-50.4 Gy, 25-28 fraction
Concurrent CCRT without operation	1.8-2 Gy, total 50.4-59.4 Gy, 28-33 fractions
RT alone	1.8-2 Gy, total 54-64 Gy, 27-35 fractions

When the radiation dosage reach 45 Gy , the stomach area should be blocked.

### Field design

Preoperative RT or CCRT :

GTV = primary lesion and involved LN; CTV = GTV + subclinical disease (regional LN and submucosal), 4 cm proximal/distal and 1 cm radial;  
PTV = CTV + 1 - 2 cm.

Tumors above the carina: treat SCV and mediastinal LN.

Tumors at or below the carina: treat mediastinal LN, and include celiac LN for lower 1/3 and gastroesophageal junction tumors.

Postoperative RT : depended by operative findings and pathological report.

Dose limitation :

Spinal cord :  $D_{max} \leq 46$  Gy at 1.8-2 Gy/fraction

Lung :  $V_{20}$  (volume receiving  $\geq 20$  Gy) < 35% .

Heart :  $V_{40}$  < 50% .

## Reference :

1. NCCN Clinical Practice Guidelines in Oncology™, Esophageal cancer , V.1.2017.
2. Steyerberg EW, Neville BA, Kopper LB, Lemmens VE, et al. Surgical mortality in patients with esophageal cancer: development and validation of a simple risk score. *J Clin Oncol* 2006;24 (26):4277-4284.
3. Fujita H, Sueyoshi S, Yamana H, Shinozaki K et al., Optimum treatment strategy for superficial esophageal cancer: Endoscopic mucosal resection versus radical esophagectomy. *World Journal of Surgery*; 2001; 25: 424-431.
4. Ell C, May A, Gossner L, Pech O, et al., Endoscopic mucosal resection of early cancer and high-grade dysplasia in Barrett's esophagus. *Gastroenterology* 2000; 118: 670-677.
5. Conio M, Repici A, Cestari R, Blanchi S, et al., Endoscopic mucosal resection for high-grade dysplasia and intramucosal carcinoma in Barrett's esophagus: An Italian experience. *World Journal of Gastroenterology* 2005; 11(42): 6650-6655.
6. Larghi A, Lightdale CJ, Ross AS, Fedi P, et al., Long-term follow-up of complete Barrett's eradication endoscopic mucosal resection (CBE-EMR) for the treatment of high-grade dysplasia and intramucosal carcinoma. *Endoscopy* 2007;39: 1086-1091.
7. Lopes CV, Hela M, Pesenti C, Bories E, et al., Circumferential endoscopic resection of Barrett's esophagus with high-grade dysplasia or early adenocarcinoma. *Surgical Endoscopy* 2007; 21: 820-824.
8. Overholt BF, Wang KK, Burdick S, Lightdale CJ, et al., Five-year efficacy and safety of photodynamic therapy with Photofrin in Barrett's high-grade dysplasia. *Gastrointestinal Endoscopy* 2007; 66(3): 460-468.
9. de Hoyos A, Litle VR, and Luketich JD. Minimally invasive esophagectomy. *Surg Clin North Am* 2005;85 (3): 631-647.
10. Hofstetter WL. Lymph Node Dissection in Esophageal Cancer. *Current Therapies in Thoracic and Cardiovascular Surgery*, edited by SC Yang and DE Cameron. Mosby, Inc., Philadelphia, Pennsylvania, pp. 360-363, 2004.
11. Swisher SG, Wynn P, Putnam JB, Mosheim MB, et al. Salvage esophagectomy for recurrent tumors after definitive chemotherapy and radiotherapy. *J Thorac Cardiovasc Surg* 2002;123:175-183.
12. Birkmeyer JD, Siewers AE, Finlayson EVA, Stukel TA, et al. Hospital volume and surgical mortality in the United States. *N Engl J Med* 2002;346(15):1128-1137.
13. Hulscher JBF, van Sandick JW, de Boer AG, et al. Extended transthoracic resection compared with limited transhiatal resection for adenocarcinoma of the esophagus. *N Engl J Med*, 2002;347(21):1662-1669
14. AJCC 7<sup>th</sup> edition

### **Reference for Radiotherapy :**

15. Herskovic A; Martz K; al-Sarraf M et al.: Combined chemotherapy and radiotherapy compared with radiotherapy alone in patients with cancer of the esophagus. *N Engl J Med* 1992;326(24):1593-8.
16. Al-Sarraf M; Martz K; Herskovic A et al.: Progress report of combined chemoradiotherapy versus radiotherapy alone in patients with esophageal cancer: an intergroup study. *J Clin Oncol* 1997;15(1):277-84.
17. Cooper JS; Guo MD; Herskovic A et al.: Chemoradiotherapy of locally advanced esophageal cancer: long-term follow-up of a prospective randomized trial (RTOG 85-01). Radiation Therapy Oncology Group. *JAMA* 1999;281(17):1623-7.
18. Minsky BD; Pajak TF; Ginsberg RJ et al.: INT 0123 (Radiation Therapy Oncology Group 94-05) phase III trial of combined-modality therapy for esophageal cancer: high-dose versus standard-dose radiation therapy. *J Clin Oncol* 2002;20(5):1167-74.
19. Shioyama Y; Nakamura K; Sasaki T et al.: Clinical results of radiation therapy for stage I esophageal cancer: a single institutional experience. *Am J Clin Oncol* 2005;28(1):75-80.
20. Chen J; Zhu J; Pan J et al: Postoperative radiotherapy improved survival of poor prognostic squamous cell carcinoma esophagus. *Ann thorac surg* 2010;90(2):435-42
21. Chen J; Pan J; Zheng X et al: Number and location of positive nodes, postoperative radiotherapy and survival after esophagectomy with three field lymph node dissection for thoracic esophageal squamous cell carcinoma. *Int. J. Radiation Oncology Biol. Phys.* 2012; 82 (1):475–82

### **Reference for Chemotherapy :**

22. Phase III Trial of Trimodality Therapy With Cisplatin, Fluorouracil, Radiotherapy, and Surgery Compared With Surgery Alone for Esophageal Cancer: CALGB 9781. *J Clin Oncol* 26:1086-1092.
23. Chemotherapy with cisplatin or carboplatin in combination with etoposide for small-cell esophageal cancer: a systemic analysis of case series. *Diseases of the Esophagus* 9 OCT 2013, DOI: 10.1111/dote.12149.
24. Phase II trial of paclitaxel, fluorouracil, and cisplatin in patients with advanced carcinoma of the esophagus. *JCO* 1998, 16(5),p 1826-1834.
25. Phase III Study of Docetaxel and Cisplatin Plus Fluorouracil Compared With Cisplatin and Fluorouracil As First-Line Therapy for Advanced Gastric Cancer: A Report of the V325 Study Group. *J Clin Oncol* 24:4991-4997.
26. Perioperative Chemotherapy versus Surgery Alone for Resectable Gastroesophageal Cancer. *N Engl J Med* 2006; 355:11-20.
27. Definitive Chemoradiotherapy with Capecitabine and Cisplatin in Patients with Esophageal Cancer: A Pilot Study. *J Korean Med Sci* 2009; 24:

120-5.

28. Prospective Randomized Trial Comparing Mitomycin, Cisplatin, and Protracted Venous-Infusion Fluorouracil (PVI 5-FU) With Epirubicin, Cisplatin, and PVI 5-FU in Advanced Esophagogastric Cancer. *J Clin Oncol* 20:1996-2004.
29. A Phase 2 Trial of Erlotinib in Patients With Previously Treated Squamous Cell and Adenocarcinoma of the Esophagus. *Cancer* 2011;117:1409–14.
30. Common Terminology Criteria for Adverse Events (CTCAE) Version 4.0 Published: May 28, 2009 (v4.03: June 14, 2010) U.S.DEPARTMENT OF HEALTH AND HUMAN SERVICES. National Institutes of Health National Cancer Institute.

