Nuclear Oncology

Remarkable responses to Bi-213-DOTATOC observed in tumors resistant to previous therapy with Y-90/Lu-177-DOTATOC

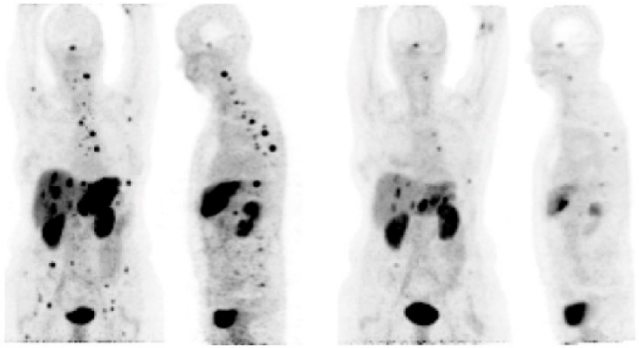

Case I: Shrinkage of liver lesions and bone metastases after i.a. therapy with 11 GBq Bi-213-DOTATOC

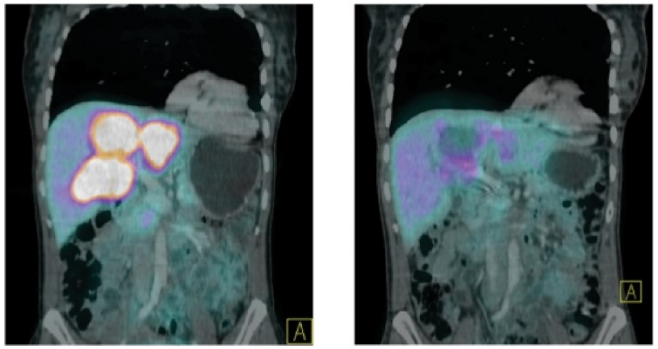

Case II: Response of multiple liver lesions after i.a. therapy with 14 GBq Bi-213-DOTATOC

SNM 2012 Image of the Year

彭南靖

民國105年10月13日

VGHKS-NM Logo

Logo說明



邊緣象徵: 1 有如太陽的光輝
2 如同細胞膜上各種功能構造

圓形象徵: 1 完滿，也象徵如同輪胎一樣不斷向前進
2 細胞膜

原子圖樣浮起: 凸顯強調「核子」
原子核一角象徵會衰變的同位素

藍色象徵科技，用以標明高雄榮總核醫是科技的部門

綠色底色與本院Logo有一致性

總結：此Logo象徵分子生物的、科技的、追求進步的高榮核醫科

Nanotechnology

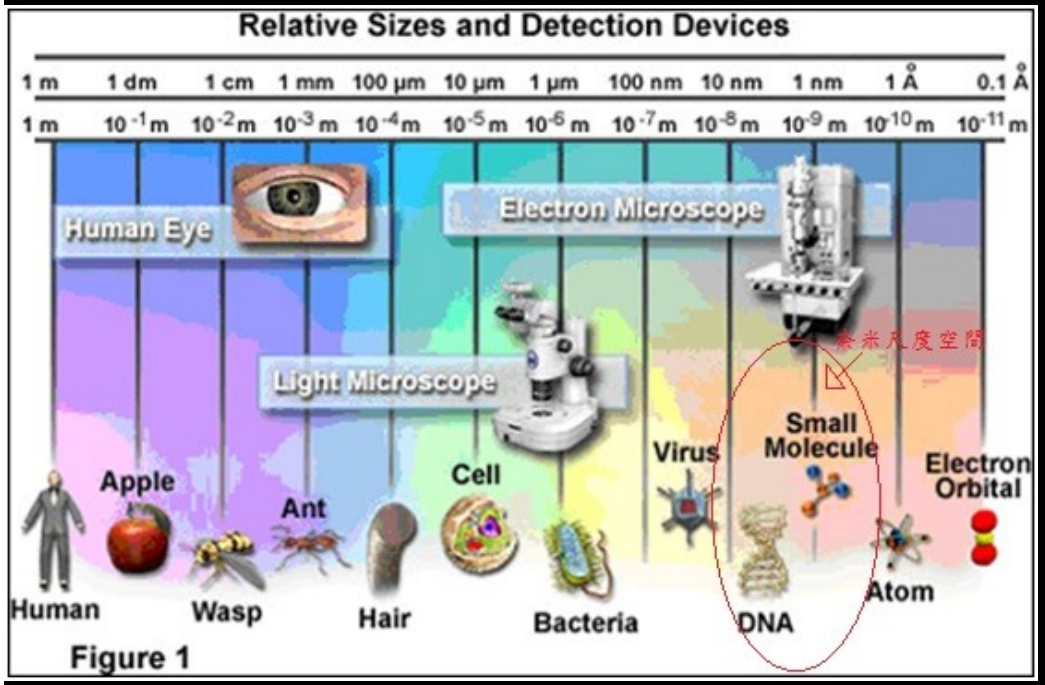

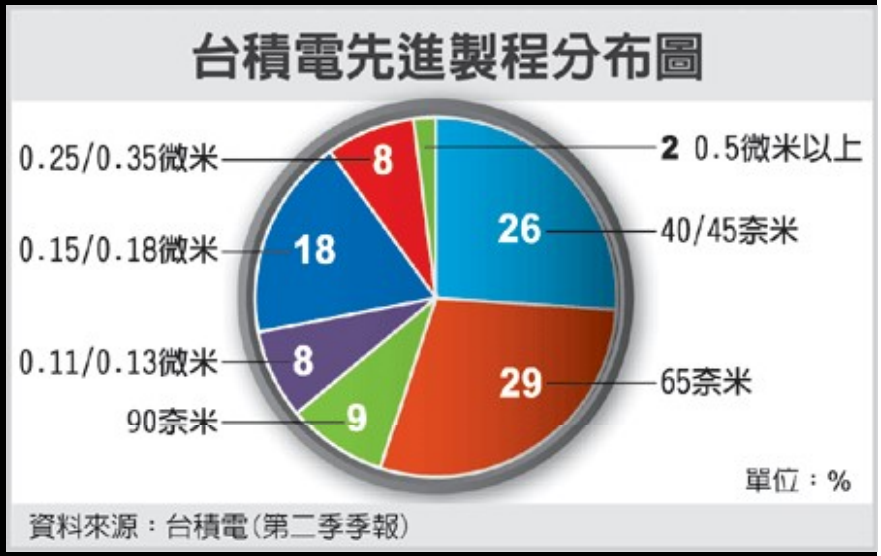

奈米（符號 nm，英式英文：nanometre、美式英文：nanometer，字首 nano 在希臘文中的原意是「侏儒」的意思），是一個長度單位，指1米的十億分之一（10^{-9}m）。

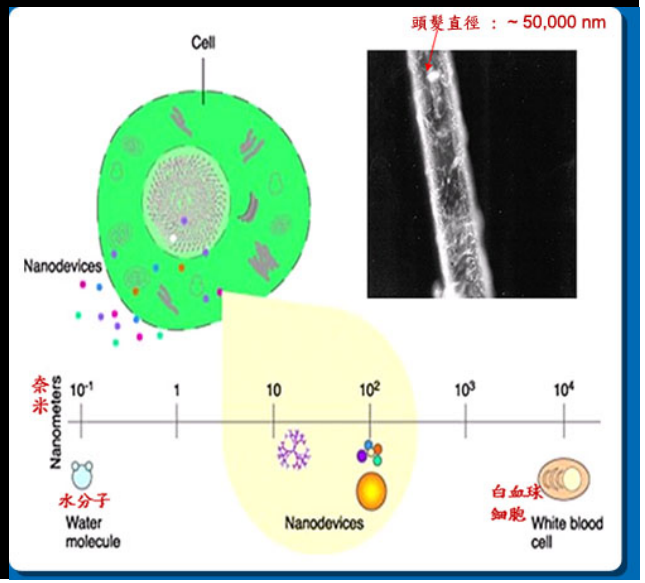

Nuclear Oncology-
Clinical Application

- Tumor markers
- Radionuclide imaging
- Radionuclide therapy

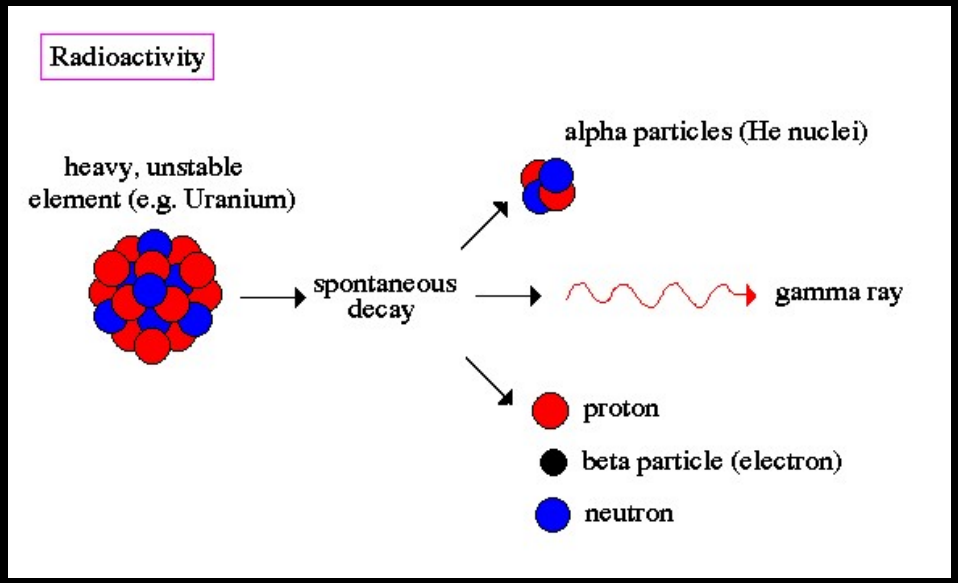

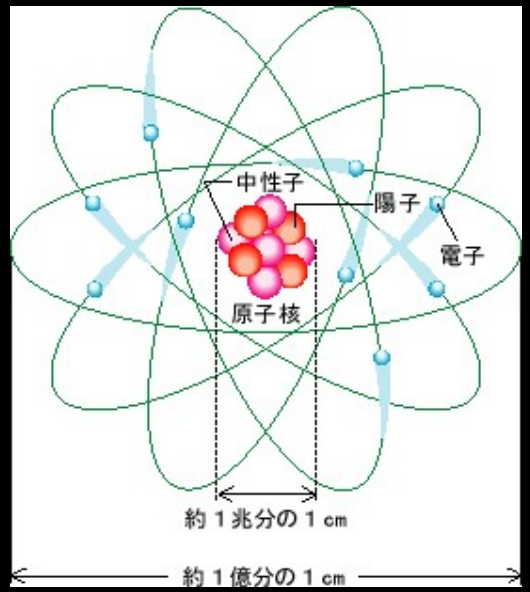

Tumor markers

- Tumor markers are substances that can be detected in higher-than-normal amounts in the blood, urine, or body tissues of some patients with certain types of cancer. A tumor marker may be made by a tumor itself or by the body in response to the tumor. Such a substance serves to "mark" the tumor; it is a "tumor marker."

Once a particular tumor has been found with a marker, the marker may be a marvel as a means of monitoring the success (or failure) of treatment. The tumor marker level may also reflect the extent (the stage) of the disease, indicate how quickly the cancer is likely to progress and so help determine the prognosis.

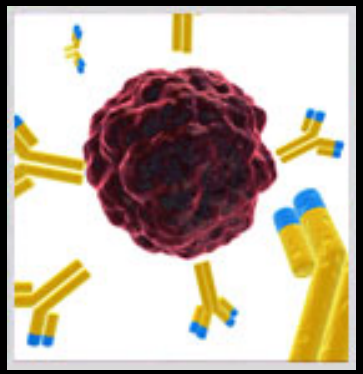

Tumor markers

- Radioimmunoassay (RIA)

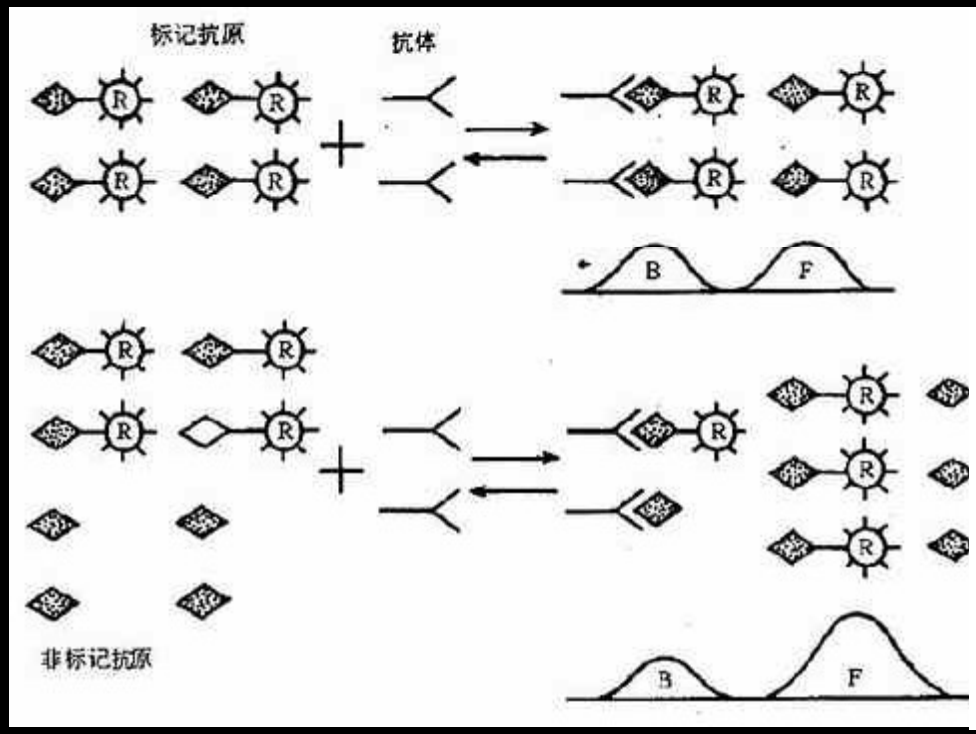

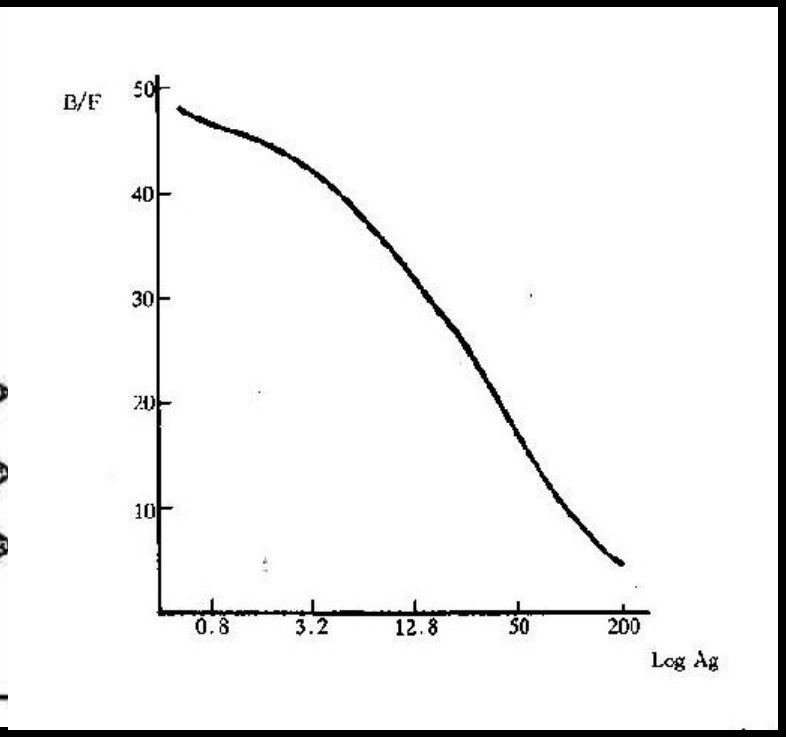

Tumor markers

Tumor type	Tumor marker
Colorectal cancer	CEA
Pancreas cancer	CA 19.9
Gastric cancer	CA 72-4
HCC	AFP
Lung cancer	Cyfra 21-1
Breast cancer	CA 15.3
Prostate cancer	PSA
Ovary cancer	CA 125
Cervical cancer	SCC

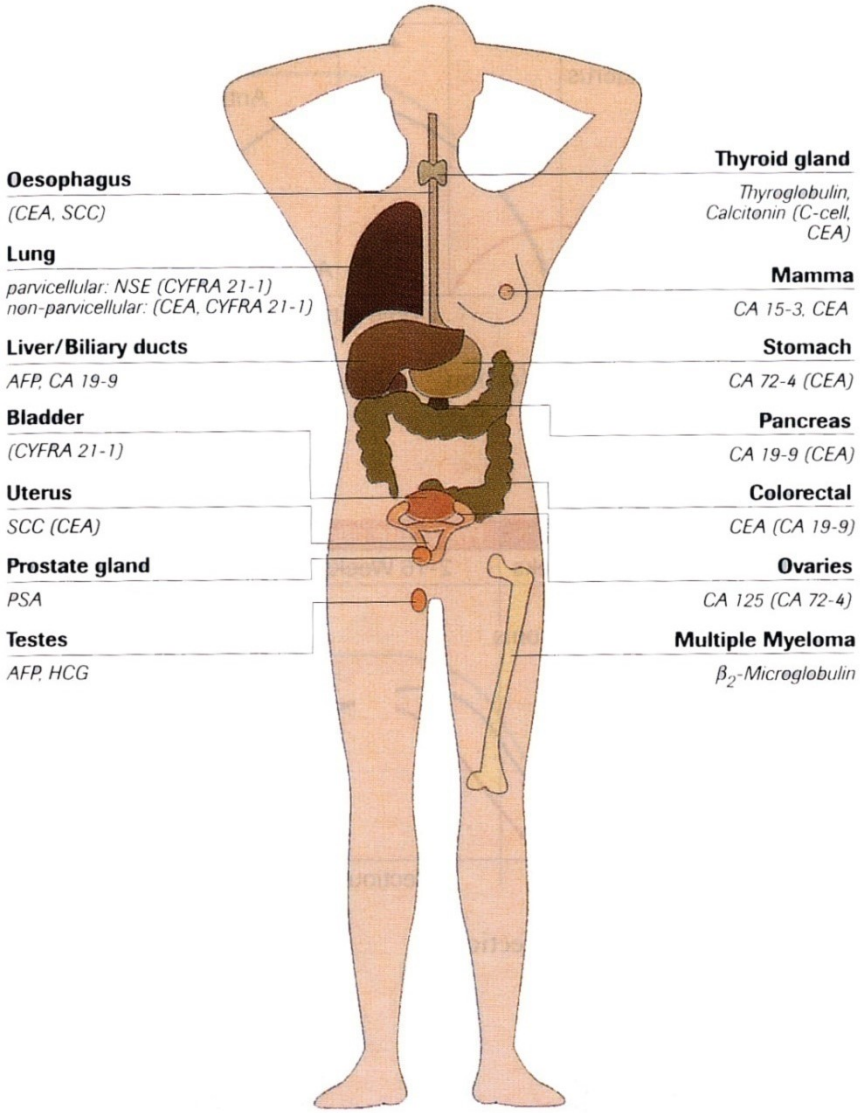

Colon cancer

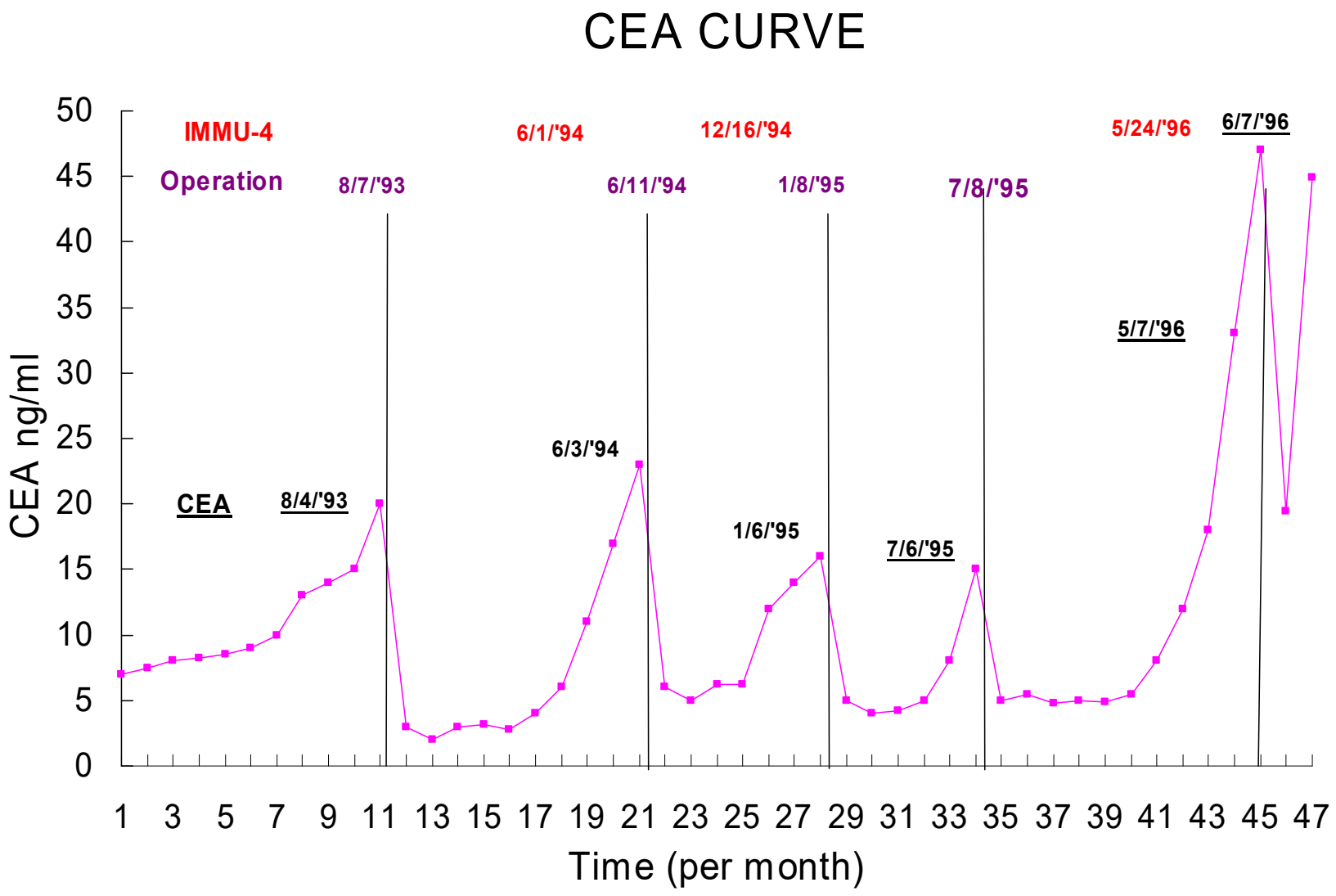

Clinical Application of Nuclear Oncology

- Tumor markers
- Radionuclide imaging
- Radionuclide therapy

采之欲遺誰？所思在遠道。

Resolution→ Resolution → Resolution

High resolution CT







Where is Waldo?

What Next?

Spy

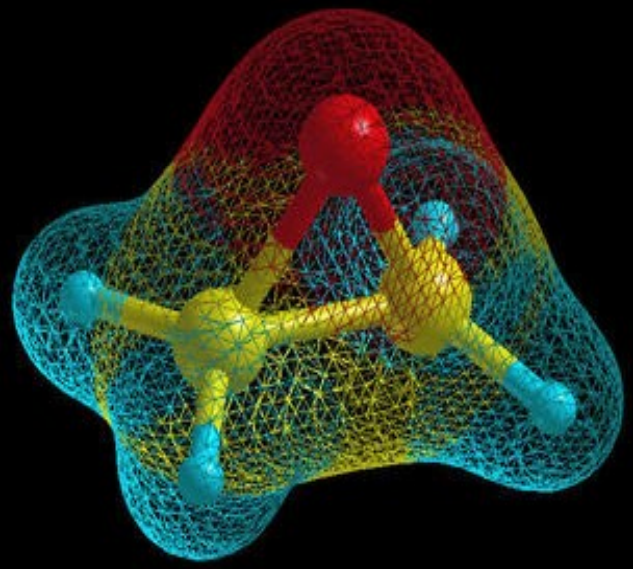

Molecular Probe

PET/SPECT

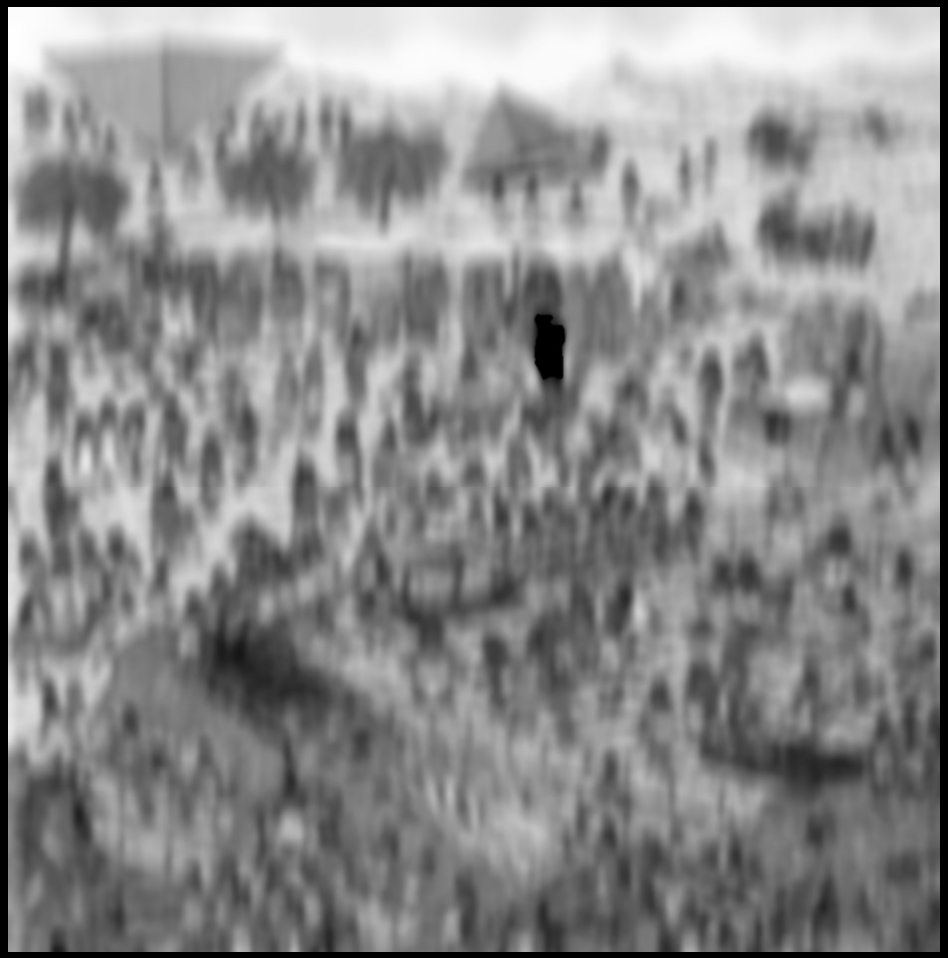

Where is Waldo?

Fused images



Here's Waldo!

Overview of tumor Scintigraphy

- Tumor-type specific radionuclides
  - –Thyroid cancer: I-131or I-123
  - –Catecholamine-secreting tumors: I-131 or I-123 MIBG
  - –Somatostatin receptor imaging
  - –Radioimmunodetection
  - –PET (F-18 DOPA, Ga-68 DOTA peptides, etc.)
- Non-specific tumor imaging radionuclides
  - –Ga-67
  - –Tl-201
  - –Tc-99m sestamibi
  - –Lymphoscintigraphy
  - –PET (F-18 FDG, C-11 acetate, F-18 choline etc.)

Mechanism of thyroid uptake

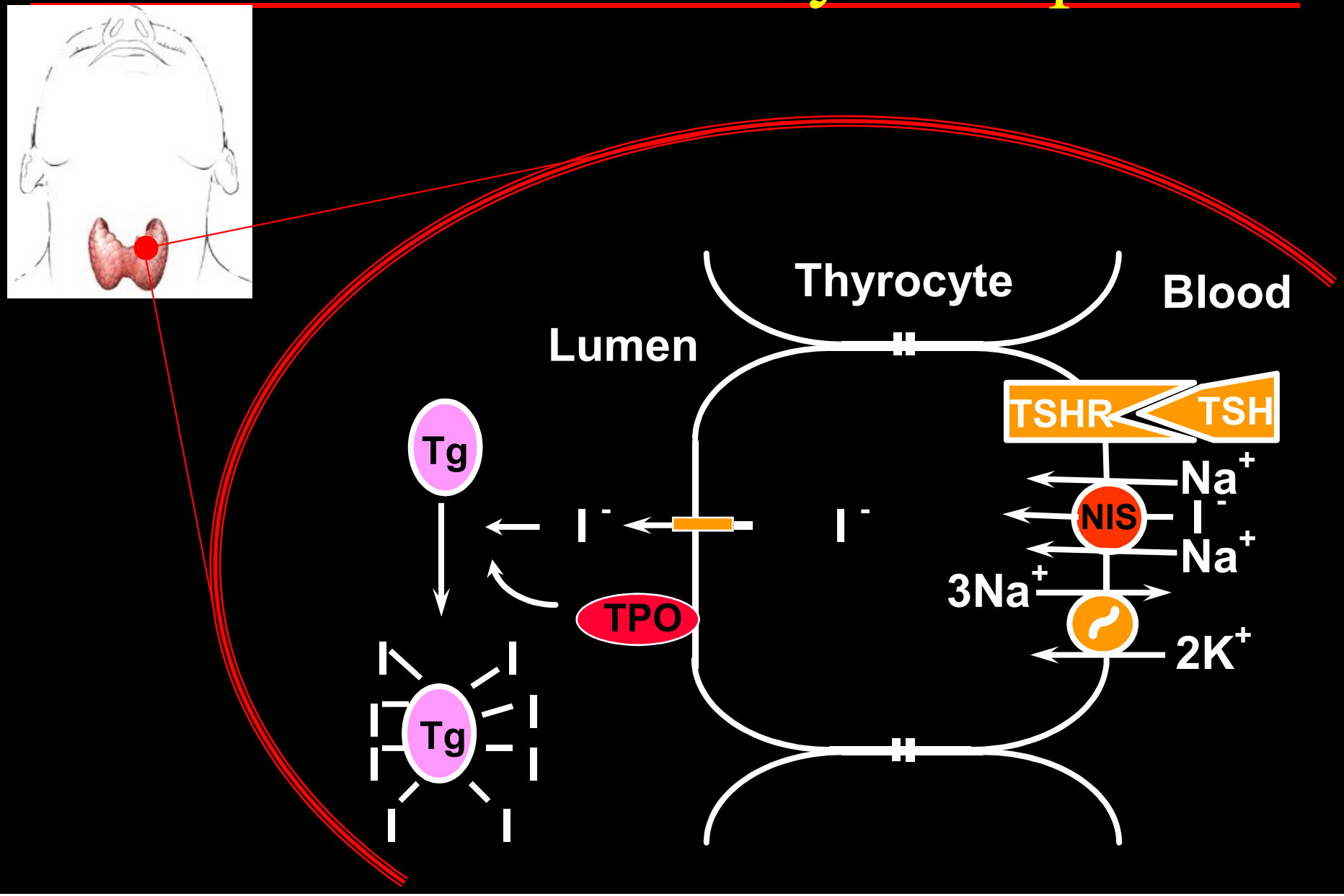

Differentiated thyroid carcinoma

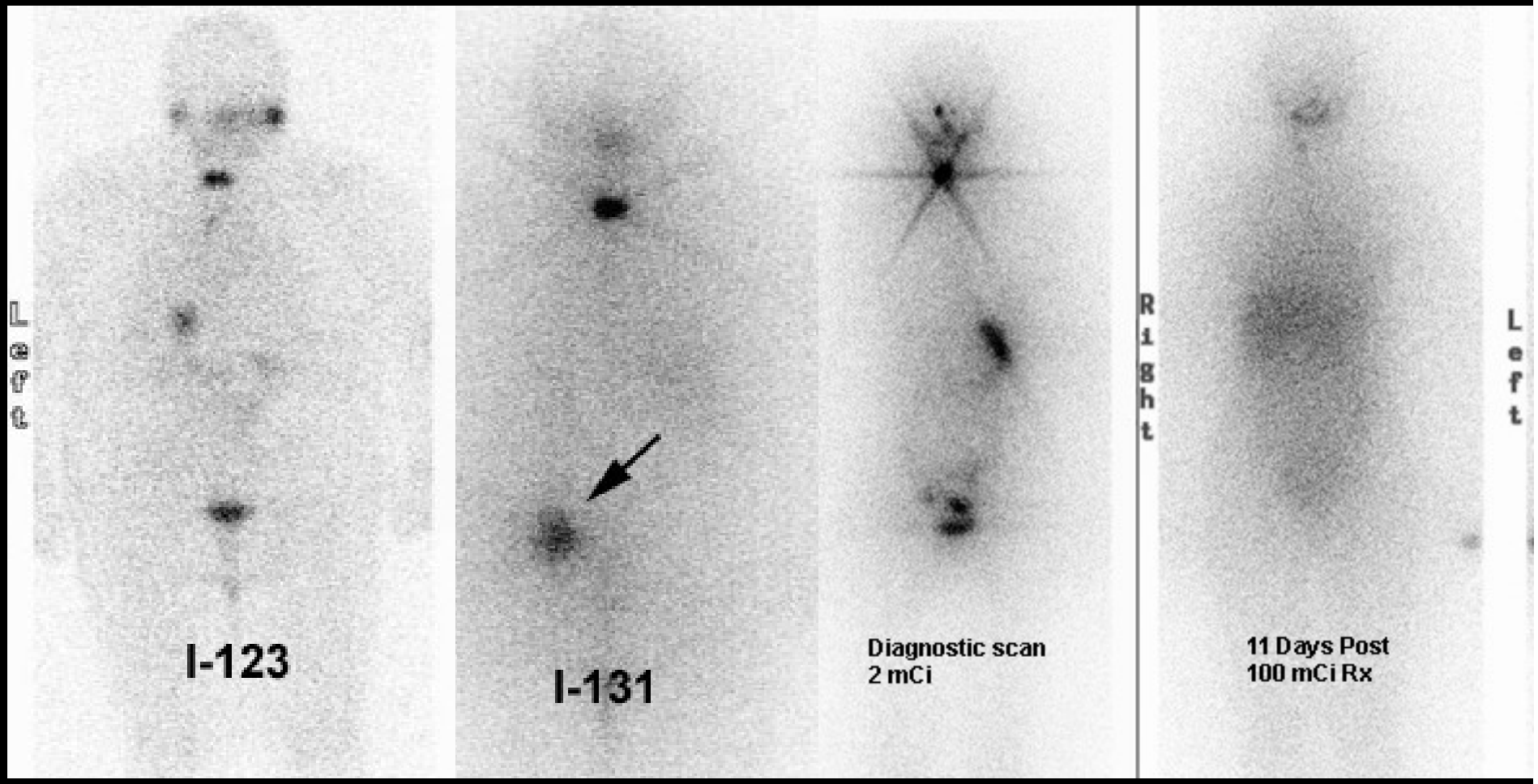

Catecholamine-secreting tumors

- MIBG is an analog of guanethidine, and shares some characteristics with the adrenergic hormone-neurotransmitter, norepinephrine.
- Norepinephrine is synthesized and stored in adrenergic granules, and is secreted by exocytosis. Some of the norepinephrine is secreted and stored again in granules.
- I-123 or I-131 MIBG can enter the metabolic pathway of norepinephrine, in organs with adrenergic innervation, and in organs that process catecholamines for excretion, such as the liver and urinary bladder.

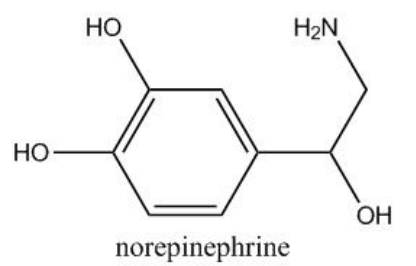

norepinephrine

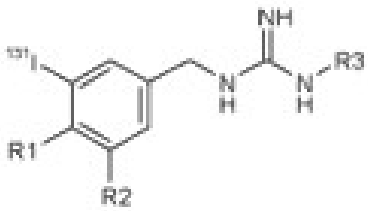

	R_1	R_2	R_3
MIBG	H	H	H
ClBG	Cl	H	H
FIBG	F	H	H
pAIBG	NH_2	H	H
HIBG	OH	H	H
mINGB	H	NO_2	H
pINGB	NO_2	H	H
NHIBG	H	H	OH
HIMBG	OH	OCH_3	H
DHIBG	OH	OH	H
mAIBG	H	NH_2	H
GIBG	CH_4N_3	H	H
GMIBG	$C_2H_6N_3$	H	H
MeIBG	CH_3	H	H

Catecholamine-secreting tumors

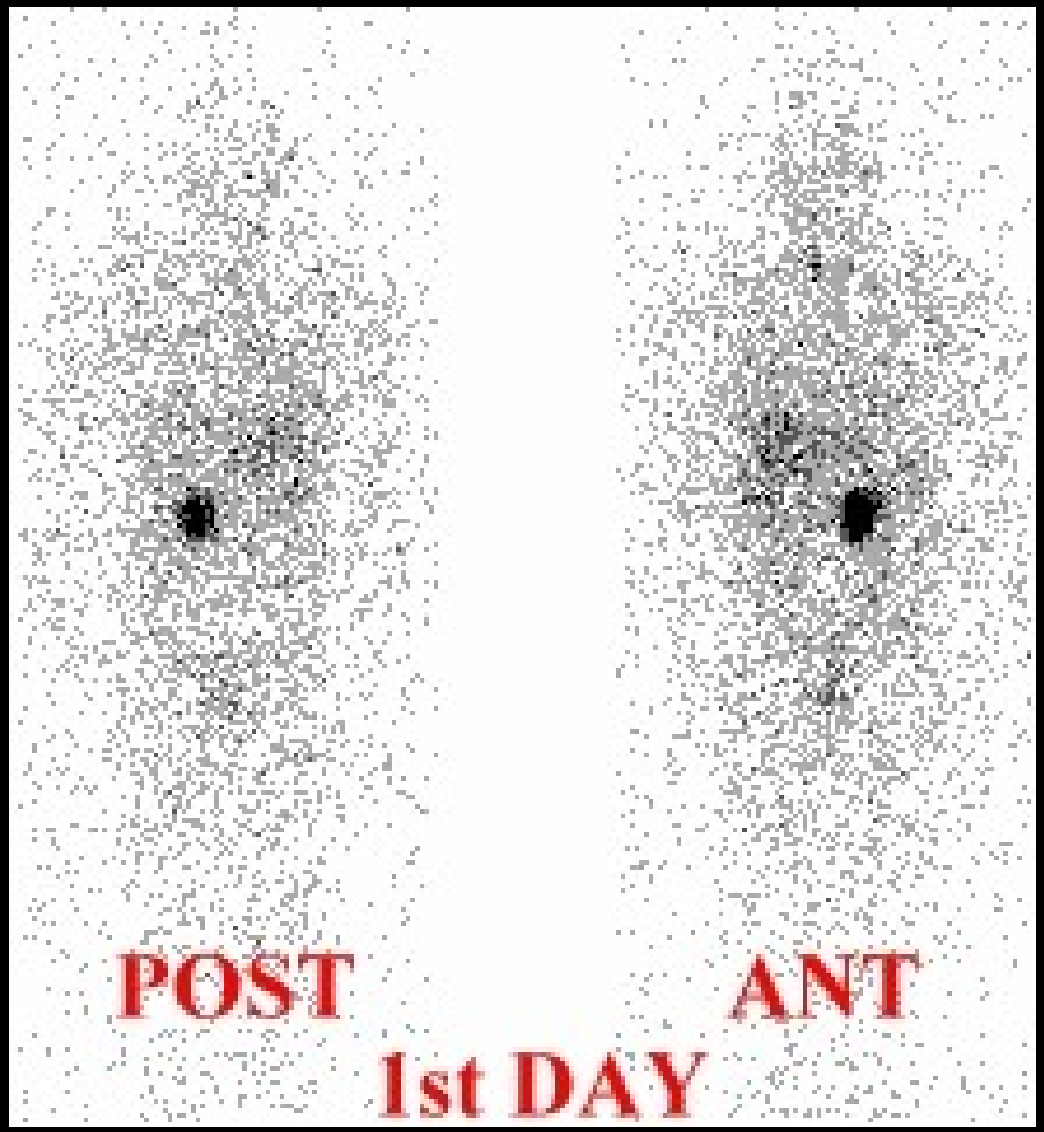

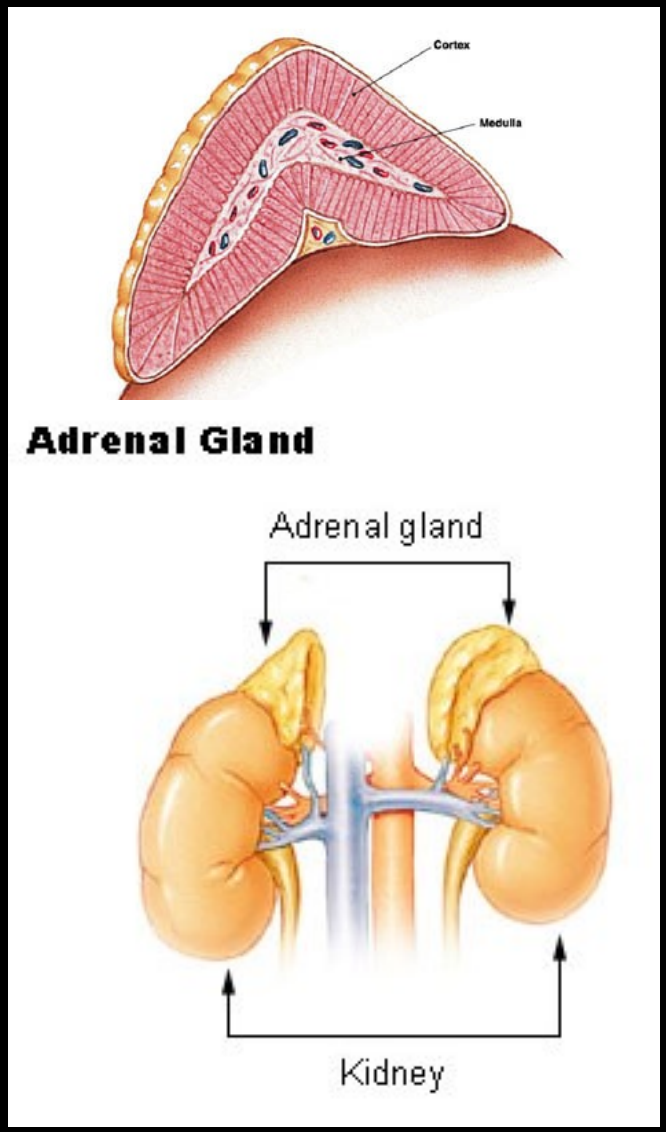

I-131 MIBG study demonstrating high uptake in a left adrenal phaeochromocytoma

Catecholamine-secreting tumors

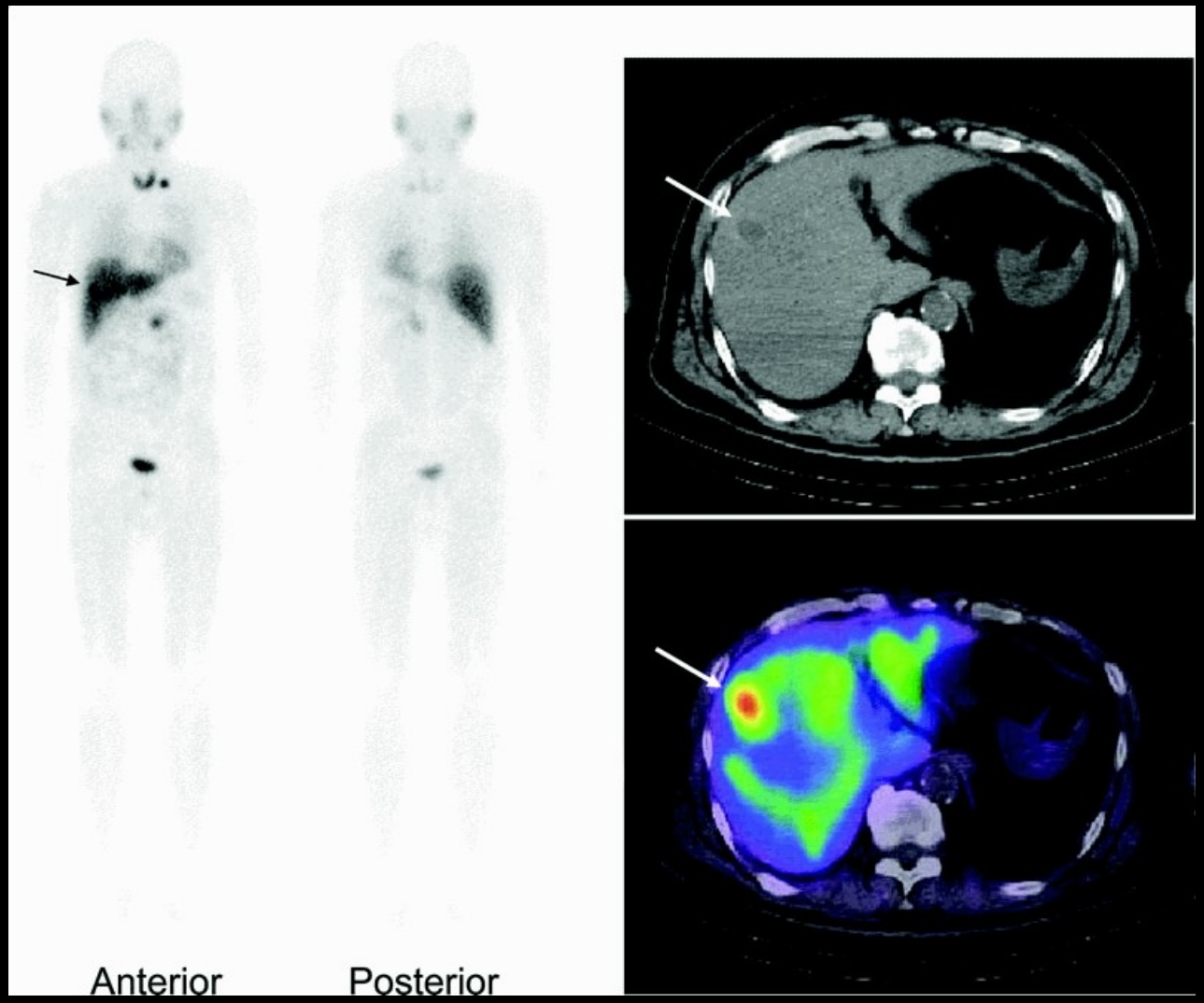

A 47-year-old woman with malignant pheochromocytoma underwent diagnostic low-dose I-123 MIBG scintigraphy. In the planar image, it is difficult to determine whether the abnormal uptake in the right upper abdomen exists in the right rib or in the liver. In the SPECT/CT, it is proved that the abnormal accumulation exists in the liver.

Catecholamine-secreting tumors

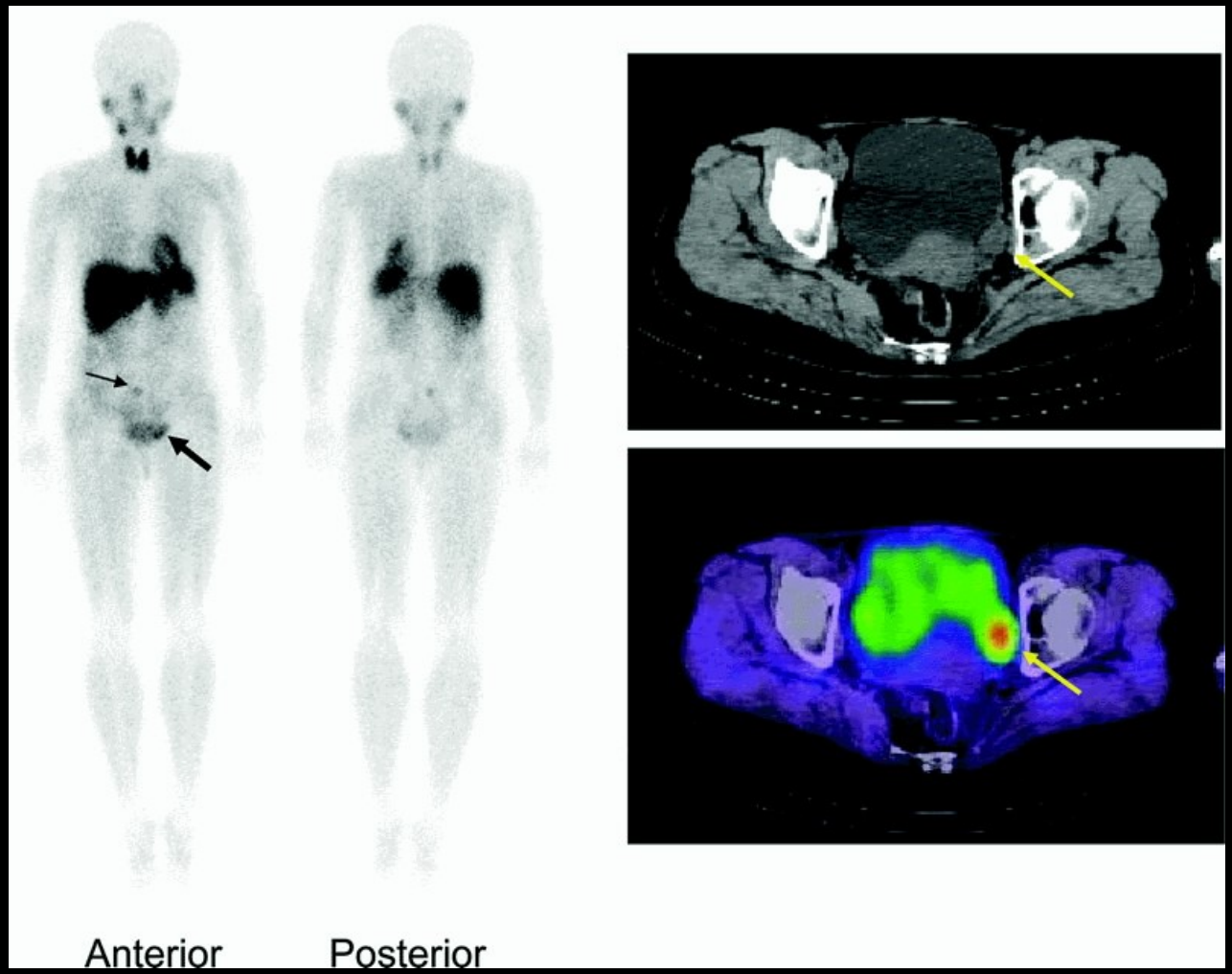

A 54-year-old woman with malignant paraganglioma underwent diagnostic I-123 MIBG scintigraphy. In the planar image, it is easy to point out the abnormal accumulation in the lower abdomen (narrow arrow), however, it is difficult to detect the abnormal uptake beside the bladder (wide arrow) because of physiological accumulation in the bladder. In the SPECT/CT, it is easy to detect the abnormal MIBG accumulation corresponding to the nodular lesion in the left side of the bladder.

Catecholamine-secreting tumors

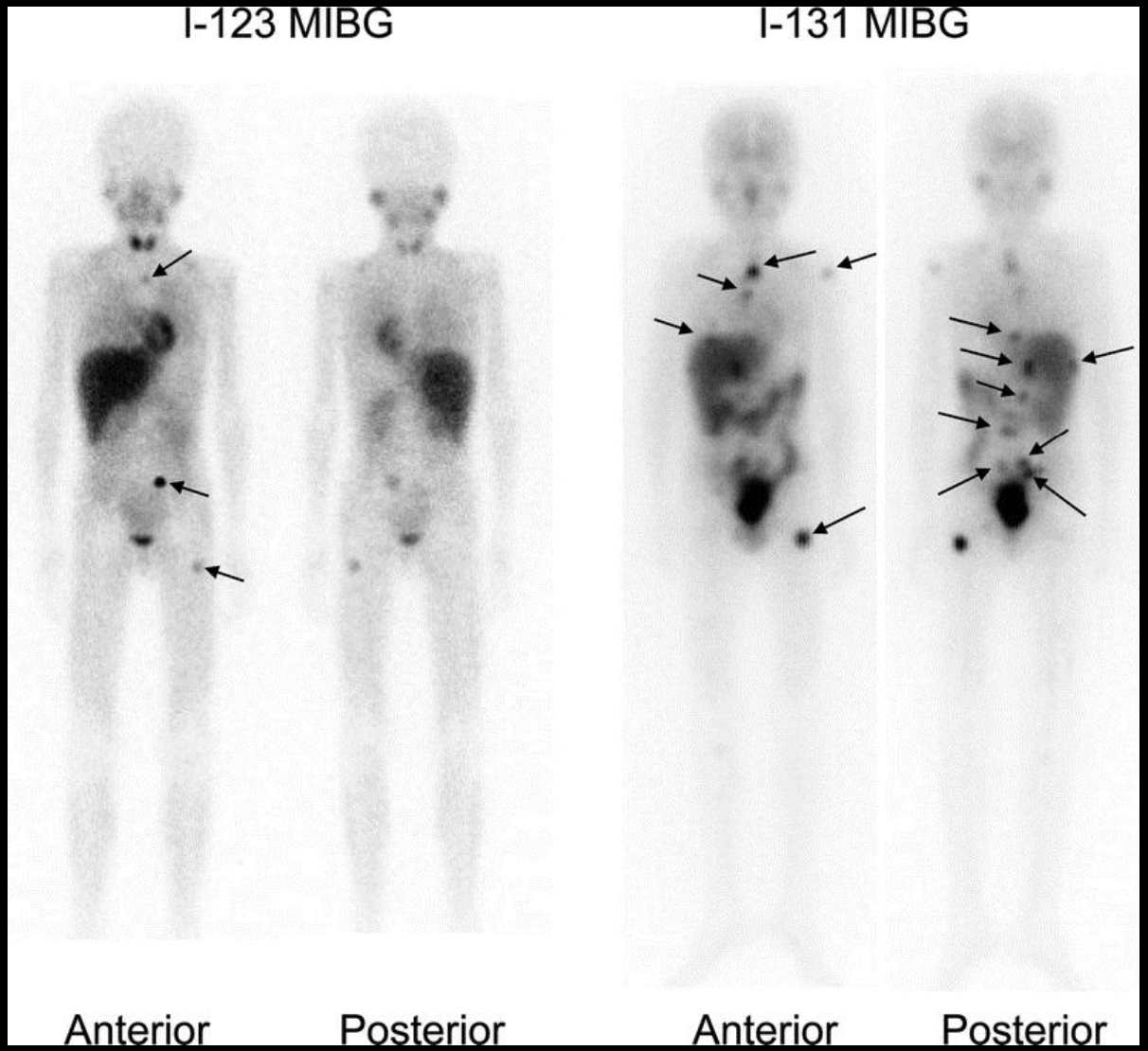

A 10-year-old boy with neuroblastoma underwent 14.8 GBq (400 mCi) of I-131 MIBG therapy. In the planar image with diagnostic I-123 MIBG, only 3 abnormal uptakes were detected in the upper mediastinum, left lower abdomen, and left thigh. In the planar image with therapeutic high-dose I-131 MIBG, total of 13 abnormal uptakes were detected in the left shoulder, mediastinum, vertebrae, upper and lower abdomen, and in the left thigh.

Somatostatin receptor imaging

- SOMATOSTATIN is a small peptide hormone of 14 amino acids.
- OCTREOTIDE is a somatostatin analogue consisting of eight amino acids. Positive in islet cell tumors, carcinoids, paraganglionomas, gastrinoma, medullary thyroid carcinoma, small cell lung cancers (NEUROENDOCRINE TUMORS).
- Might help in patient selection for clinical trails with somatostatin analogs in the treatment of neuroendocrine cancers.

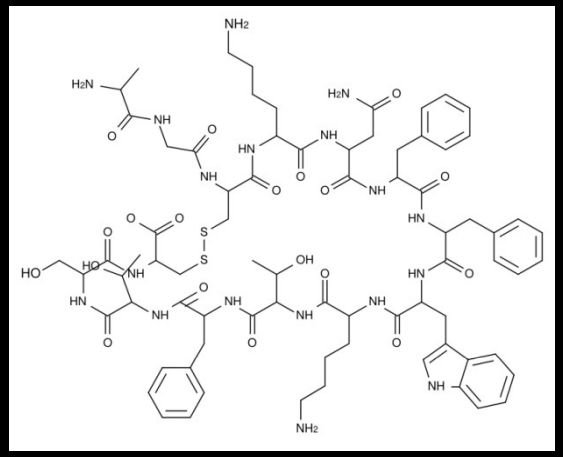

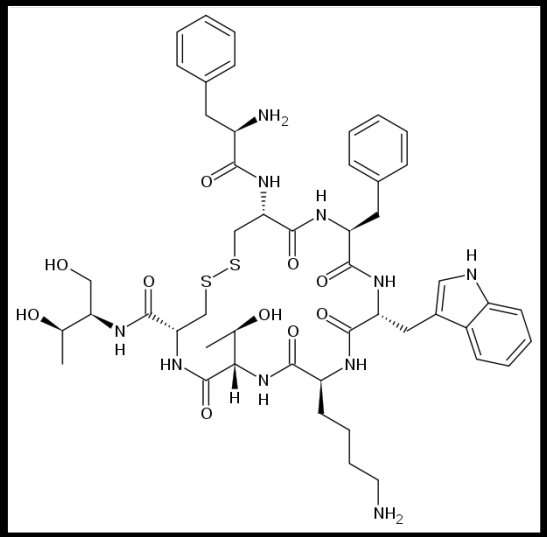

Peptide receptor targeting

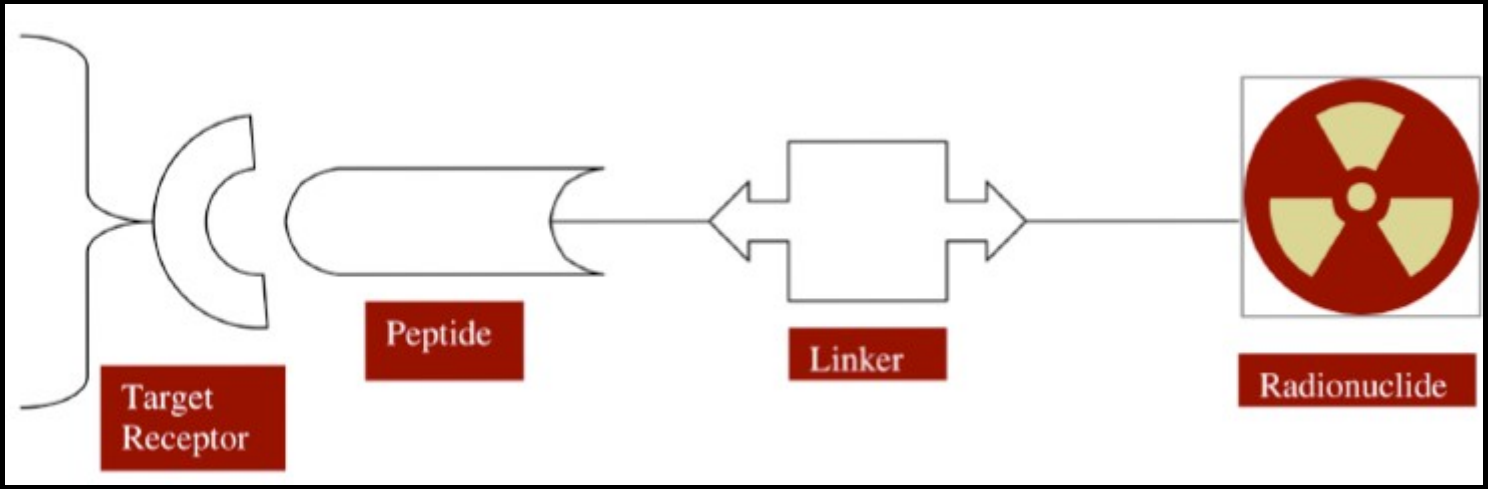

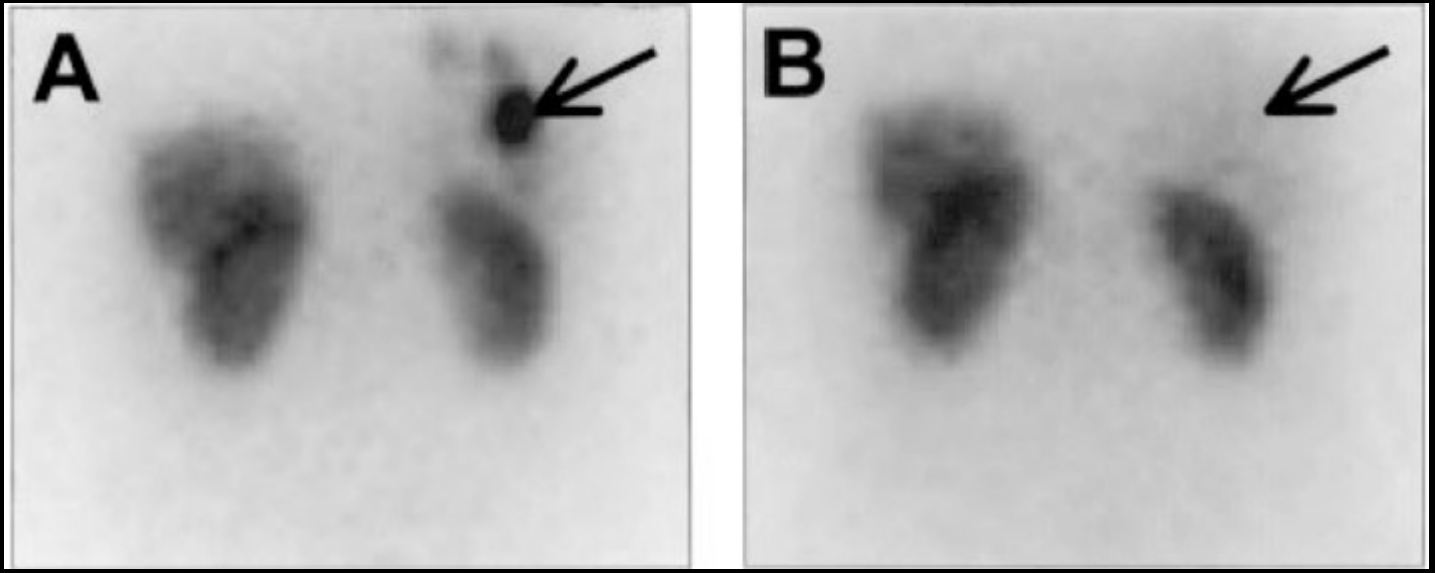

In-111-DTPA-octreotide

Radioimmunodetection (CEA-Scan)

Intact Antibody $F(ab')_2$ Fragment Fab' Fragment CEA-Scan

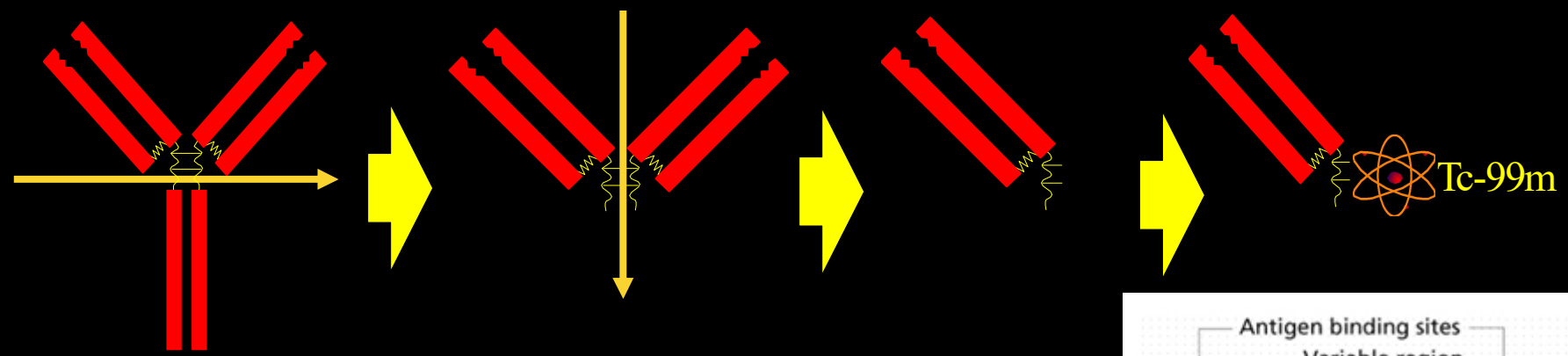

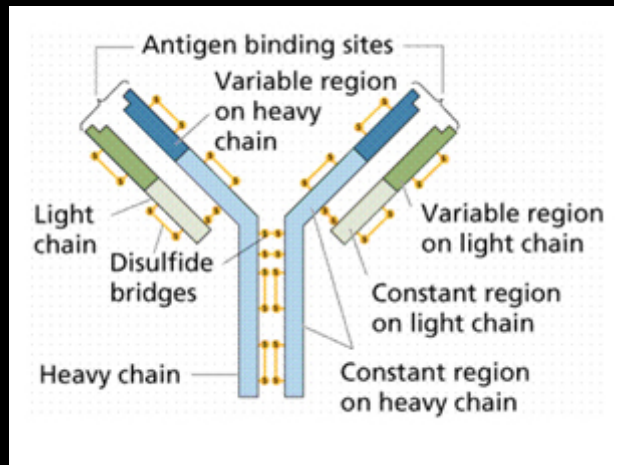

What is CEA-Scan?

- A murine monoclonal antibody Fab' fragment.
- When labeled with technetium-99m provides imaging of CEA expressing tumors.

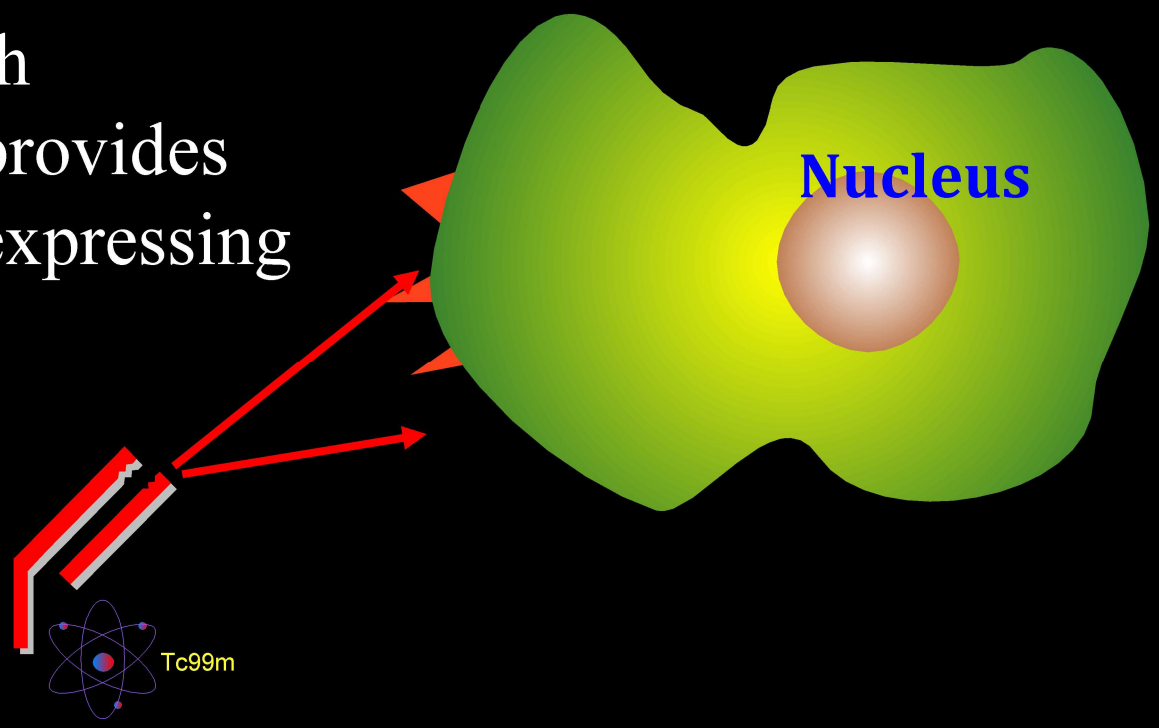

Radioimmunodetection (CEA-Scan)

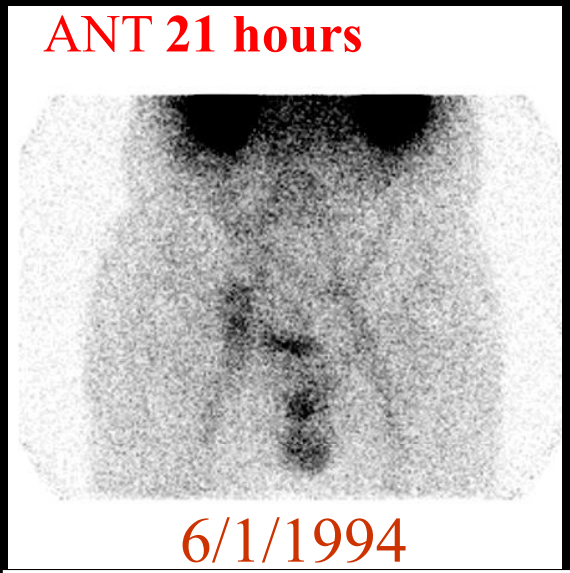

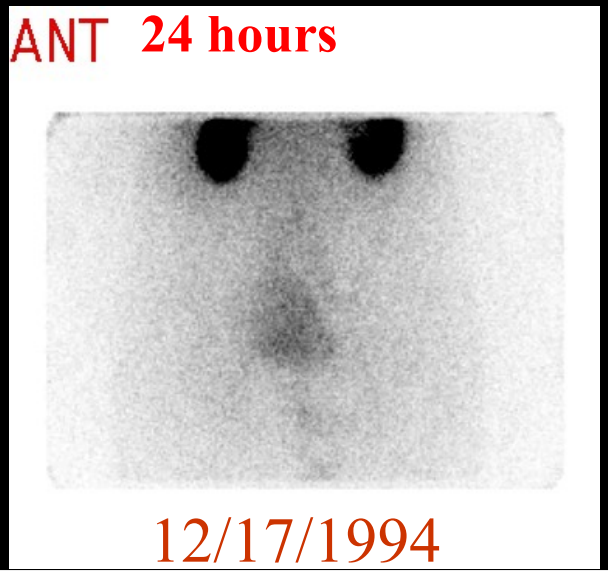

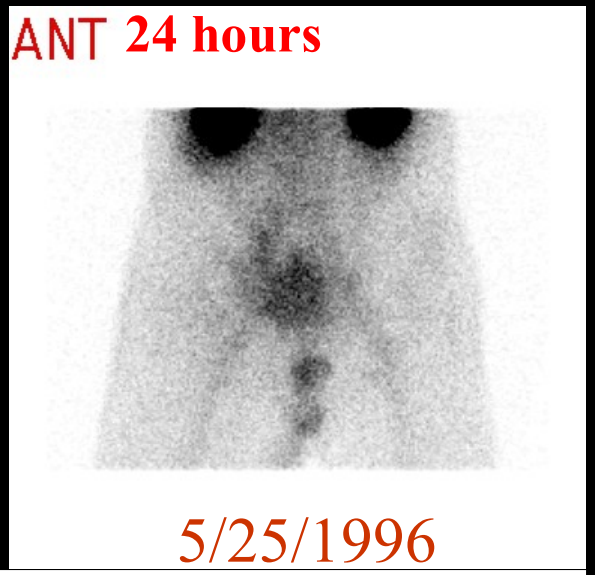

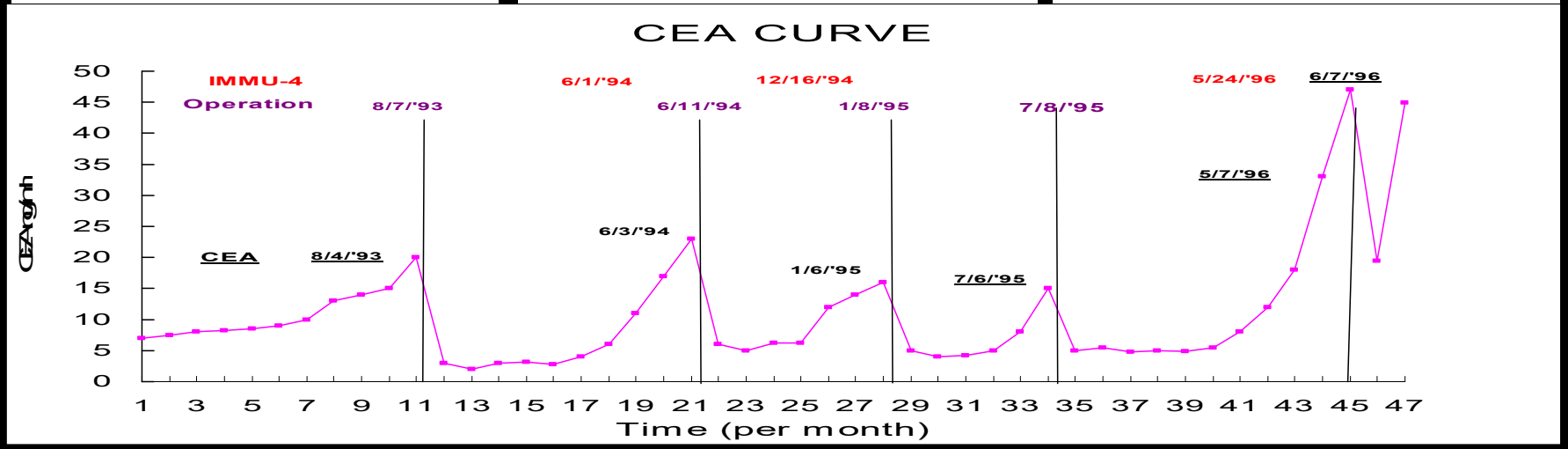

Overview of tumor scintigraphy

- Tumor-type specific radionuclides
  - –Thyroid cancer: I-131or I-123
  - –Catecholamine-secreting tumors: I-131 or I-123 MIBG
  - –Somatostatin receptor imaging
  - –Radioimmunodetection
  - –PET (F-18 DOPA, Ga-68 DOTA peptides, etc.)
- Non-specific tumor imaging radionuclides
  - –Ga-67
  - –Tl-201
  - –Tc-99m sestamibi
  - –Lymphoscintigraphy
  - – PET (F-18 FDG, C-11 acetate, etc.)

Ga-67 scan

- Mechanism of tumor localization
  - Adequate blood supply
  - Vascular premeability
  - Specific tumor-associated transferrin receptor
  - Tumor metabolism
- Biological behavior: similar to ferric ion
- Binding to iron-binding molecules, including transferrin, lactoferrin, ferritin, siderophores

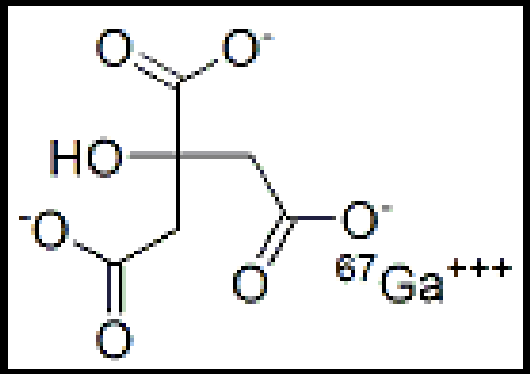

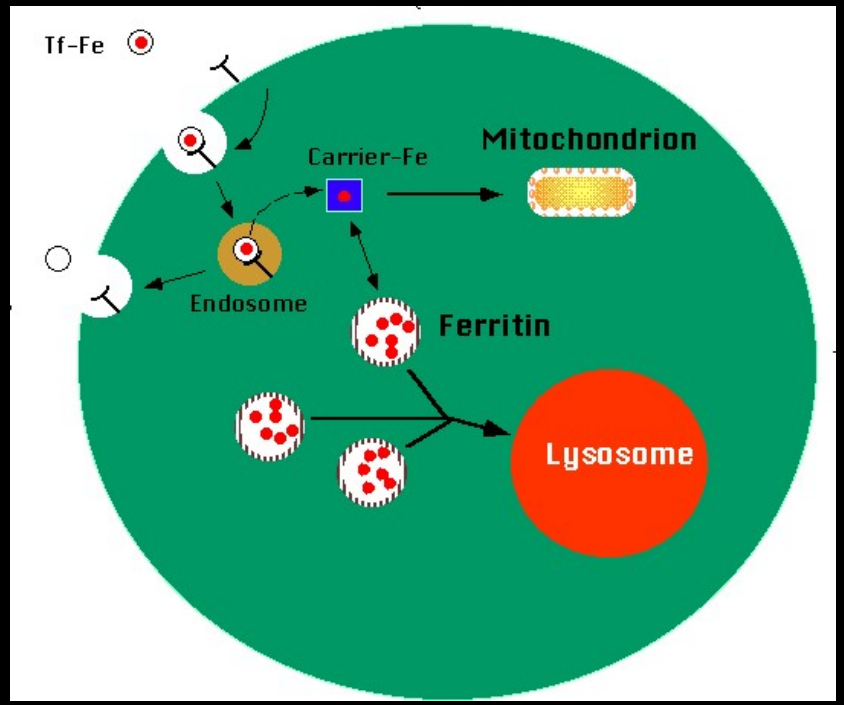

Ga-67 scan

Normal Gallium Scan

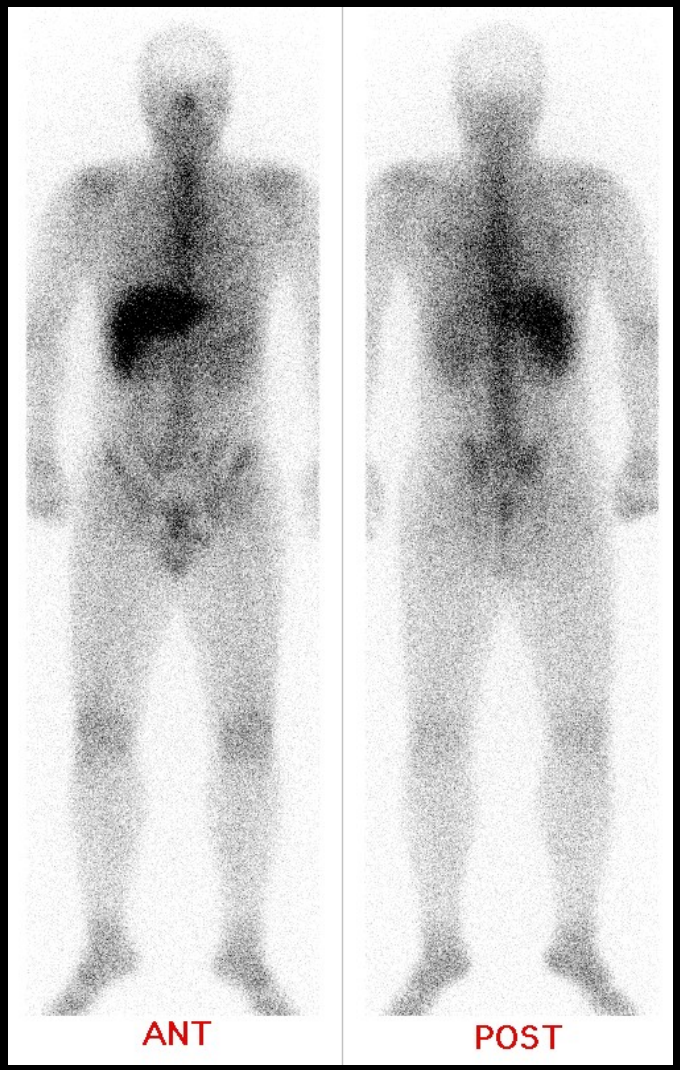

Lymphoma

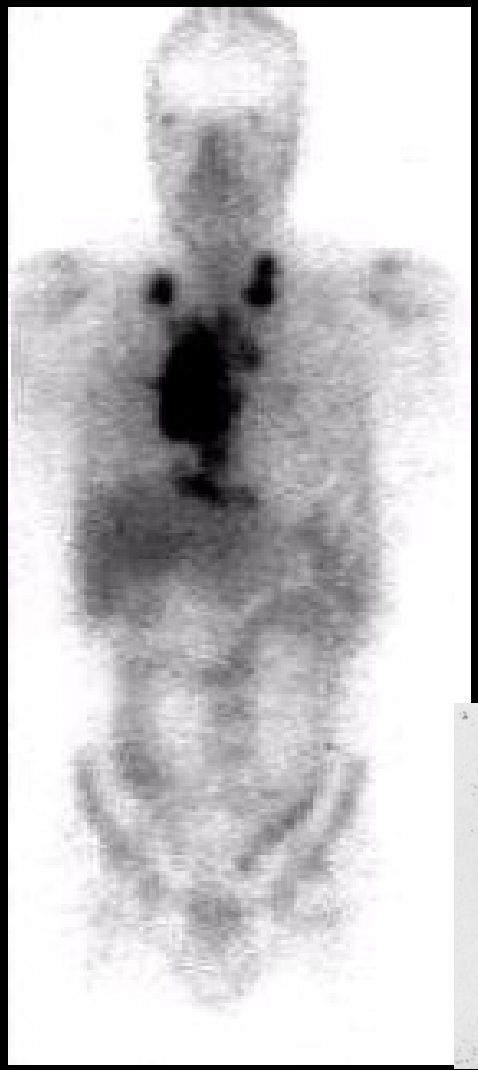

Sarcoidosis

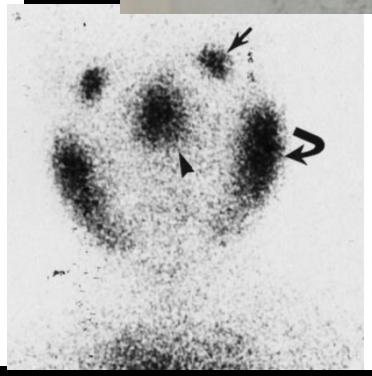



Tl-201 chloride tumor scan

- Thallium-201: a potassium analog
- Factors determining tumor cell uptake:
  - Blood flow
  - Tumor viability (Sodium-potassium ATPase system)
  - Tumor type (Kaposi's sarcoma, gallium-negative)
- Clearance by kidney, half-life: 73 hrs

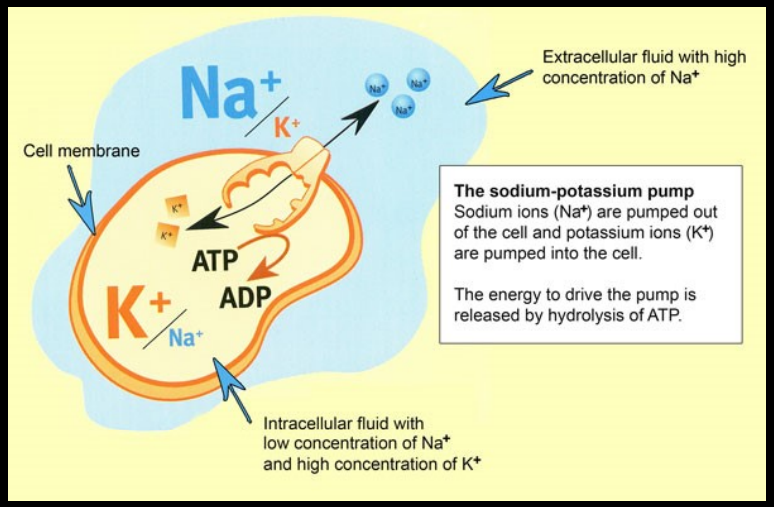

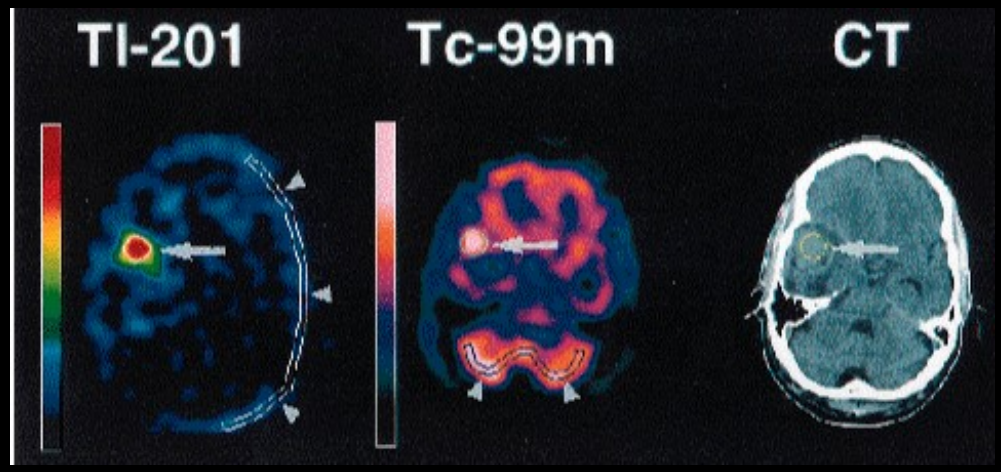

Tl-201 chloride tumor scan

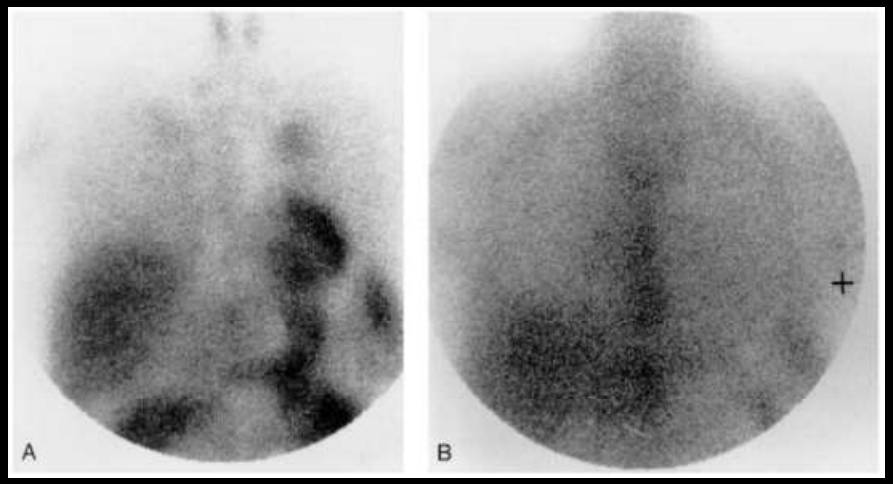

AIDS patient with Kaposi's sarcoma of the skin
(A) Tl-201 (+)
(B) Ga-67 (-)
Focal pulmonary Kaposi's sarcoma in left upper lobe

AIDS patient with pneumocystic carinii pneumonia.
(A) CXR: bilateral hilar congestion and diffuse interstitial markings
(B) Ga-67: increased uptake involving both upper lung zones with less uptake in lower lung zones

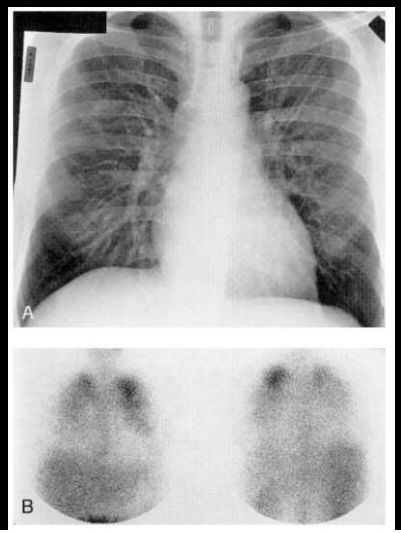

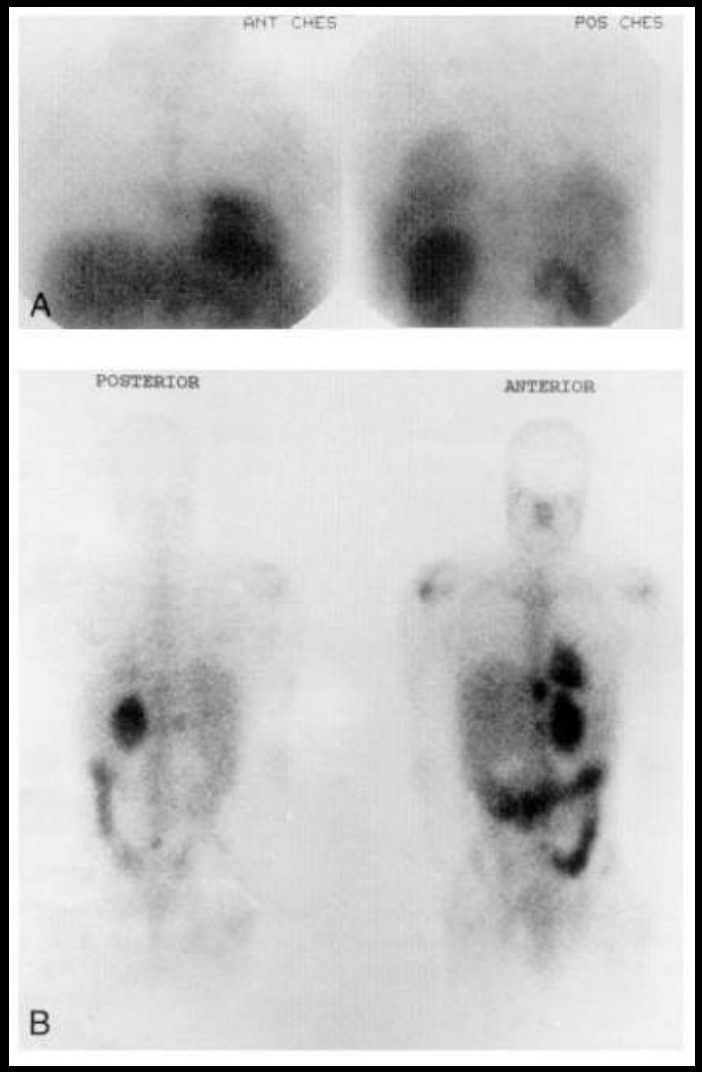

Cardiac lymphoma.
(A) Tl-201: a defect in the anterior wall
(B) Ga-67: heart, left lobe of liver, left epigastric mass

Tc-99m sestamibi

- A lipophilic cationic complex
  - tumor imaging characteristic similar to Tl-201
  - Localize in the mitochondria
- Factors determining tumor cell uptake:
  - Blood flow
  - Tumor viability
  - Tumor type
  - Lipophilic cation
- brain tumors, breast cancer, primary bone or soft tissue sarcoma

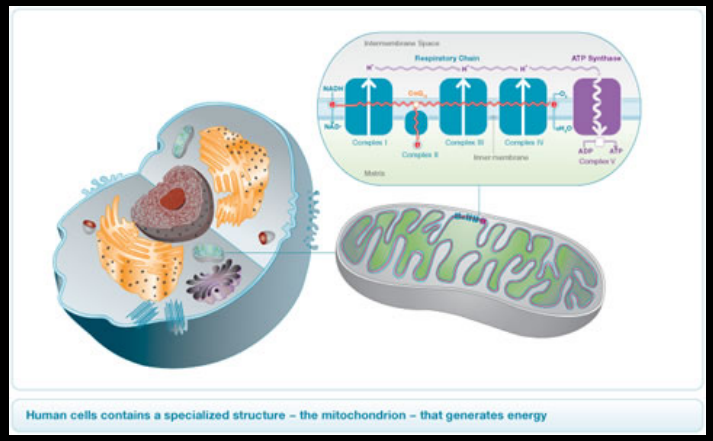

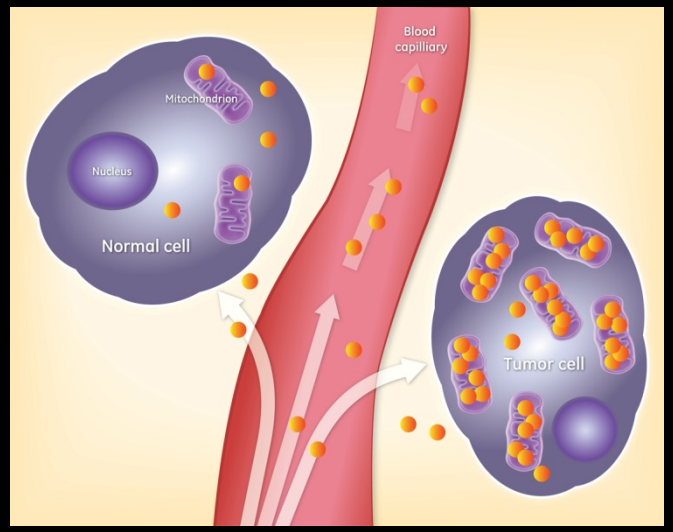

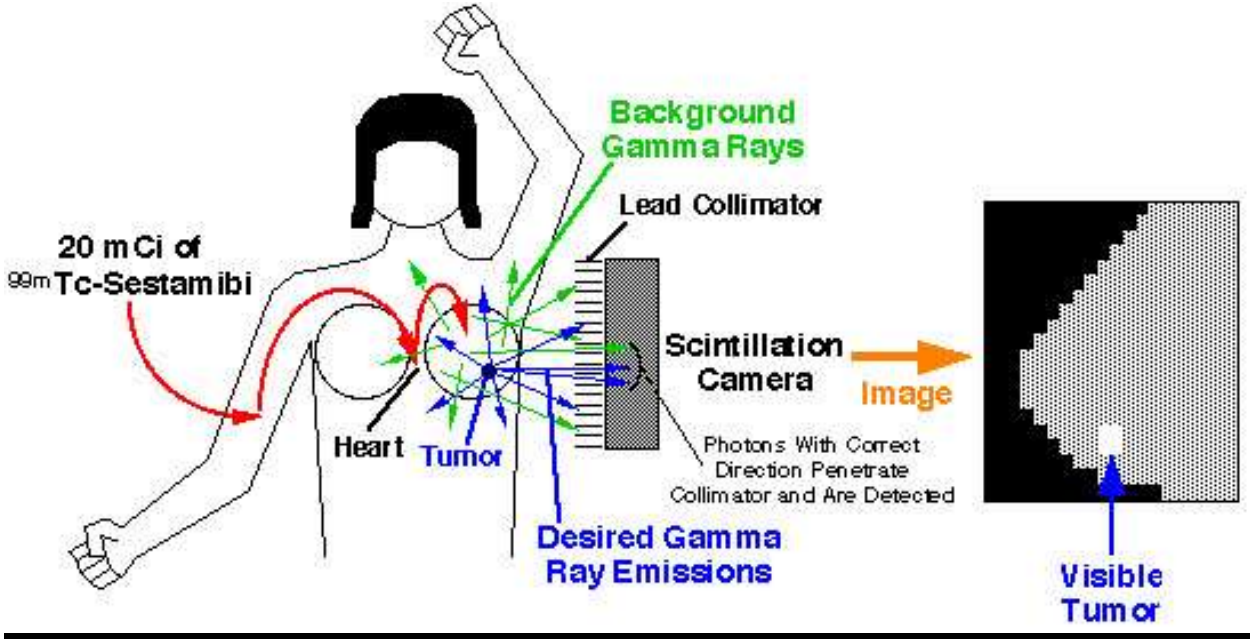

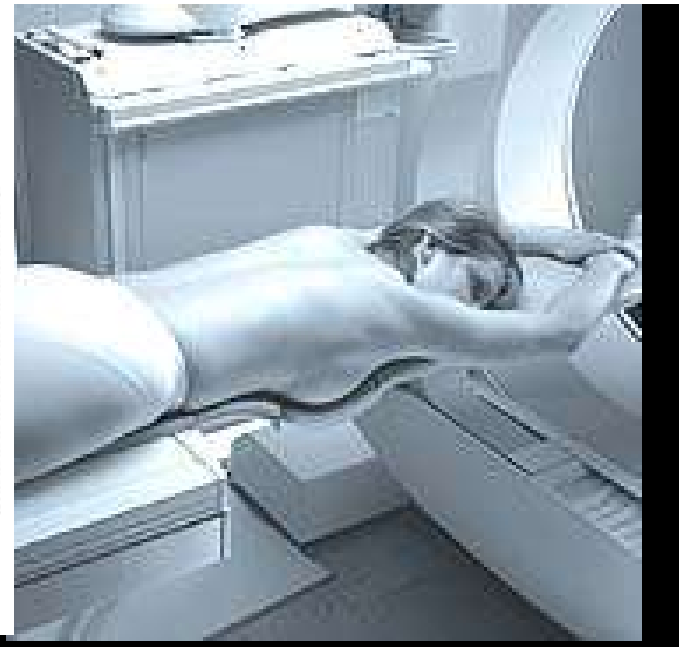

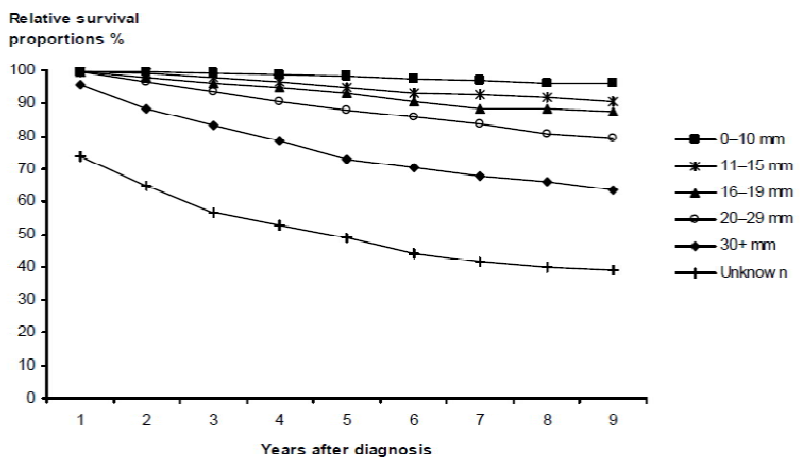

Breast cancer relative survival by size of cancer

Sensitivity = 85%; specificity = 89%
< 15 mm sensitivity = 55%

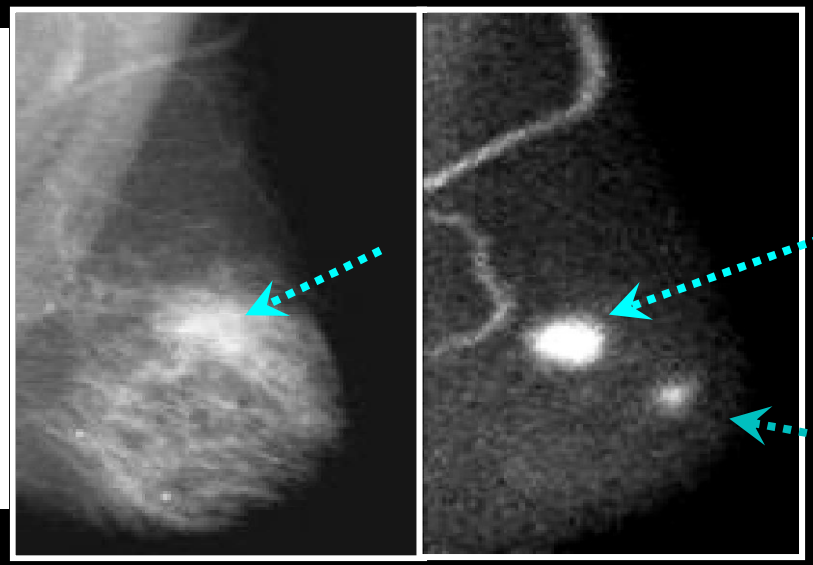

20 mm cancer lesion seen on both Mammo & MBI

Additional 10mm cancer lesion seen only on MBI

Mammography MBI

From... LARGE system with limited ability to detect 15-20mm breast lesions
To.... SMALL system with significant ability to detect ~5mm breast lesions

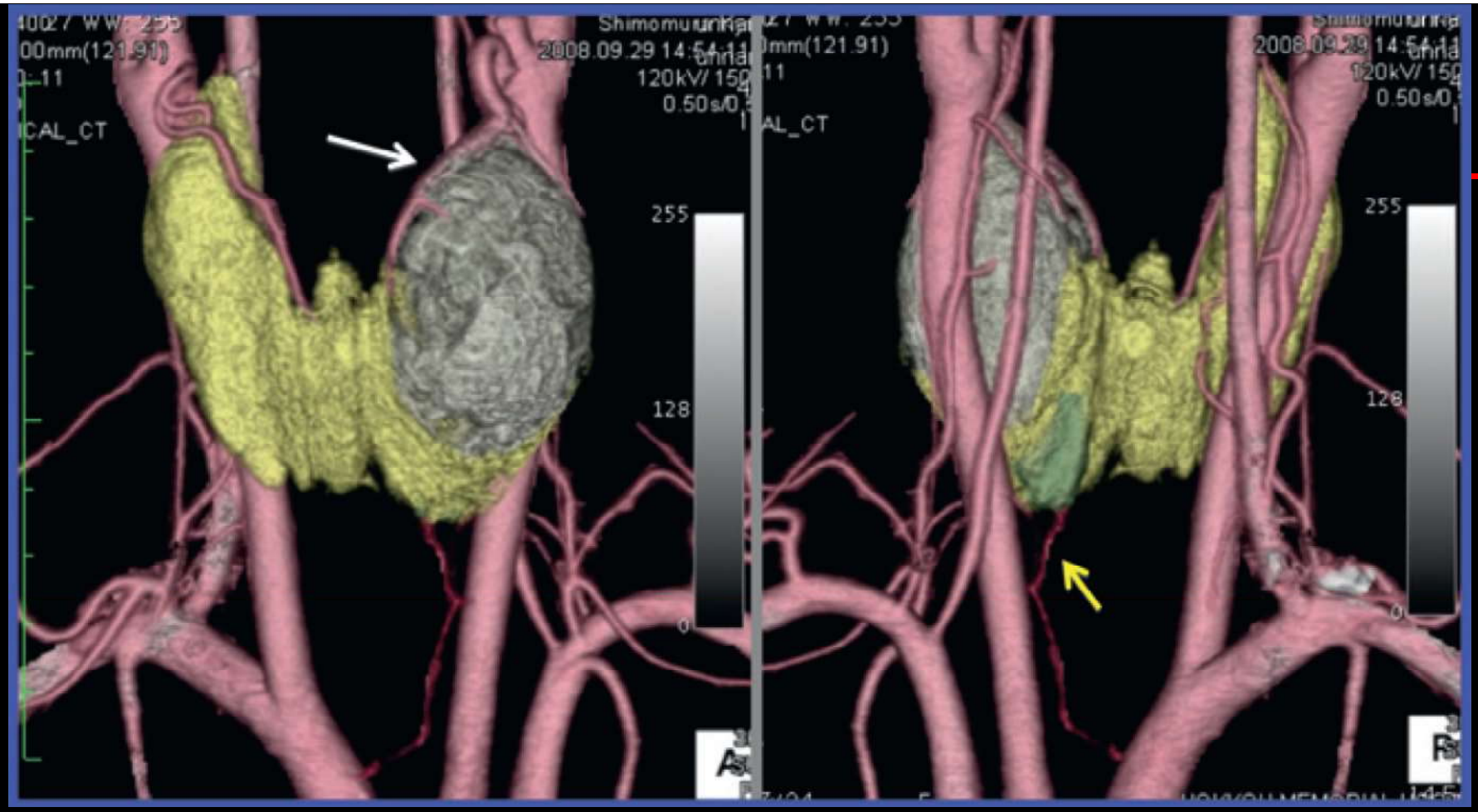

FIGURE 41. 3D volume rendering of CT of arteries in the neck, thyroid gland, and enlarged parathyroid gland from the anterior (left) and posterior (right) projection in a female patient with a parathyroid adenoma and follicular adenoma of the thyroid. Normal thyroid is seen in yellow. The gray area is a thyroid adenoma with a superior thyroid artery feeding vessel. In the posterior view, the parathyroid adenoma is light green and a feeding vessel is visualized coming off the internal mammary artery from the brachiocephalic trunk.

Lymphoscintigraphy

- Sentinel lymph node.

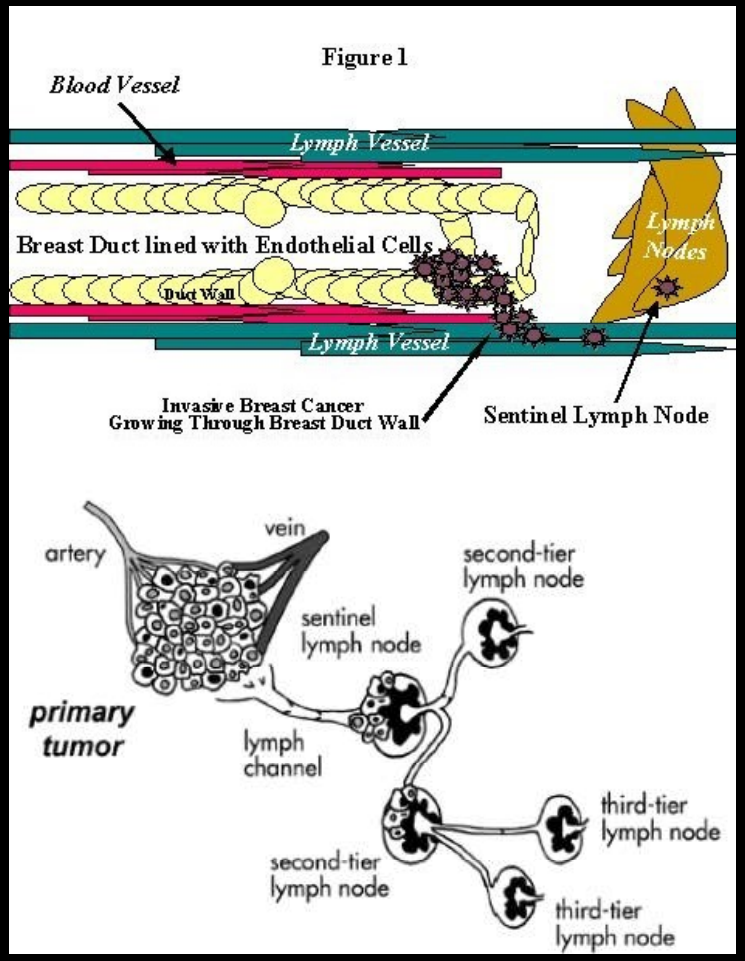

Lymphoscintigraphy

- Tracer injected into the tumor or surrounding tissue to identify the nodes receiving the lymphatic drainage of that tumor
- Tracers:
  - ^{99m}Tc-sulfur colloid,
  - ^{99m}Tc-phytate
- Injection type:
  - intradermal
  - Peritumoral
  - periareolar
- To localize the proximal or initial portion of the lymphatic chain, efferent from the tumor, for subsequent surgical excision and histologic diagnosis

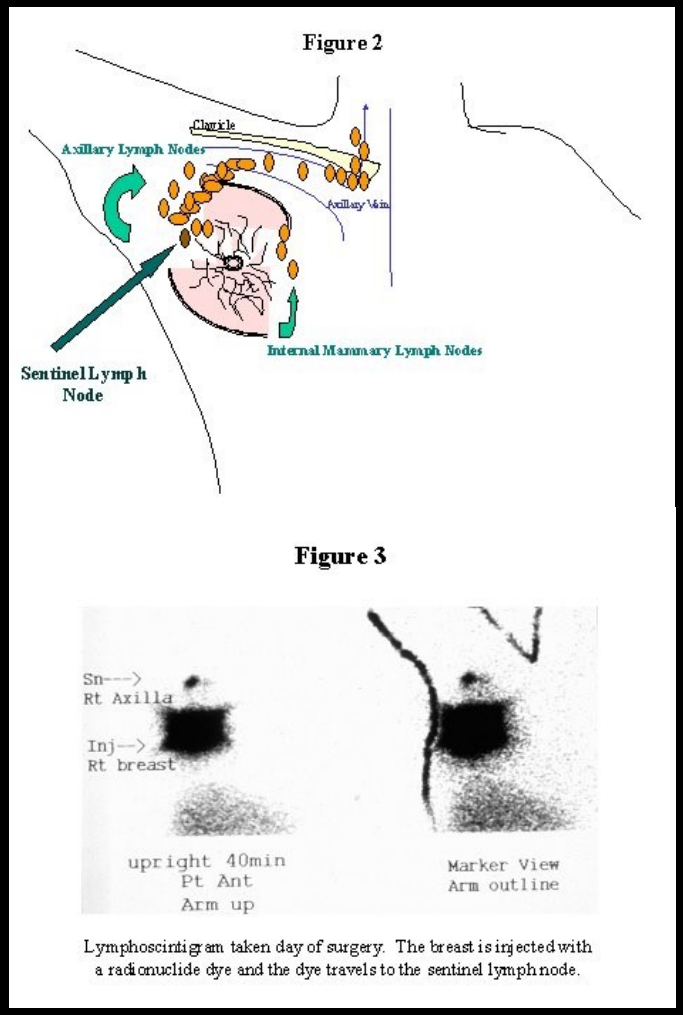

Lymphoscintigram taken day of surgery. The breast is injected with a radionuclide dye and the dye travels to the sentinel lymph node.

Positron Emission Tomography



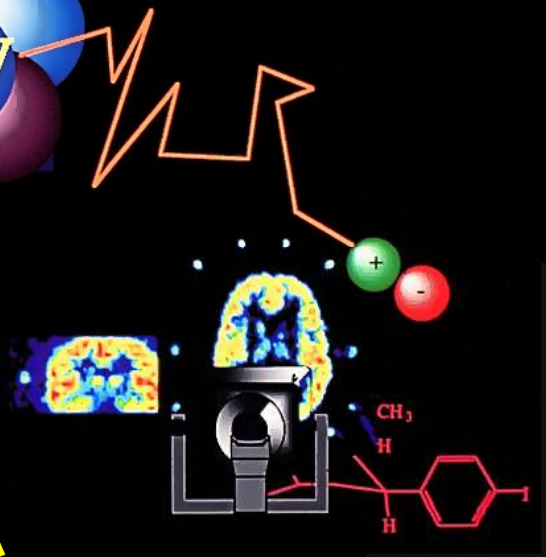

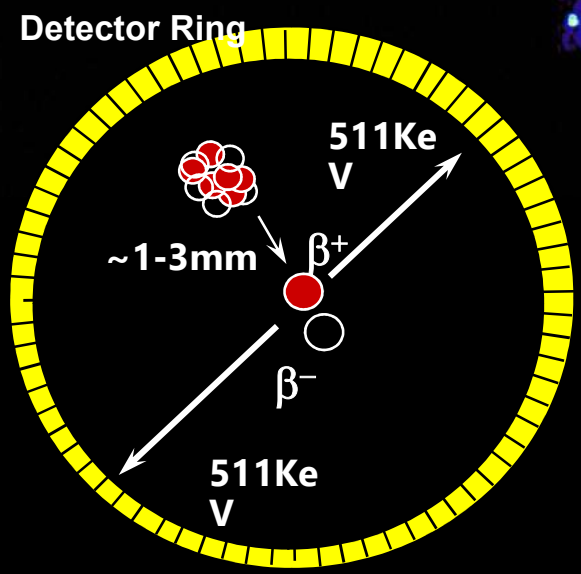

Positron Emission Tomography

Cyclotron: Produces proton rich radioactive isotopes

Radioisotopes:	F-18	C-11	N-13	O-15	Ga-68
half life:	2 hrs	20 min	10 min	2 min	68 min

Radiochemistry: less than 3 half lives

Radiolabelled Imaging Compounds:
FDG, FLT, FHBG, FESP, F-, NH3, O2, CO2,
many C-11 methylated organic compounds

PET TRACERS in Oncology

DNA Synthesis
[^{18}F]FLT, [^{18}F]FUdR…

Cell membrane
[^{11}C]choline, [^{18}F]FECh...

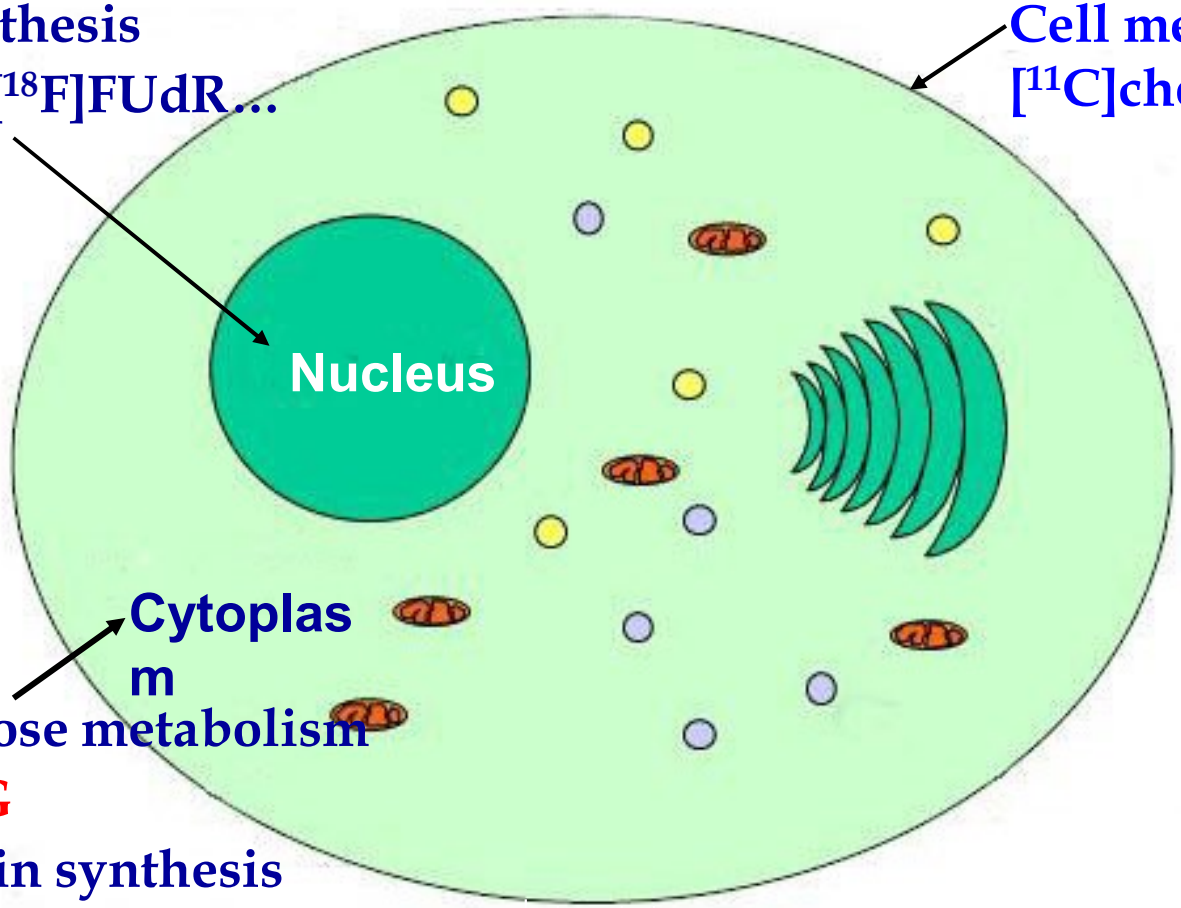

(A)Glucose metabolism
[^{18}F]FDG
(B)Protein synthesis
[^{18}F]FET, [^{11}C]Methionine …
(C)Biosynthesis
[^{11}C]acetate…

Tumor marker
Specific ligand, e.g. [^{18}F]FES

[F-18]去氧葡萄糖的合成

[18F]FDG

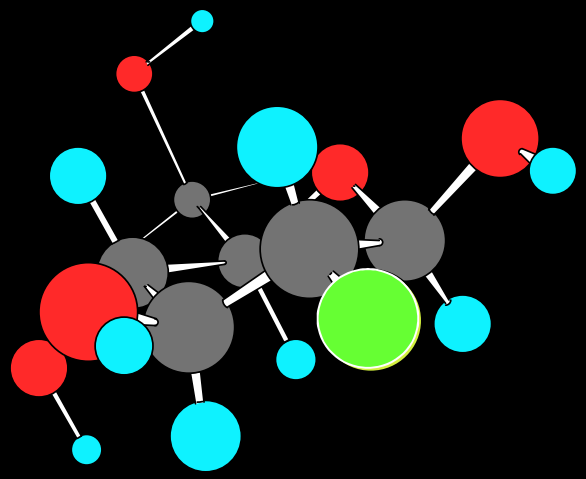

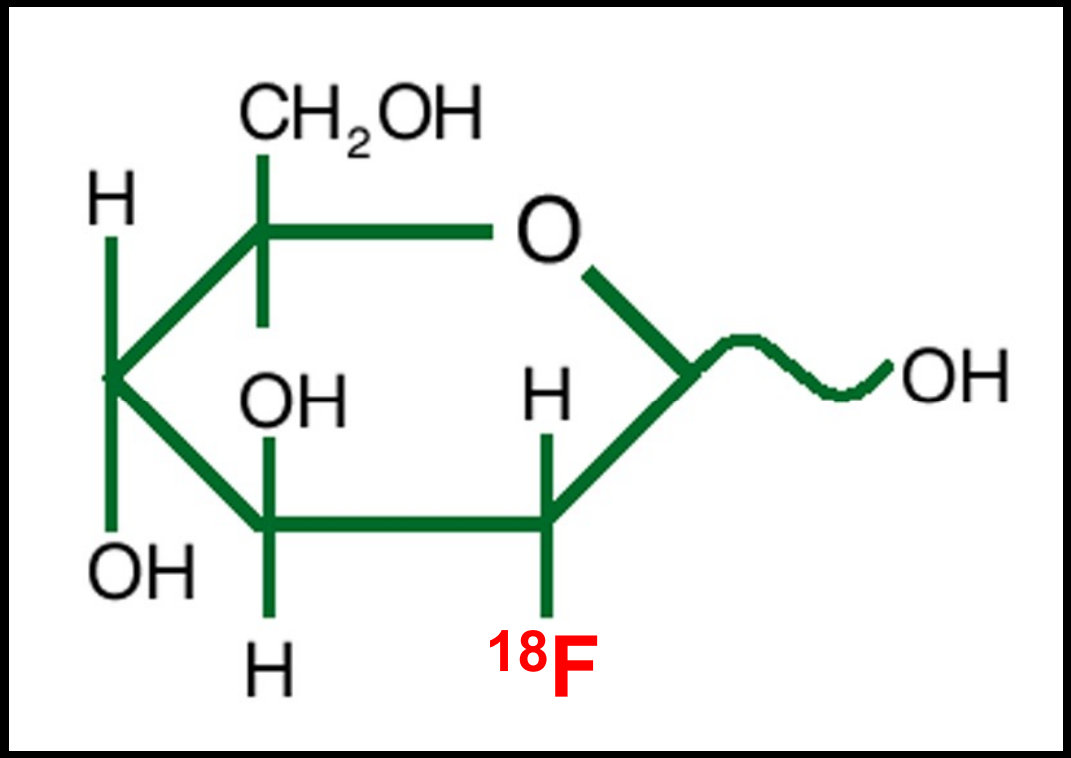

F-18去氧葡萄糖

氟化葡萄糖(FDG)代謝

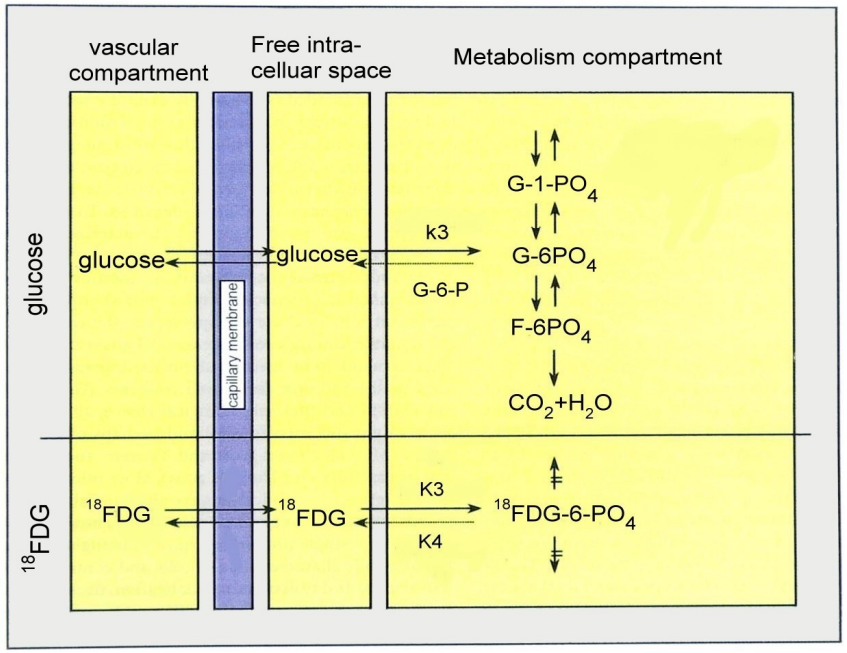
vascular compartment
Free intra-celluar space
Metabolism compartment
glucose
capillary membrane
glucose
glucose
k3
G-6-P
G-1-PO4
G-6PO4
F-6PO4
CO2+H2O
18FDG
18FDG
18FDG
K3
K4
18FDG-6-PO4

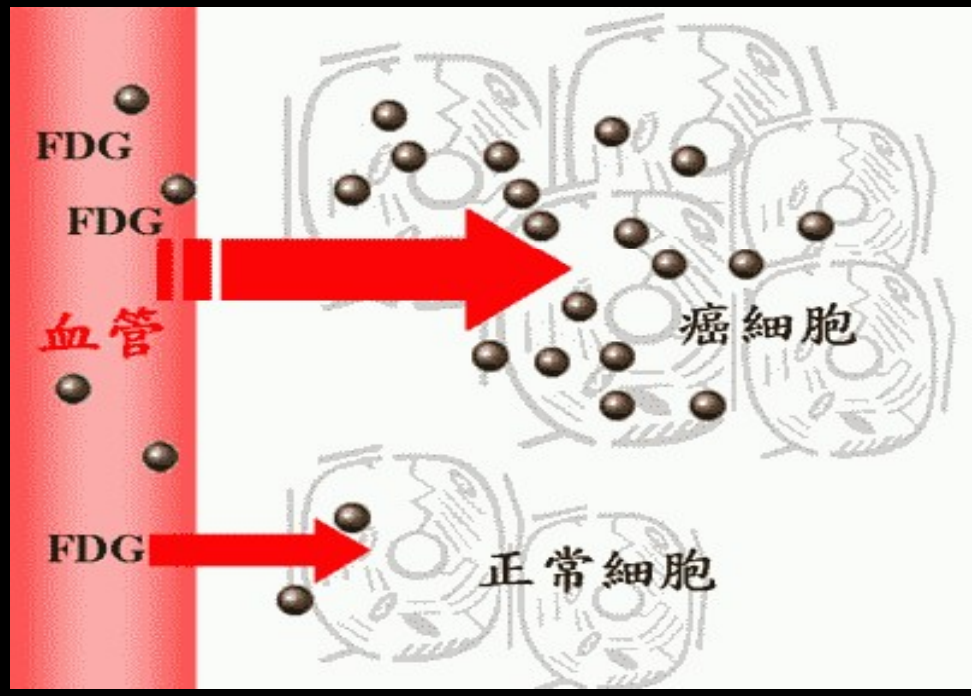
FDG
FDG
血管
FDG
癌細胞
正常細胞

Scanning Procedure

1.Radiopharmaceuticals

2. Injection of radiotracers



3. Scanning

4. Interpretation

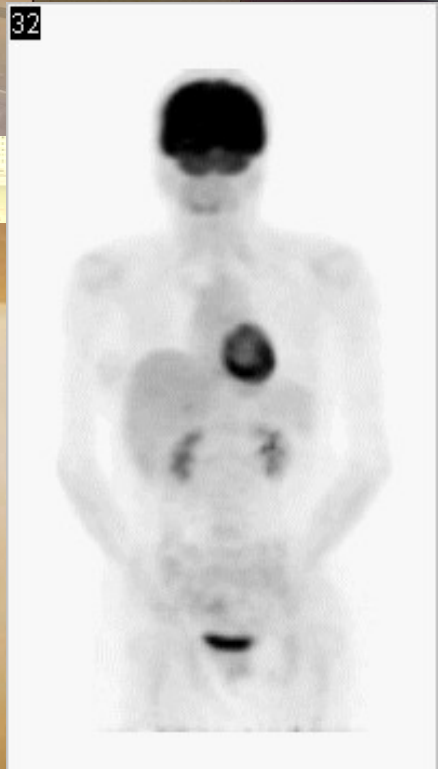

FDG PET vs. Ga-67 scan

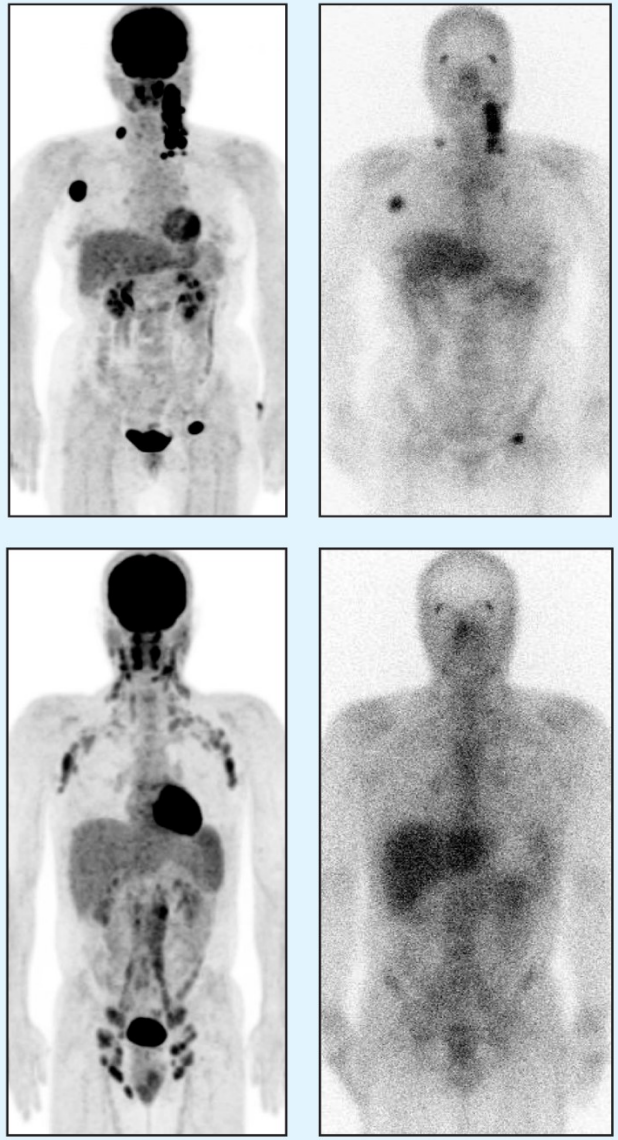

PET Ga-67 scan

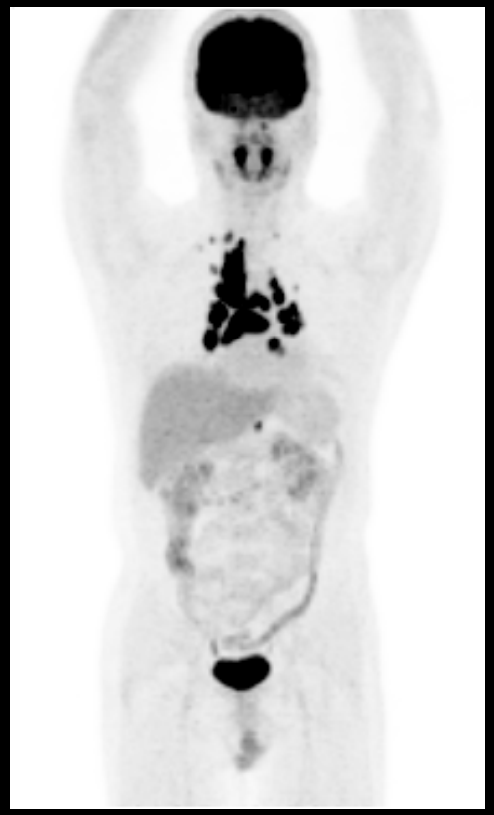

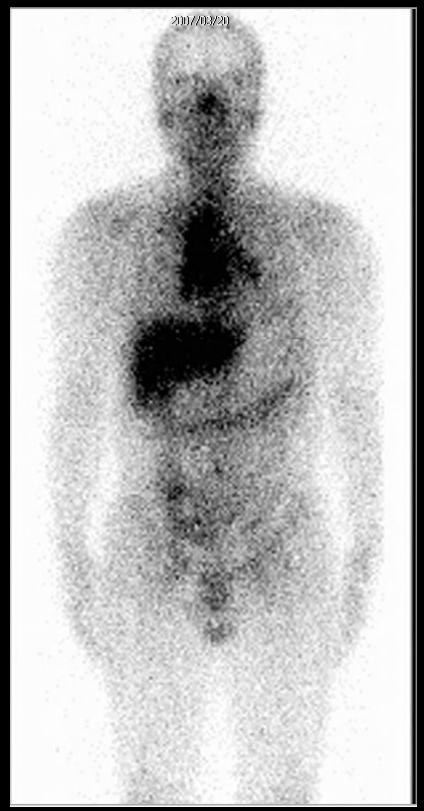

2007/03/09 **2007/03/23**

FDG PET vs. I-131 scan

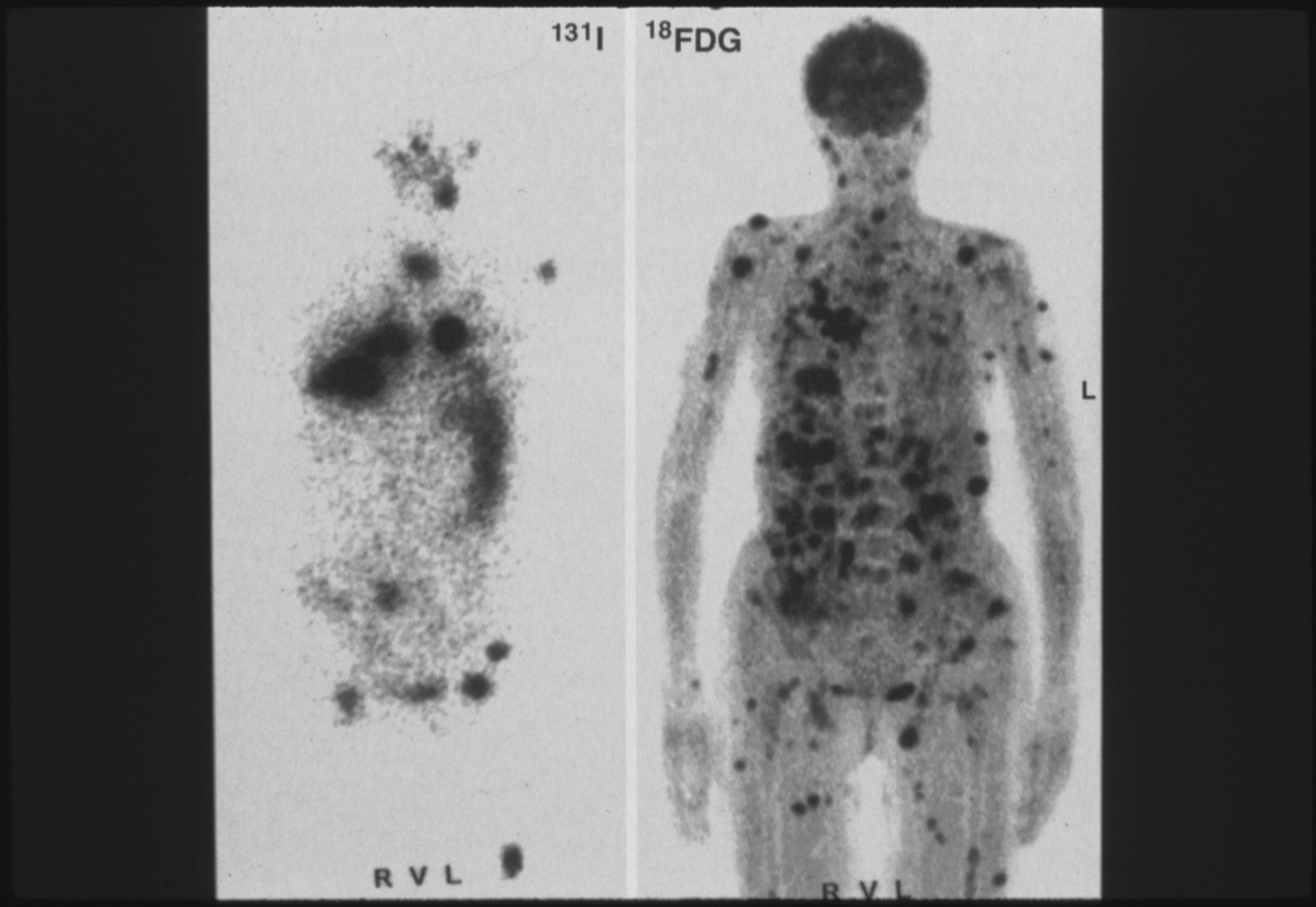





中華民國

白色巨塔犯的錯
正子掃描可預防

不再看走眼

掃描就是利用癌細胞這種特性來找出癌症所在。不論是食道癌還是肺癌，歐、美、日現代醫療的標準做法，都已經把正子斷層掃描列入術前診斷中，因為光有傳統電腦斷層掃描是不夠的。

以佐佐木先生這類食道癌患者來說，傳統檢查下發現沒有轉移病變者當中，約有兩成可進一步經由正子斷層掃描發現異常，而必須考慮改變手術方法，甚至以化學藥物治療或放射線治療等方式取代。

針對佐佐木先生的肺部陰影，正子掃描可以提供額外診斷資訊來澄清肺部病變的真正原因，一旦正子掃描呈現陰性反應，幾乎可以排除食道癌轉移肺部的可能性。即使正子斷層掃描無法百分之百區分那個病變是癌症還是炎症，加上定量分析後，應該能更進一步確認是否已造成轉移。

財前醫師的肺癌就更有討論空間。他的肺癌組織型態是腺癌，屬於所謂非小型細胞癌症（台灣的肺癌當中八十八%屬此類），是美國在一九九八年第一個通過保險給付進行正子掃描檢查的癌症，也就是說正子掃描可協助臨床醫師做正確的診斷，且保險公司支付這項檢查費用。

戲裡所有醫師都認為財前的肺癌是第一期，卻在手術時才發現是第四期，使得東教授進行的「開胸」手術成了不必要手術，不但浪費手術所需要的醫療資源，也導致患者要等到手術後體力恢復才能開始進行化療，造成後續治療的延誤。

根據文獻報告，正子掃描對於肺癌診斷期

FDG-PET/CT

IDC in the rib due to better lesion characterization. difficult to characterize as axillary, rib, or other lesions on PET alone.

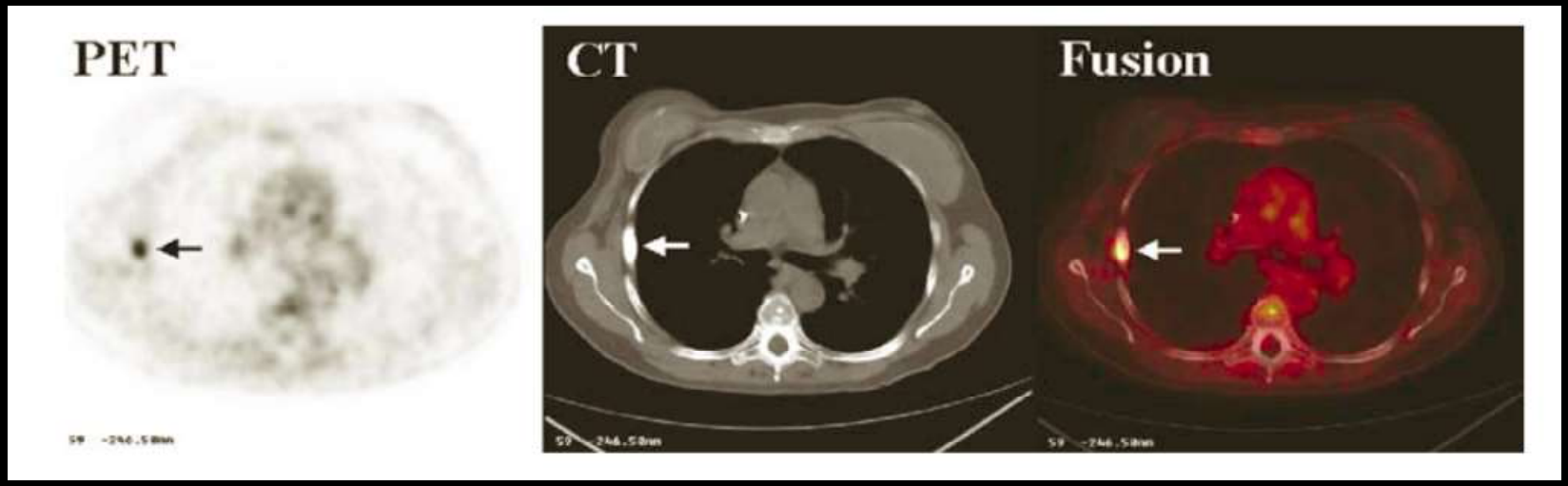

European Journal of Nuclear Medicine and Molecular Imaging Vol. 33, No. 3, March 2006

PET in Oncology

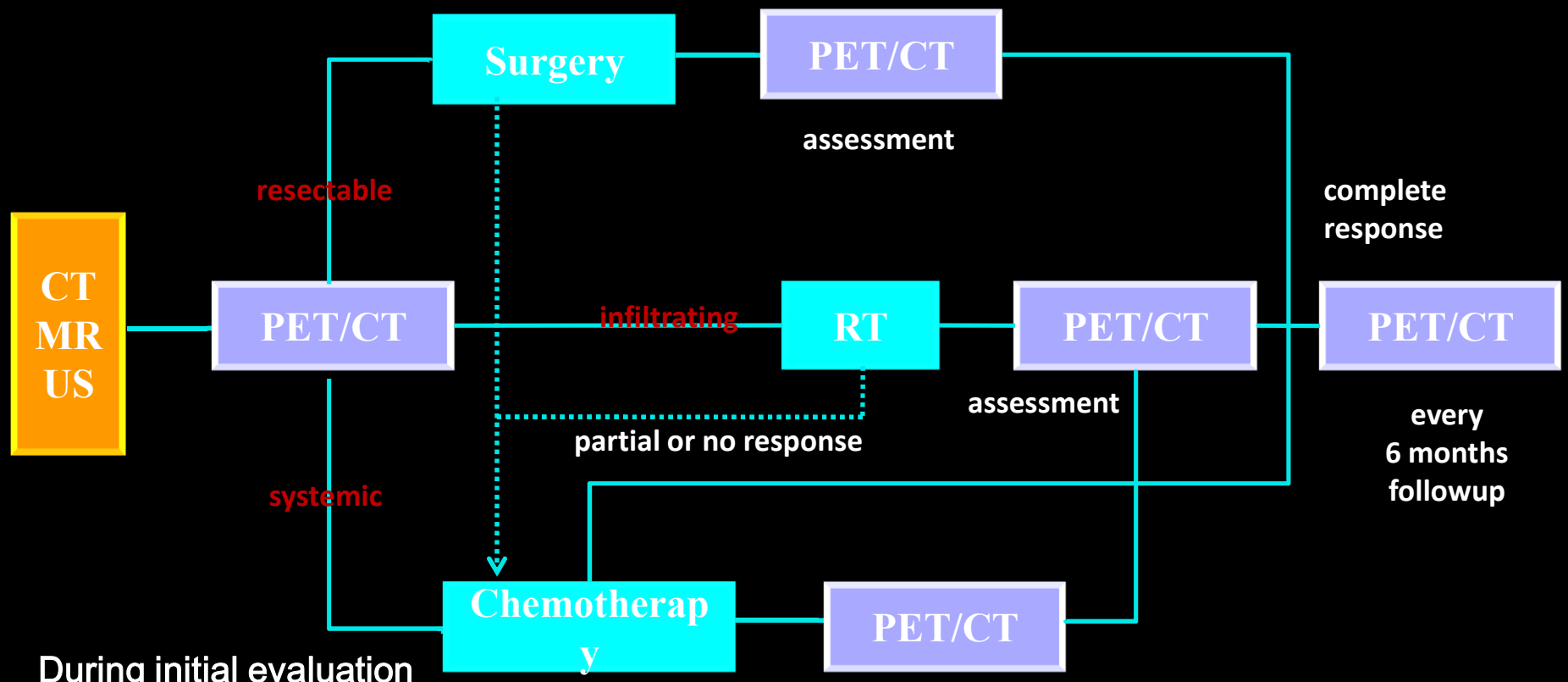

- During initial evaluation
- DDx benign from malignant lesion
- Determining degree of malignancy
- Staging
- Assessing prognosis after therapy

- Determining effect of therapy
- Restaging

- Documenting recurrence
- Monitoring progression
- Restaging

PET indications on NCCN

Cancer	Stage 0	Stage I	Stage II	Stage III	Stage IV	Response Preoperative	Response Post C/T	Recurrence
Esophagus	2A	2A	2A	2A	X	2B	2B	2A
Breast (except Paget's, phyllodes)	X	X	X	2B	X	2B	X	X
Colon	X	X	X	X	2A	X	X	2A
Melanoma	X	X	2A	2A	2A	X	2B	2B for local, nodal 2A for distant
Lung (NSCLC)	X	2A	2A	2A	2A	X	X	
Thyroid	X	X	X	X	X	X	X	2A
Head&neck (oral, pharynx, larynx)	X	X	X	2A	2A		2A	
Cervix	X	Optional except IB2 (2A)	2A	2A	2A except IVB	X		2A
Lymphoma (Hodgkin)	2A	2A	2A	2A	2A	X	2A	

Ovarian cancer

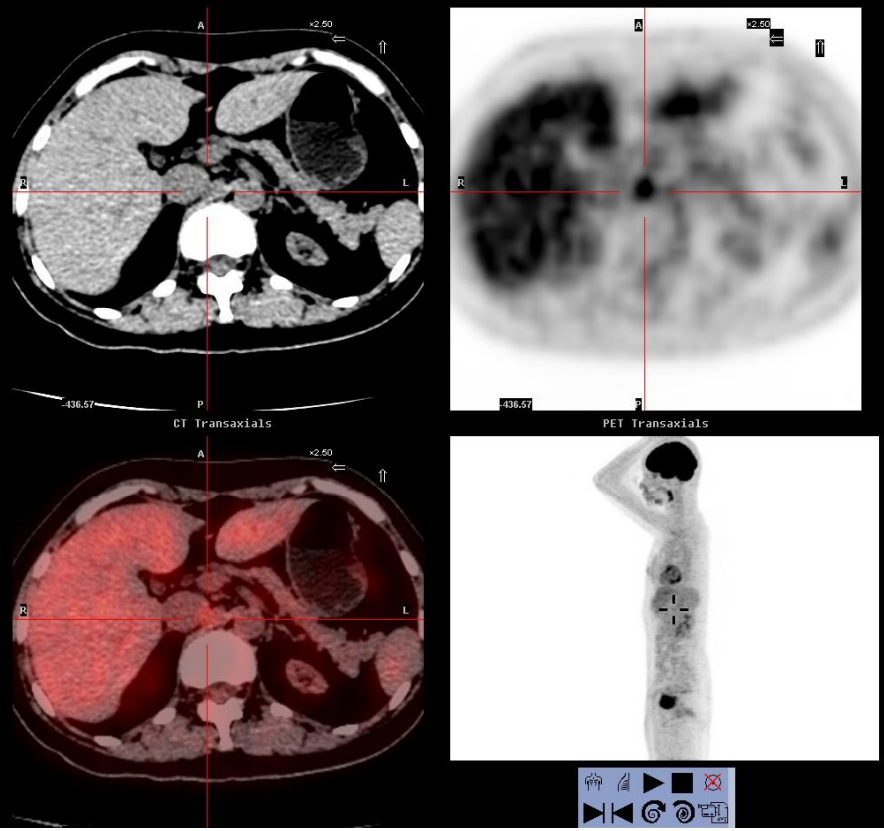

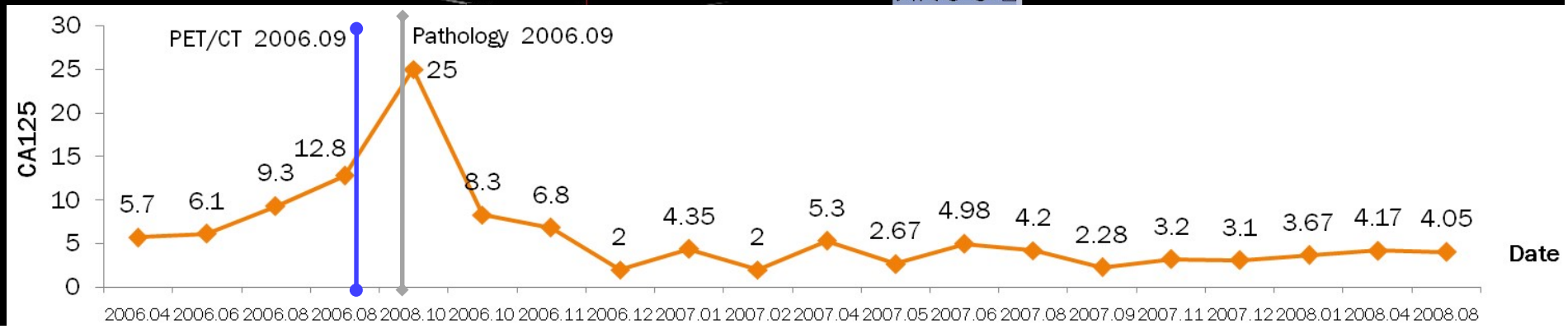

Serum tumor markers and FDG-PET/CT for detection of recurrent cancer

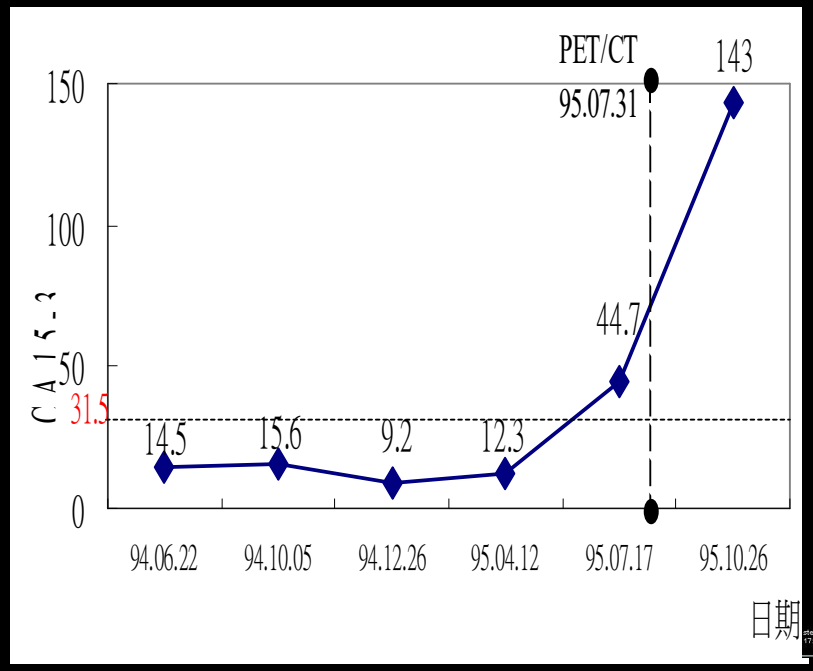

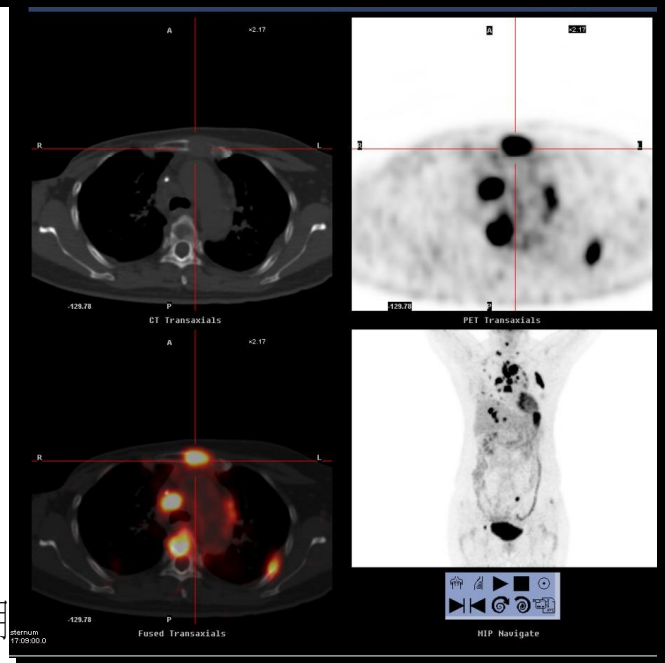

Clinical Application of Nuclear Oncology

- Tumor markers
- Radionuclide imaging
- Radionuclide therapy

Radionuclide therapy

Tumor type	Radiopharmaceutical
Differentiated thyroid carcinoma	I-131
Catecholamine-secreting tumors	I-131 MIBG
Neuroendocrine tumors	In-111 Octreotide, Y-90 DOTATOC, Lu-177 DOTATATE
Lymphoma Colon cancer	Y-90 Zevalin Sm-153 CEA, Lu-177 CEA, Y-90 CEA
Liver tumor	Y-90 Microsphere
Palliation of bony metastasis	P-32, Sr-89, Sm-153 EDTMP, Re-186 HEDP, Ra-223
Polycythemia vera	P-32

Differentiated thyroid carcinoma

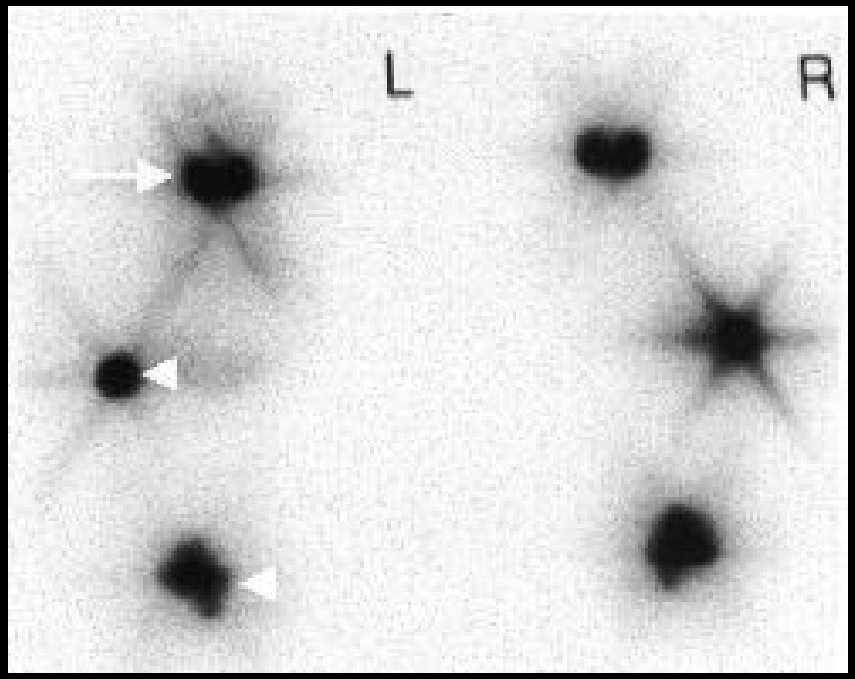

I-131uptake in primary differentiated thyroid carcinoma (arrow) and in rib and pelvic metastases (arrowheads)

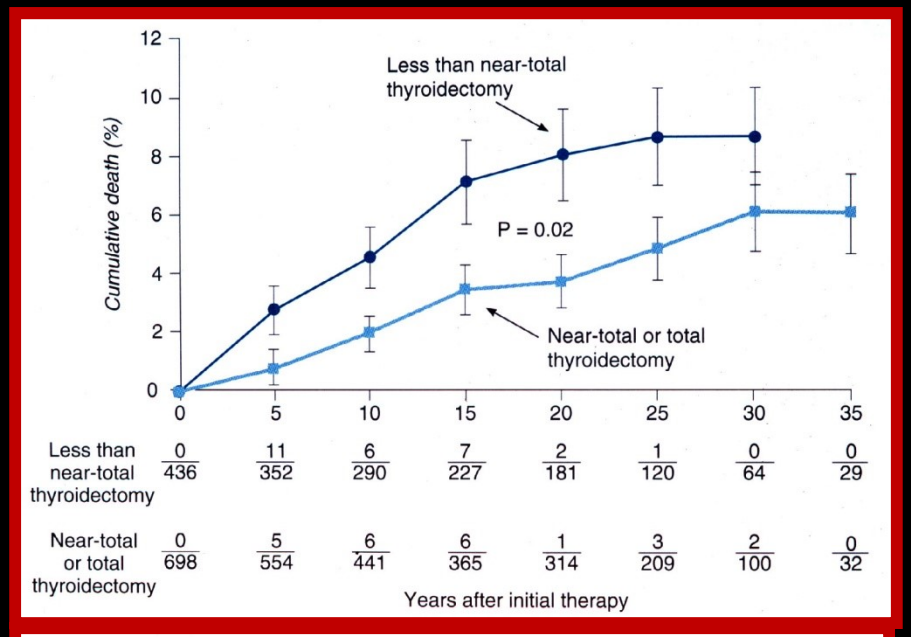

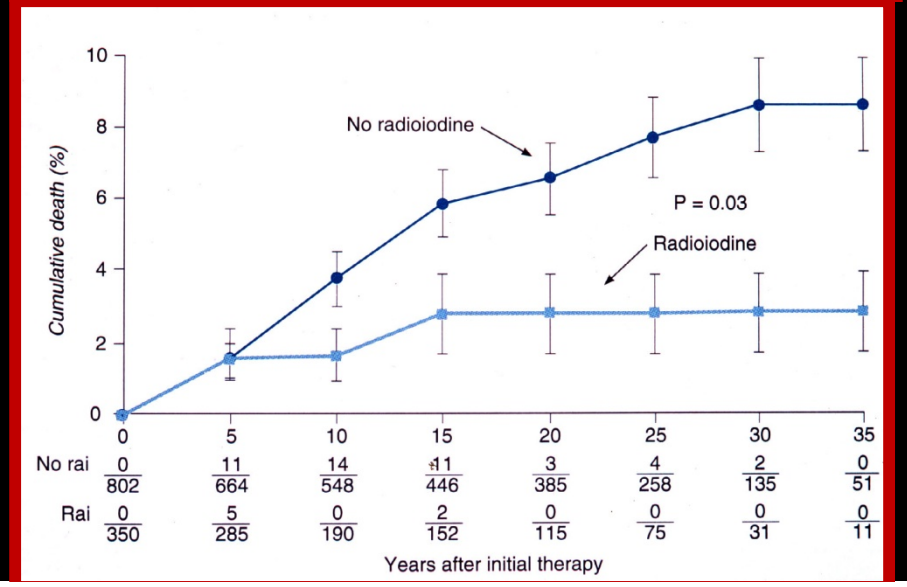

Radioiodinated MIBG Therapy

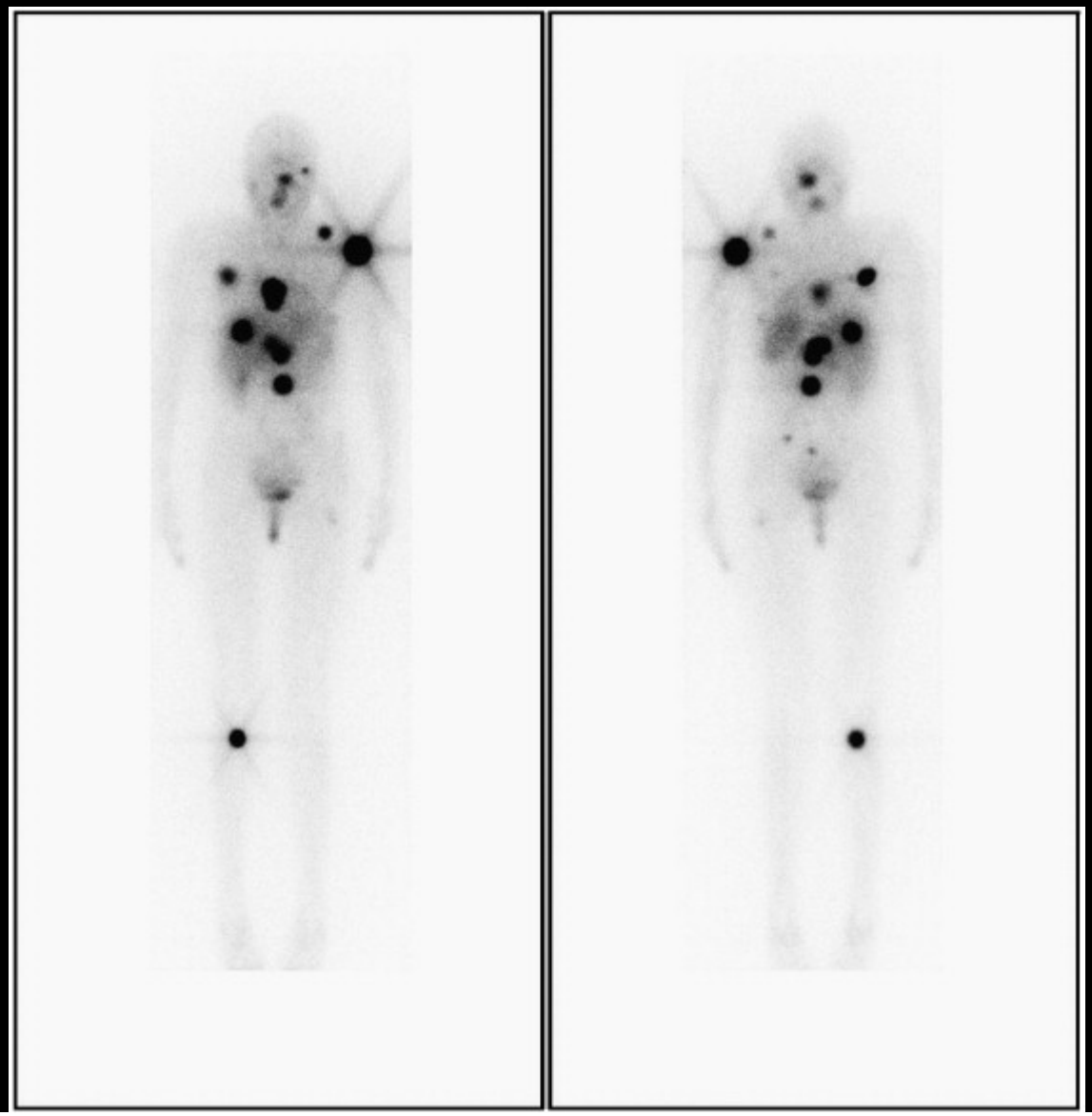

A 36-year-old female with a history of carotid body paraganglioma in 1997 with metastases to the skull, sternum and abdomen in 2006. She underwent surgical removal of T12 vertebral lesions, base of skull metastases and abdominal metastases. The patient was diagnosed with sternal metastases in 2007. The patient was treated with 428 mCi of MIBG (11.6 GBq). Anterior and posterior images obtained 1 week after the therapy dose are shown.

Peptide receptor targeted therapy

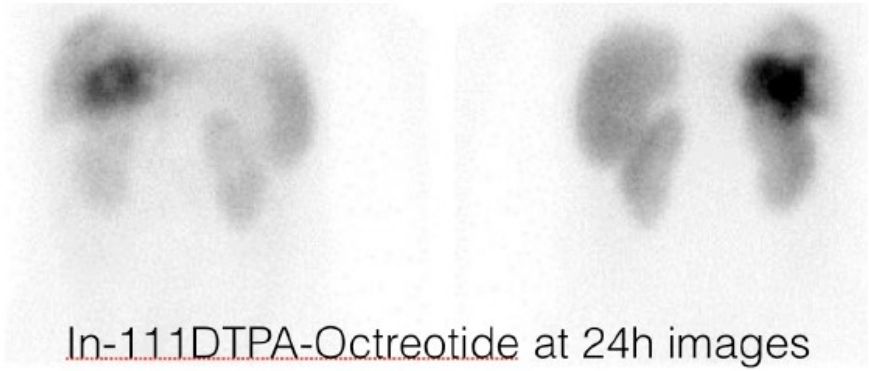

In-111DTPA-Octreotide at 24h images

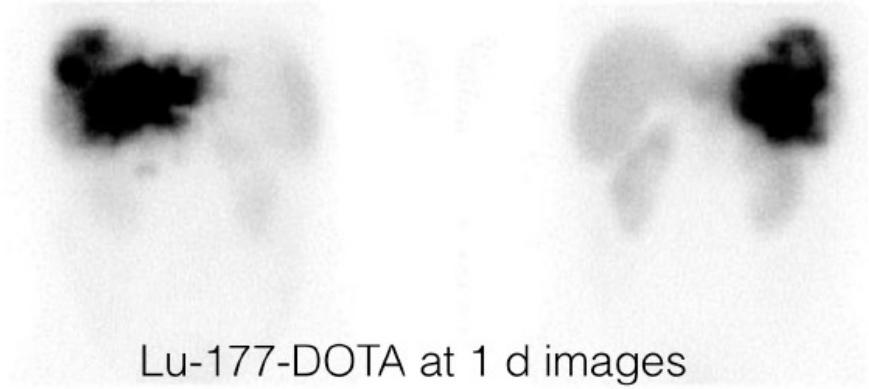

Lu-177-DOTA at 1 d images

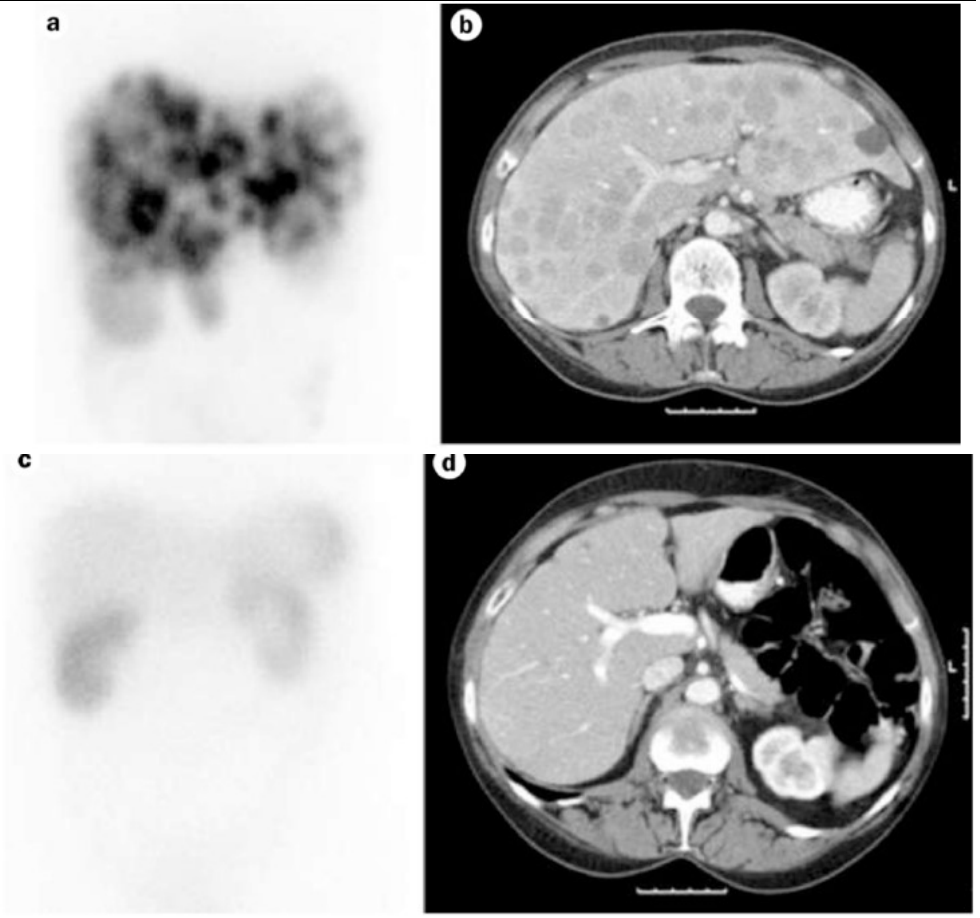

Non-Hodgkin lymphoma

What is Zevalin?

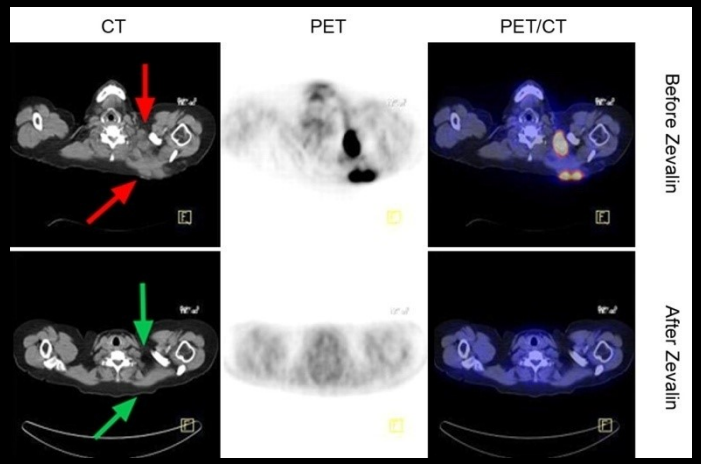

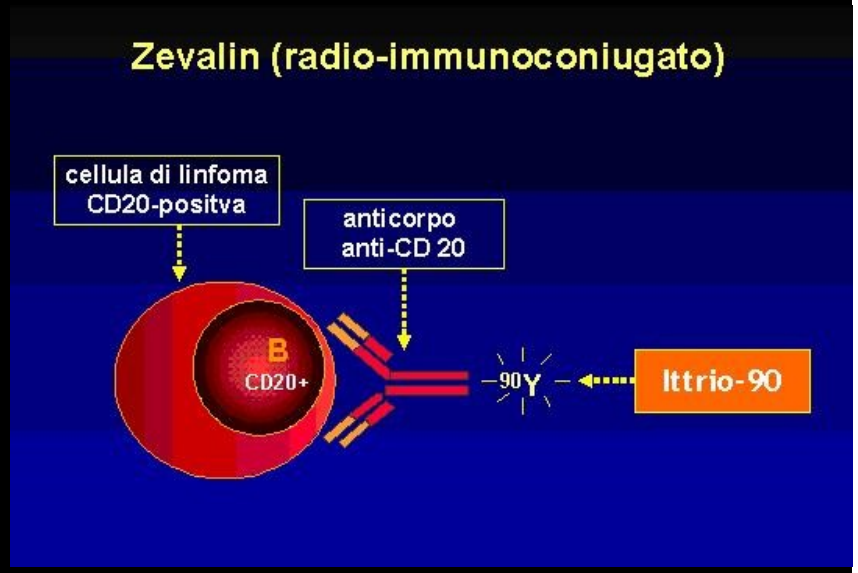

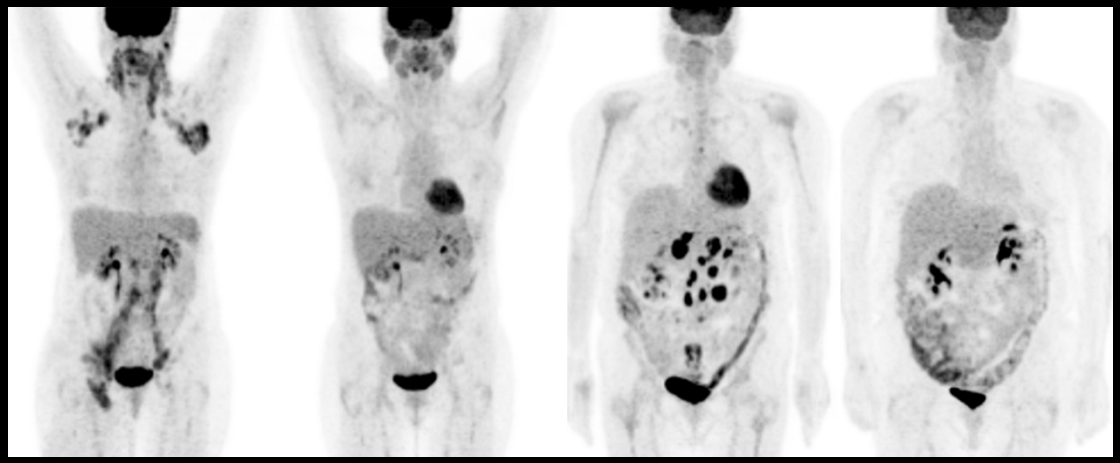

SNM 2009 Image of the Year

A monoclonal antibody that recognizes a special molecules that called CD20 on the surface of lymphoma cells.

Y-90 microspheres

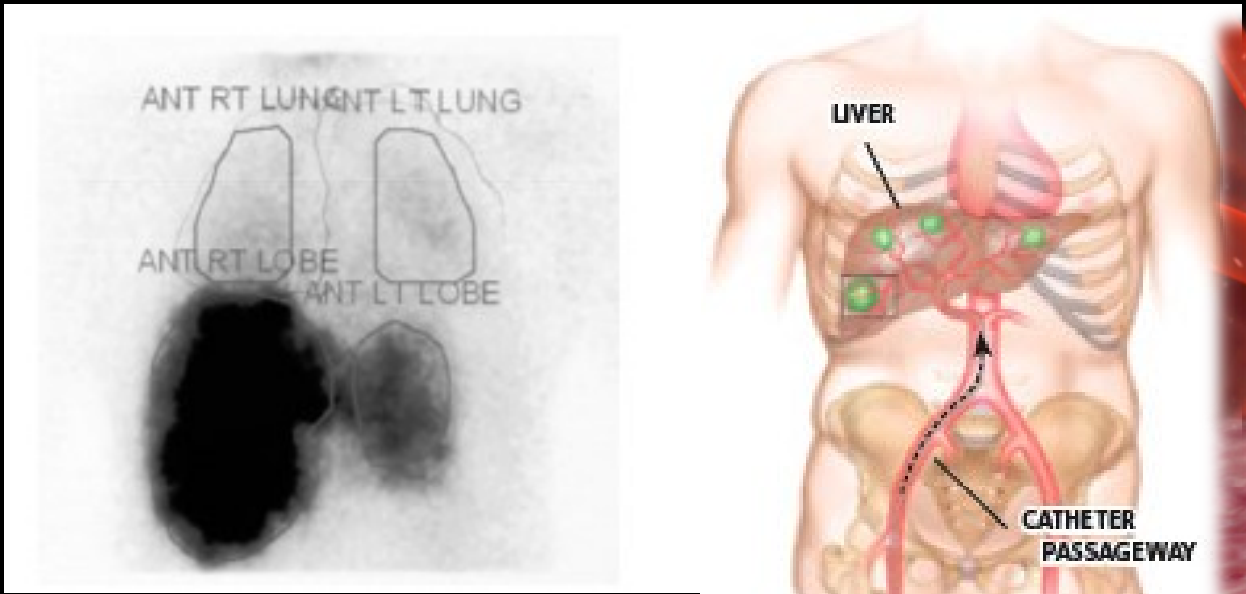

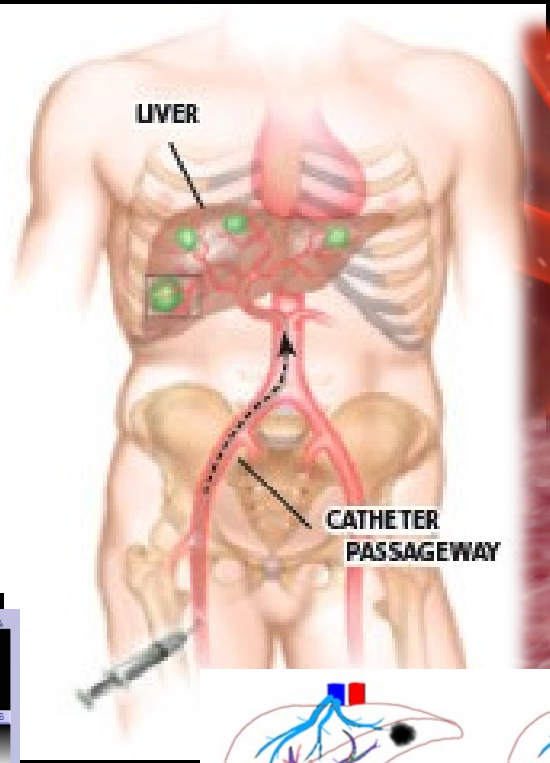

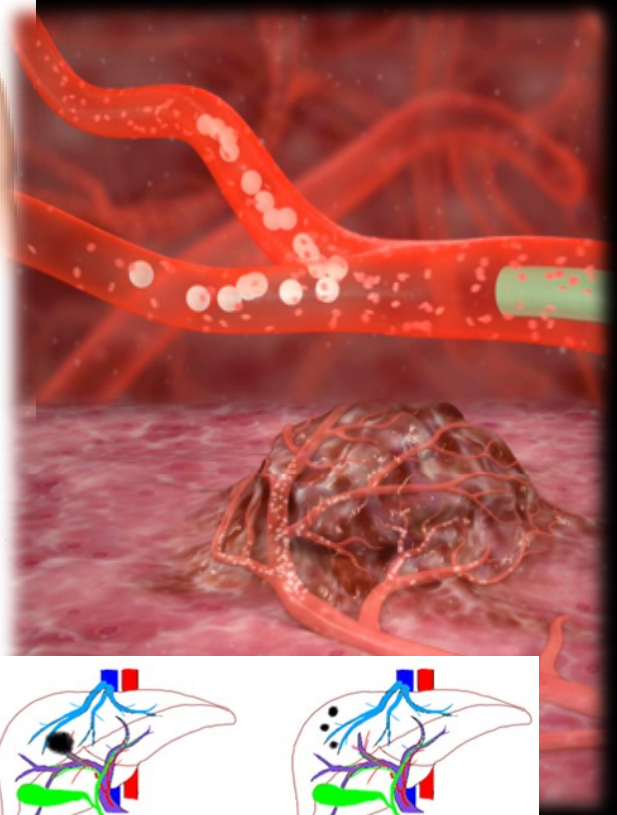

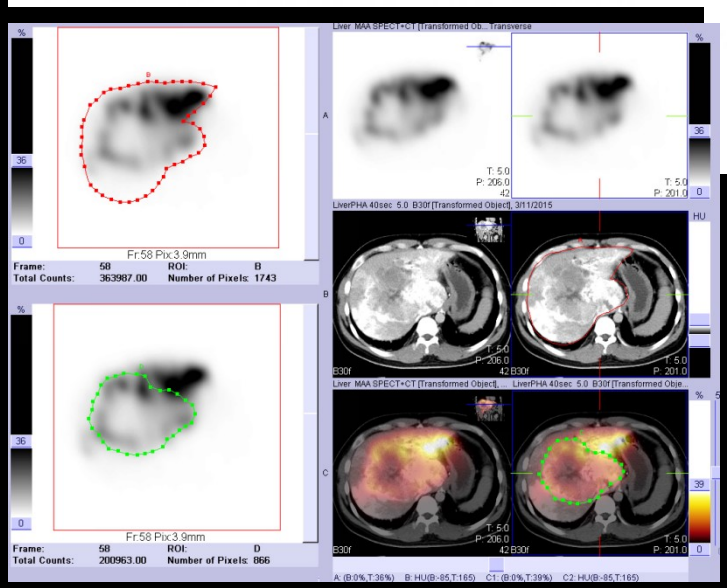

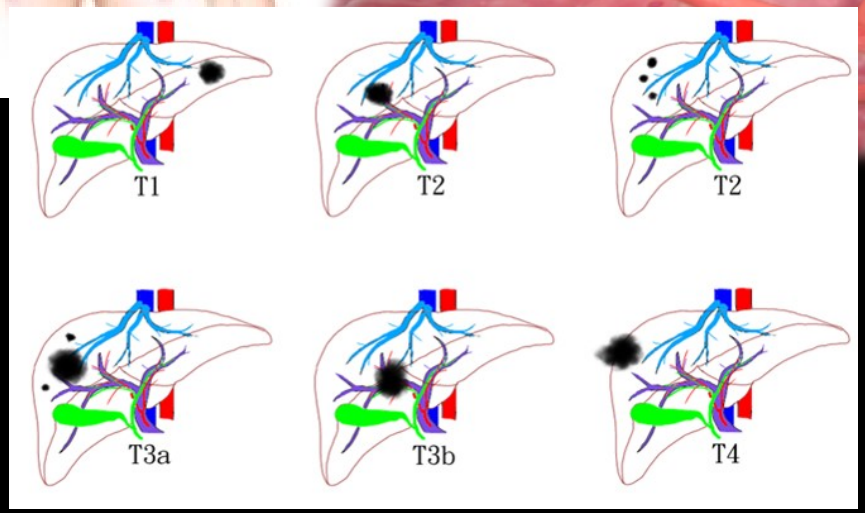

Y-90 microspheres

11-Nov-2009

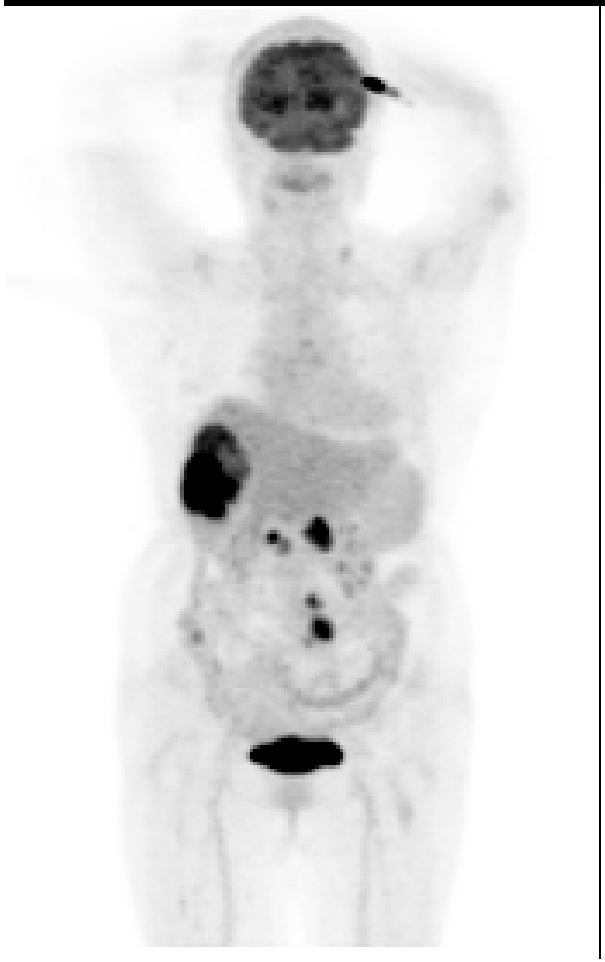

28-Dec-2009

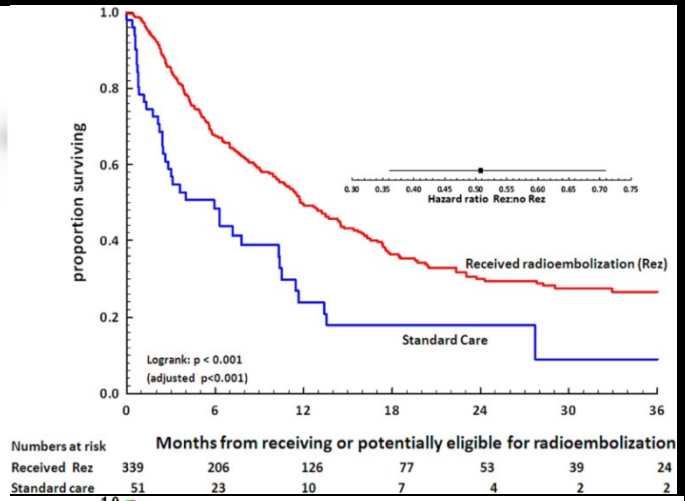

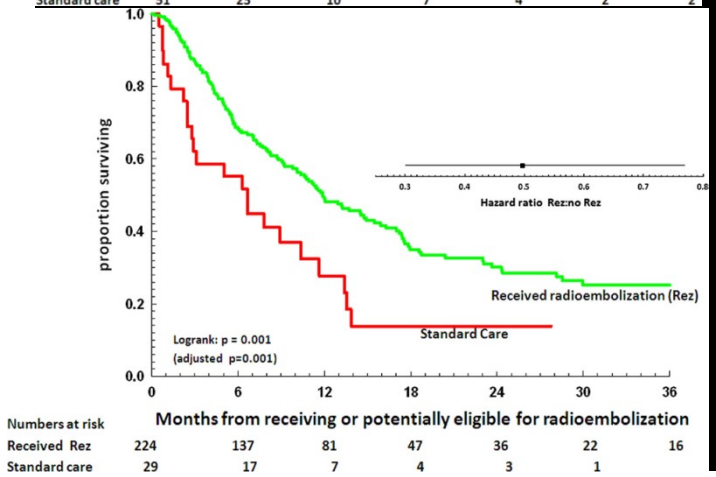

Alpha Emitter Radium-223 in ~~Metastatic Prostate Cancer~~

Ra 223

11.43 d

α 5.7162, 5.6067...
γ 269, 154, 324...
C14
σ 130
$\sigma_f < 0.7$

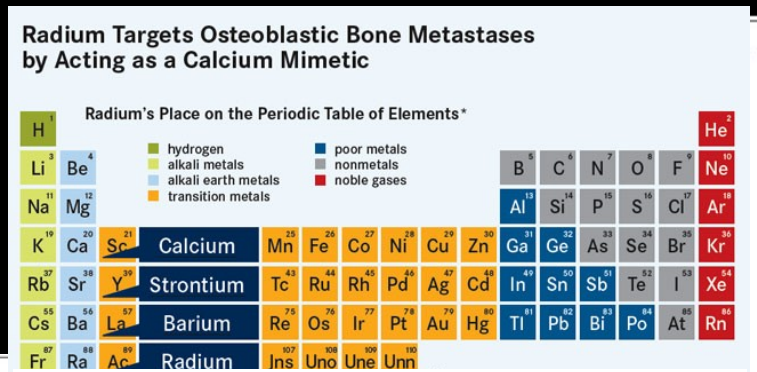

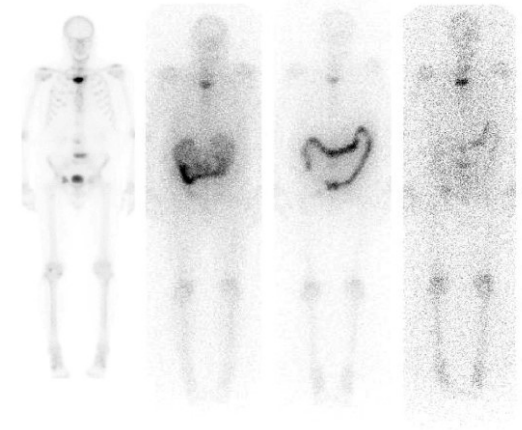

Fig. 5. Comparison of the images obtained after ^{99}Tc-MDP (A) or ^{223}radium on day 0 (B1), day 2 (B2) or day 6 (B3).

[^{18}F] FDG PET/CT at Baseline and After 2 Injections of Ra-223

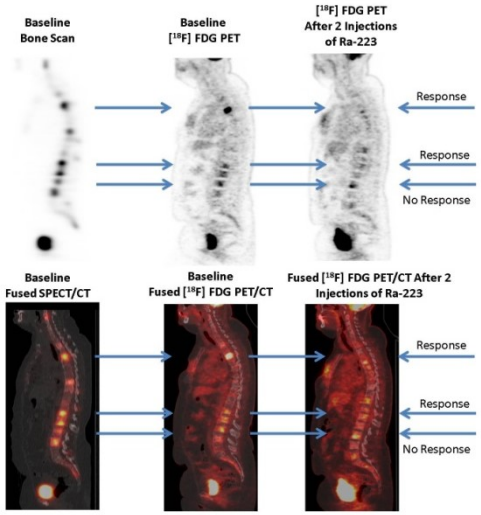

Images obtained after 2 injections of Ra-223 showed a significant decrease (≥ 25% decrease of SUV_{max} from baseline) in [^{18}F] FDG uptake intensity in multiple bone mets located in the thoracic and lumbar spine, indicating a partial metabolic treatment response at the level of the tumor cells early during Ra-223 therapy.

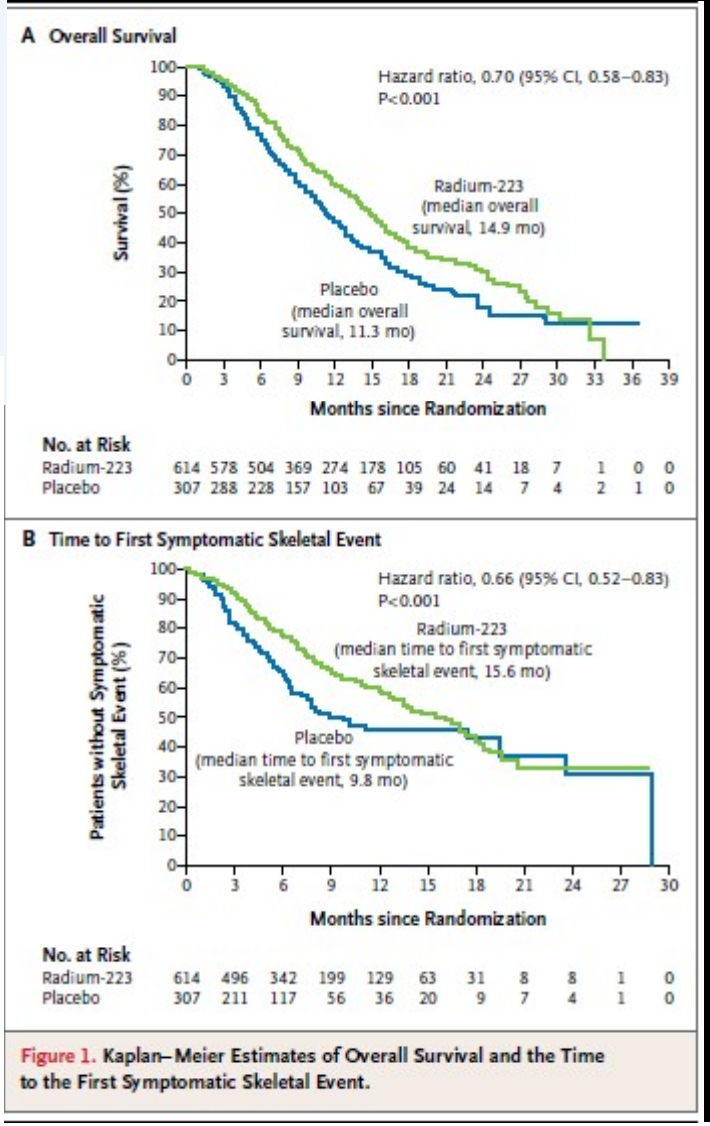

Figure 1. Kaplan–Meier Estimates of Overall Survival and the Time to the First Symptomatic Skeletal Event.

The End

Thanks for your attention !


深仁厚義
成仁取義
吳鳳公神位


成仁取義