

Correlation of thalamic blood flow redistribution with persistent complex regional pain syndrome in a stroke patient with poor diabetic control

Kao-Chih Hsu, Shin-Tsu Chang*

ABSTRACT

We present a right-hemispheric stroke patient with complex regional pain syndrome (CRPS). Symptoms of CRPS developed in conjunction with a corresponding elevation of the contralateral thalamic flow when the glycosylated hemoglobin values were high (16.1% and 13.4%), twice observed as migration from the bottom to the top location of the thalamus. CRPS improved after the glycosylated hemoglobin level reduced to 10.6% and 8.3%. Poor blood sugar control might cause redistribution of thalamic regional blood flow and be associated with the persistence of CRPS in this case. (*J Diabetes Invest*, doi: 10.1111/jdi.12104, 2013)

KEY WORDS: Complex regional pain syndrome, Thalamus, Type 2 diabetes mellitus

INTRODUCTION

Complex regional pain syndrome (CRPS) is a neuropathic disease characterized by pain disproportionate to the precipitating event and accompanied by some related sensory abnormalities (allodynia or hyperalgesia), edema, autonomic dysfunction, motor symptoms, and/or trophic changes¹. It usually develops after trauma, surgery, myocardial infarction, spinal cord injury or stroke. Changes in the thalamic regional cerebral blood flow have been shown to be responsible for both acute and chronic CRPS², including that in diabetic patients³. However, to our knowledge, no studies have thus far described the potential relationship between blood sugar levels and thalamic blood flow. The presence of pain in patients with diabetic neuropathy suggested that there might also be a relationship between CRPS and blood sugar control as a result of changes in regional cerebral blood flow in thalamus. Here, we describe the case of an acute stroke patient who developed CRPS. The patient's CRPS was linked to changes in thalamic blood flow, possibly associated with poor diabetic control.

CASE REPORT

A 57-year-old woman with a 10-year medical history of hypertension, type 2 diabetes mellitus, and gradually-developed tingling and numbness in extremities diagnosed as diabetic neuropathy was admitted to the Tri-Service General Hospital in Taipei, Taiwan, in November 2010 for acute right cerebral stroke

with neurological deficits, including dysarthria, left facial palsy and left-sided hemiparesis with grade 3 muscle power. Highly elevated (16.1%) glycosylated hemoglobin (HbA_{1c}) was also noted on admission. Magnetic resonance imaging (MRI) of the brain showed an acute infarction in the right median pons. The patient's dysarthria and left facial palsy improved quickly, but localized swelling, allodynia and pain developed in her left upper extremity, after admission. Previously developed symptoms of tingling and numbness in extremities remained almost the same as before. Brain technetium-99m ethyl cysteinate dimer single photon emission computed tomography (SPECT) showed increased tracer uptake in the right thalamus (Figure 1a), which was consistent with the clinical diagnosis of acute-onset CRPS.

After comprehensive rehabilitation, muscle strength in her left extremities gradually improved from grade 3 to grade 4–5, over a period of 4 months. During this time, the swelling, allodynia and pain in her left hand/forearm also improved slightly. By January 2011, the HbA_{1c} value reduced to 10.6%. The aforementioned symptoms in the patient's left arm worsened in July 2011. A second SPECT carried out at this point again showed increased thalamic tracer uptake. Surprisingly, in contrast to her initial SPECT findings, an upward migration of the regional thalamic flow was observed in this SPECT (Figure 1b). This change was noted simultaneously with a repeated elevation of HbA_{1c}, which was found to be 13.4%. The limb swelling, allodynia and pain reduced after another 3 months of rehabilitation, with a HbA_{1c} reduction to 8.3%.

DISCUSSION

CRPS is a painfully disabling condition in stroke patients. The current modified new diagnostic criteria according to Harden

Department of Physical Medicine & Rehabilitation, Tri-Service General Hospital, National Defense Medical Center, Taipei, Taichung Veterans General Hospital, Taichung, Taiwan
*Corresponding author. Shin-Tsu Chang Tel: +886-2-8792-3311 Fax: +886-945-60-5523
E-mail address: nnchang.tw@yahoo.com.tw

Received 19 July 2012; revised 10 January 2013; accepted 8 April 2013

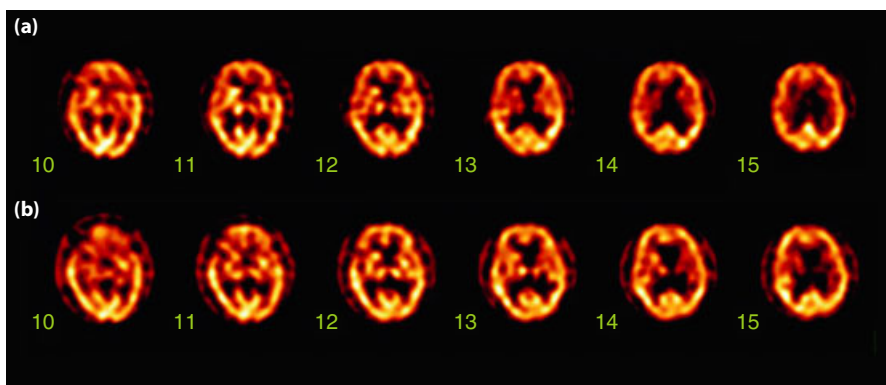


Figure 1 | Brain technetium-99m ethyl cysteinate dimer single photon emission computed tomography (SPECT). (a) The first SPECT showing a high radioisotope uptake in the lower part of the right thalamus (number 11 and 12). (b) The high uptake is still observed in the right thalamus (number 12 and 13) in the second SPECT. Redistribution of thalamic blood flow with upward migration is considered.

*et al.*¹ are listed in Table 1. SPECT is accepted as a useful procedure for clinical evaluation and follow up in CRPS⁴, and iodine-123-labelled iodoamphetamine SPECT was used by Ushida *et al.*² to evaluate thalamic perfusion in patients with spontaneous neuropathic pain (CRPS vs radiculopathy). The authors of the aforementioned study found that neuropathic pain can alter thalamic neuronal activity, and that the activity of the contralateral thalamus might be related to the persistence of chronic pain.

In the present case, symptoms of CRPS developed in conjunction with a corresponding elevation of the contralateral thalamic flow when the HbA_{1c} values were high (16.1% and 13.4%). The redistribution of thalamic perfusion, as a consequence of persistent CRPS, was assumed to be associated with increased neuronal activity in the thalamus. These results are consistent with those cited in a review of neuropathic pain disorder studies by Fischer and Waxman³, which showed that central neuropathic mechanisms can contribute to the pain experienced by diabetics. Interestingly, the review stated that

thalamic dysfunction occurs in patients with diabetes mellitus, and that in experimental models of this disease, neurons in the ventral posterolateral thalamus can become hyperexcitable, firing at abnormally high frequencies and generating aberrant spontaneous activity. Therefore, thalamic neurons can act as central generators or amplifiers of pain in diabetics. Selvarajah *et al.*⁵ also reported that painful diabetic neuropathy is associated with increased thalamic vascularity, which could be related to increased neuronal activity. In the present case, remission of CRPS was achieved after the HbA_{1c} level reduced. From the extant literature and our current observations, it might have implications that persistence of CRPS and redistribution of thalamic flow could result from poor serum glucose control, and possibly provide an important clue to the pathogenesis of CRPS.

In conclusion, we present a case of acute stroke and suggest that the poor blood sugar control might cause redistribution of thalamic regional blood flow, resulting in the persistence of CRPS.

Table 1 | Diagnostic criteria for complex regional pain syndrome

1. Continuing pain, which is disproportionate to any inciting event
2. Must report at least one symptom in three of the four following categories:
 - 2.1. Sensory Reports of hyperesthesia and/or allodynia
 - 2.2. Vasomotor Reports of temperature asymmetry and/or skin color changes and/or skin color asymmetry
 - 2.3. Sudomotor/edema Reports of edema and/or sweating changes and/or sweating asymmetry
 - 2.4. Motor/trophic Reports of decreased range of motion and/or motor dysfunction (weakness, tremor, dystonia) and/or trophic changes (hair, nail, skin)
3. Must show at least one sign at time of evaluation in two or more of the following categories:
 - 3.1. Sensory Evidence of hyperalgesia (to pinprick) and/or allodynia (to light touch and/or temperature sensation and/or deep somatic pressure and/or joint movement)
 - 3.2. Vasomotor Evidence of temperature asymmetry (>1°C) and/or skin color changes and/or asymmetry
 - 3.3. Sudomotor/edema Evidence of edema and/or sweating changes and/or sweating asymmetry
 - 3.4. Motor/trophic Evidence of decreased range of motion and/or motor dysfunction (weakness, tremor, dystonia) and/or trophic changes (hair, nail, skin)
4. There is no other diagnosis that better explains the signs and symptoms

Reproduced from Harden *et al.*¹ with permission.

ACKNOWLEDGEMENT

This report was carried out without any financial support or relationships that may pose a conflict of interest.

REFERENCES

1. Harden RN, Bruehl S, Stanton-Hicks M, *et al.* Proposed new diagnostic criteria for complex regional pain syndrome. *Pain Med* 2007; 8: 326–331.
2. Ushida T, Fukumoto M, Binti C, *et al.* Alterations of contralateral thalamic perfusion in neuropathic pain. *Open Neuroimag J* 2010; 4: 182–186.
3. Fischer TZ, Waxman SG. Neuropathic pain in diabetes—evidence for a central mechanism. *Nat Rev Neurol* 2010; 6: 462–466.
4. Lai MH, Wang TY, Chang CC, *et al.* Cerebellar diaschisis and contralateral thalamus hyperperfusion in a stroke patient with complex regional pain syndrome. *J Clin Neurosci* 2008; 15: 1166–1168.
5. Selvarajah D, Wilkinson ID, Gandhi R, *et al.* Microvascular perfusion abnormalities of the thalamus in painful but not painless diabetic polyneuropathy: a clue to the pathogenesis of pain in type 1 diabetes. *Diabetes Care* 2011; 34: 718–720.