

# The role of quantitative sacroiliac scintigraphy in clinical relevance: a literature review

## Abstract

Nuclear skeletal scintigraphy affords a highly sensitive functional method in order to identify systemic skeletoarticular disorders or injuries. Bone scan with quantitative sacroiliac scintigraphy (QSS) is a practical indicator for discovering inflammation/stress of sacroiliac (SI) joints. Sacroiliitis takes place in many situations, for instance, spondyloarthritis, osteitis condensans ilii, post-streptococcal reactive arthritis, and lower extremity periostitis. QSS exerts a superior tool in scintigraphy rehabilitation and raises alertness for physicians paying more attention to the following steps for exact diagnosis.

**Keywords:** skeletal scintigraphy, osteitis condensans ilii, Streptolysin, periostitis, post-streptococcal reactive arthritis, scintigraphic rehabilitation

Volume 15 Issue 6 - 2023

Shin-Tsu Chang<sup>1,2</sup>

<sup>1</sup>Department of Physical Medicine and Rehabilitation, Kaohsiung Veterans General Hospital, Kaohsiung, Taiwan

<sup>2</sup>Department of Physical Medicine and Rehabilitation, Tri-Service General Hospital, School of Medicine, National Defense Medical Center, Taipei, Taiwan

**Correspondence:** Shin-Tsu Chang, Department of Physical Medicine and Rehabilitation, Tri-Service General Hospital, School of Medicine, National Defense Medical Center, Taipei, Taiwan, Email [ccdvlaser1959@gmail.com](mailto:ccdvlaser1959@gmail.com)

**Received:** December 06, 2023 | **Published:** December 22, 2023

## Introduction

Skeletal nuclear scintigraphy affords a highly sensitive functional illustration for whole body in varying bony diseases.<sup>1,2</sup> The technetium 99m-methylene diphosphonate (Tc-99m MDP) bone scan has been reported more of use than plain films in the earlier recognition of SpA.<sup>3</sup> Tc-99m MDP, which is engulfed by skeleton cells. SPECT alone or combined with CT as hybrid imaging can identify the precise spot of pain in diverse disorder,<sup>4,5</sup> the sternoclavicular joint inflammation.<sup>6</sup> Quantitative SI scintigraphy (QSS) chose Tc-99m-MDP as the radiological compound.<sup>7</sup> A recent article reported the worth of QSS in serving the differential diagnoses of backache-associated disorders, for instance, occult fracture,<sup>8</sup> chiefly in patients with SI joint pain due to a traffic accident.

Nuclear medicine bone scan with QSS has been reported a valuable indicator for inflammation of SI joint in the last 60 years.<sup>9</sup> QSS is performed by intravenous injection of 750 MBq Tc-99m MDP, and planar imaging of the spine/SI joints reaches in the antero-posterior projections 3 hours later. Based on the region-of-interest method, a SI joint-to-sacrum ratio (SI/S ratio or SI ratio), is calculated quantitatively by device computer.<sup>10</sup> The ratio for the upper, middle, and lower thirds of both joints is recorded separately. Clinically, the inflammation is deemed as negative if the SI/S ratio is <1.3, or equivocal if around 1.4-1.5, or positive if >1.5.<sup>11</sup>

## QSS perceiving and specifying sacroiliitis

Sacroiliitis is an inflammation of the SI joint of rheumatologic diseases or abnormal shearing force (stress), for instance, postpartum females, leisure runners, military soldiers, and ice hockey elites.<sup>12-17</sup> Clinical expressions of sacroiliitis are lower back pain, and many SI-associated disorders.<sup>18</sup>

Buell et al.<sup>19</sup> firstly reported elevated SI ratios in subjects with SI disorders. In 1998, Kaçar et al.<sup>20</sup> calculated the SI ratios as average of <1.3200 for the healthy and <1.3812 for patients with late arthritis, while even elevated at 1.5200-2.0900 for patients with early arthritis. Tiwari et al.<sup>21</sup> later gave an idea about quantifying ways of the SI joint index: rectangular ROI, irregular ROI, profile-integrated counts and profile peak counts. All of above four demonstrated akin to results. As a result, SI ratio is a excellent appraisal for vigilance of early but not

late arthritis.<sup>20</sup> Consideration of different tissue structures and kinetic biomechanics in the upper, middle, and lower three parts of the SI joints, SI ratios should be calculated separately in the three thirds.<sup>22</sup> With respect to QSS in healthy people, the first literature reported that the SI ratios go downhill little by little with age in women, and there are two plateaus in ages 21 to 40, and 41 to 70 years in men.<sup>23</sup> The novel quantitative analysis of QSS has been confirmed superior than planar bone scan in active stage.<sup>24</sup>

## QSS for spondyloarthropathy, including ankylosing spondylitis

In the 1980s, QSS was utilized as an essential index in early diagnosis of ankylosing spondylitis (AS).<sup>25-29</sup> The SI ratio of 1.55 indicated that AS steps forward to last less than three years or bigger than three years if 1.40.<sup>30</sup> One study of AS patients with 2-year follow-up brought to a close that the QSS of AS proposes the prospect for earlier disease identification in possible cases.<sup>31</sup> Considering time and cost, QSS is fairly superior than MRI in identifying AS as well as sacroiliitis.<sup>32</sup> The factor of highly sensitive C-reactive protein (hs-CRP) is a biomarker for varynig diseases, such as SpA. A study declared that the high hs-CRP in SpA acts an index of SI inflammation to imply a rheumatologic upshot to a flair-up, based on the fact of a significant difference in hs-CRP and QSS, especial in the middle third.<sup>33</sup>

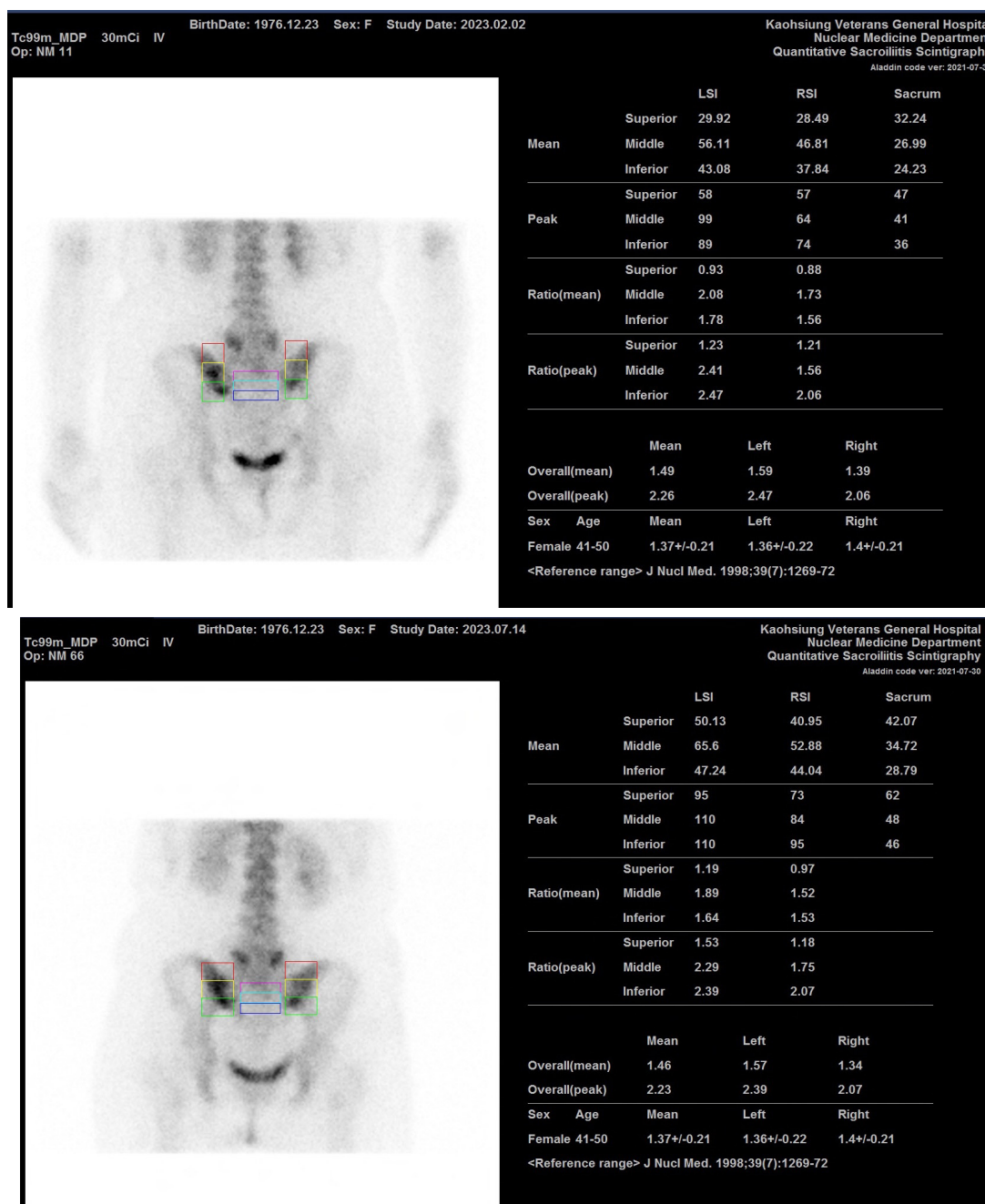
The magnitude of utilizing CT along with QSS in the judgment of SI joints is that combination of CT (semi-quantitative analysis) and QSS (quantitative analysis) can raise the inimitable requirement of the diagnostic intensity for active phase of sacroiliitis.<sup>34</sup> CT can identify sclerosis and syndesmophytes, which is useful in last stage of sacroiliitis.<sup>34,35</sup> For exact diagnoses of SpA, QSS is only advocated while examined together with the CT scan.<sup>64</sup> The combination of both QSS and MRI increased the diagnostic accuracy sacroiliitis with axial spondyloarthritis (SpA).<sup>36</sup>

One review article enrolled studies about AS populations with/without sacroiliitis, and concluded that the probability ratio of QSS for diagnosis of acute sacroiliitis is only 2.5-3.0, so QSS is limited for diagnostic ethics for AS, even QSS is almost 50% cost and generally more avfeasible than MRI.<sup>37</sup>

### QSS for osteitis condensans Ilii

Osteitis condensans ilii (OCI) was reported first in 1926, which was also called as idiopathic pelvis sclerosis,<sup>38</sup> or hyperostosis triangularis ilii.<sup>39</sup> OCI often shows intermittent lower backache and associated pain on SI stress tests,<sup>40</sup> affecting women less than the age of 40. Patients also have SI joint tenderness with obvious lumbar lordosis.<sup>41</sup> The features of X-ray films of OCI reveal sclerosis in triangular shape along the auricular part of the both ilia with preserved space of SI joint,<sup>42,43</sup> mimic radiographic sacroiliitis.<sup>44</sup> OCI can bring

stress in the SI joints, resulting in piriformis muscle syndrome with further sciatica. The relationship between OCI and SI joint sacroiliitis (stress), and between piriformis muscle syndrome and sciatica, has been reported. Symptoms of OCI showed with associated sciatica can be effectively treated by simple injection SI joint, which use QSS as the first to detect SI joint stress prior and after the injection.<sup>45</sup> OCI is intractable in patient with SARS-CoV-2 infection, and higher ratios of QSS persisted even after intervention of multiple rehabilitation modalities (Figure 1).



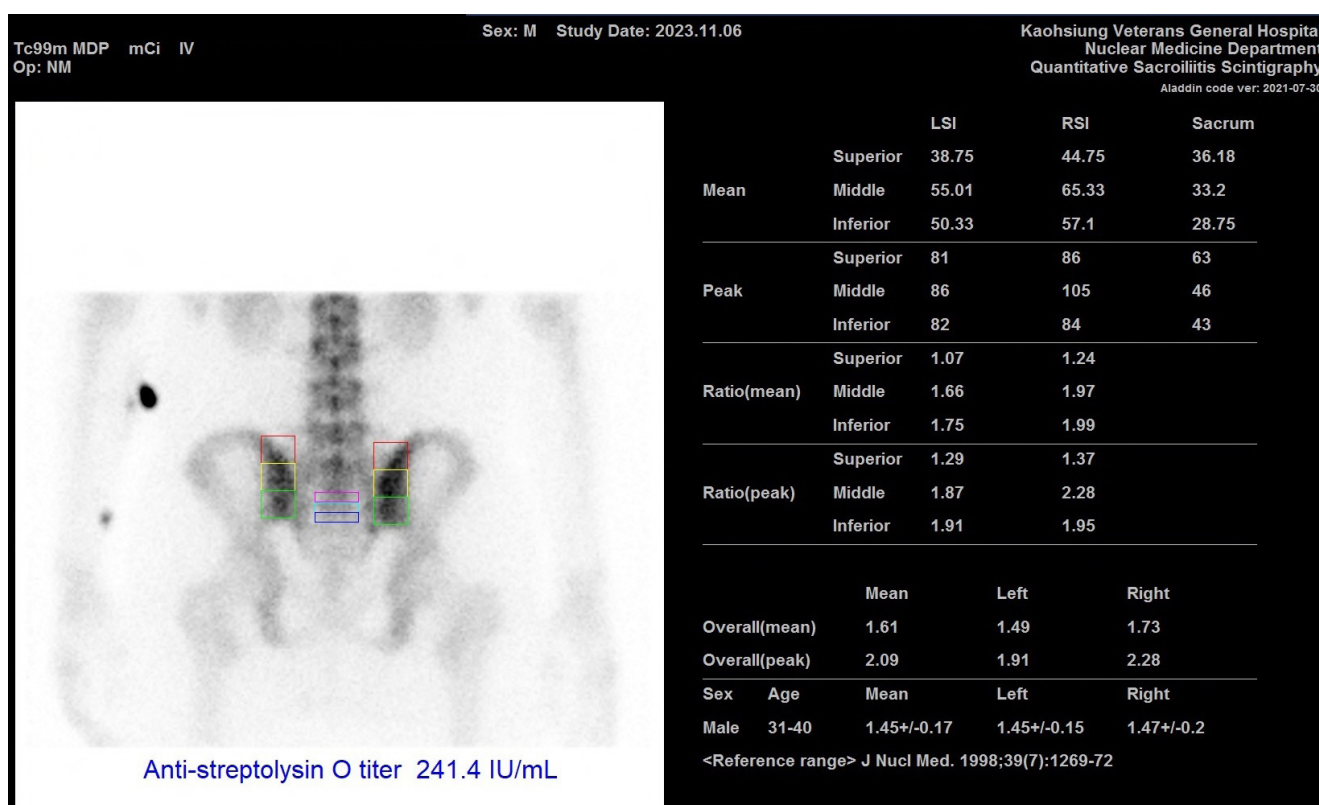
**Figure 1** Osteitis condensans ilii is intractable in this case with SARS-CoV-2 infection, and higher ratios of QSS persisted even after intervention of multiple rehabilitation modalities before (1A) and after (1B).

### QSS for Post-streptococcal reactive arthritis

The development of post-streptococcal reactive arthritis (PSRA) has been known to be a prior subclinical streptococcal infection. The titers of anti-streptolysin O (ASLO) play a role in diagnosis PSRA,<sup>22,46-48</sup> early arthritis related to rheumatic fever,<sup>49-51</sup> as well as movement disorder.<sup>52</sup> A defined cut point is considered as negative if the titer  $\leq 116$  IU/mL, and positive if  $>116$  IU/mL.

Patients with high ASLO levels have bigger sways on all postural

parameters compared to those with low ASLO. Proprioceptive deficit in the SI joint contributes to postural impairments.<sup>53,54</sup> A study presenting the association of the SI joint in the progress of PSRA showed a significant relationship disclosed between QSS and ASLO, with the raised ASLO titer per unit, SI ratio raised by 0.0008 units, and furthermore 0.0074 units for every extra year, indicating a well-built association between both in PSRA.<sup>22</sup> This is the only study presenting the involvement of this specific joint in PSRA.<sup>22</sup> A latest case with ASLO value 241.4 IU/mL also present the similar finding (Figure 2).



**Figure 2** Post-streptococcal reactive arthritis can be diagnosed when measured ASLO value 241.4 IU/mL in this case with persisted higher ratios of QSS.

ASLO, anti-streptolysin O; QSS, quantitative sacroiliac scintigraphy

### QSS for Periostitis-induced sacroiliac pain

Some body injuries, malpractice of exercise, and abnormal trunk posture will increase SI joint stress to develop high QSS, while pain-killers and rehabilitation correcting abnormal posture are able to decrease SI ratios.<sup>55</sup> Periostitis of lower limb (foot) is a common disorder in sports medicine, which can be treated well by a beneficial device, low-level laser therapy (LLLT), for improvement of proprioception disorder.<sup>56,57</sup>

Based on the truth that foot pain can bottom-up provoke SI joint stress, a noteworthy relationship was found among the middle and lower thirds of the joint, and QSS for the middle third on bilateral SI joints were significantly higher (0.06 units) compared to the lower third. Improvement of the foot periostitis can restore the abnormal QSS, which reflect to a conclusion that subjects with stress in SI after foot/ankle periostitis can be healed well by either LLLT or conventional therapies.<sup>55</sup> Another study regarding medial tibial stress syndrome (MTSS) reported akin to results, which claimed that SI stress due to bottom-up processing of MTSS can be restored to normal

after LLLT.<sup>58</sup> Both MTSS and SI joint stress could be confirmed by QSS.<sup>58</sup> The use of QSS is the first study of periostitis-induced sacroiliac pain.

### Limitations of QSS

QSS has three imitations. The first is lower specificity in identifying chronic inflammation, the second is minute overlaps in SI indices in patients with/without sacroiliitis, and the third is lack of stratification of age and gender in order to discriminate the overlapping sites caused by sacroiliitis.

### Conclusion

We revisited skeletal scintigraphy using QSS on patients with SI joint disorders, and recommend physicians paying more attention to the disease pathophysiology contributing sacroiliitis. QSS is ready to lend a hand in advisory evaluation of disease(s). Empirical practice of QSS showed that bone scan is an excellent technique for follow-up measurement in scintigraphic rehabilitation and raises awareness towards exact diagnosis.

## Acknowledgments

None.

## Conflicts of interest

The authors declare no conflicts of interest. The article did not receive any specific grant from funding agencies in the public, commercial, or not-for-profit sectors.

## References

- Rybak L, Rosenthal D. Radiological imaging for the diagnosis of bone metastases. *Q J Nucl Med.* 2001;45(1):53–64.
- Tombal B, Lecouvet F. Modern detection of prostate cancer's bone metastasis: is the bone scan era over? *Adv Urol.* 2012;2012:893193.
- Shinto AS, Kamaleshwaran K, Anjali M, et al. Utility of 99mTc-MDP bone scan in comparison to MRI and plain radiographs for the diagnosis of early spondyloarthritis. *J Spinal Surg.* 2014;1(1):12–15.
- Rosenthal L. Nuclear medicine techniques in arthritis. *Rheum Dis Clin North Am.* 1991;17(3):585–597.
- Chang ST, Chuan C, Wan H, et al. Single-photon emission computed tomography/computed tomography (hybrid imaging) in the diagnosis of unilateral facet joint arthritis after internal fixation for atlas fracture. *HSSOA J Med Study Res.* 2019;2:010.
- Chang ST, Tsai TW. Abrupt swollen bump of the shoulder girdle joint as the first presentation of flare-up in a case of axial spondyloarthritis. *Can J Biomed Res Tech.* 2020;3(5):1–5.
- Lin WY, Wang SJ. The influence of two bone agents (99Tcm-pyrophosphate and 99Tcm-methylenediphosphonate) on quantitative sacroiliac joint scintigraphy. *Nucl Med Commun.* 1996;17(12):1035–1038.
- Wei JC, Chen H, Hsieh T, et al. Clinical practice recommendations for the use of imaging in the diagnosis and management of axial spondyloarthritis in Taiwan. *Int J Rheum Dis.* 2020;23(1):24–36.
- Verlooy H, Mortelmans L, Vleugels S, et al. Quantitative scintigraphy of the sacroiliac joints. *Clin imaging.* 1992;16(4):230–233.
- Davis MC, Turner D, Charters T, et al. Quantitative sacroiliac scintigraphy. The effect of method of selection of region of interest. *Clin Nucl Med.* 1984;9(6):334–340.
- Zhu WL, Shih CT, Yi CL, et al. A worthwhile measurement of early vigilance and therapeutic monitor in axial spondyloarthritis: a literature review of quantitative sacroiliac scintigraphy. *European Medical Journal Rheumatology.* 2021;8(1):129–139.
- Weber U, Jurik AG, Zejden A, et al. Frequency and anatomic distribution of magnetic resonance imaging features in the sacroiliac joints of young athletes: exploring “background noise” toward a data-driven definition of sacroiliitis in early spondyloarthritis. *Arthritis Rheumatol.* 2018;70(5):736–745.
- Varkas G, Manouk H, Thomas R, et al. Effect of mechanical stress on magnetic resonance imaging of the sacroiliac joints: assessment of military recruits by magnetic resonance imaging study. *Rheumatology.* 2018;57(3):508–513.
- Winter J, Manouk H, Marleen Sande, et al. Magnetic resonance imaging of the Sacroiliac joints indicating sacroiliitis according to the assessment of spondyloarthritis International Society definition in healthy individuals, runners, and women with postpartum back pain. *Arthritis Rheumatol.* 2018;70(7):1042–1048.
- Barnsley L, Paiva J, Barnsley L. Frequency of pertinent MRI abnormalities of the sacroiliac joints of patients without spondyloarthropathies: a systematic review of the literature. *Skeletal Radiol.* 2021;50(9):1741–1748.
- Eshed I, Hadar MR, Mordec D, et al. Peripartum changes of the sacroiliac joints on MRI: increasing mechanical load correlating with signs of edema and inflammation kindling spondyloarthritis in the genetically prone. *Clin Rheumatol.* 2015;34(8):1419–1426.
- Lee KA, Lee, SY, Kim SH, et al. Computed tomography-based assessment of radiographic progression in spine and sacroiliac joints after pregnancy in women with ankylosing spondylitis. *Front Med.* 2022;15:9:970546.
- Visser L, Nigssen PG, Tijssen CC, et al. Sciatica-like symptoms and the sacroiliac joint: clinical features and differential diagnosis. *Eur Spine J.* 2013;22(7):1657–1664.
- Buell U. The scintigraphic investigation of sacroiliac disease. *J Nucl Med.* 1977;18(12):1241–1242.
- Kaçar G, Kacar C, Karayalcin B, et al. Quantitative sacroiliac joint scintigraphy in normal subjects and patients with sacroiliitis. *Ann Nucl Med.* 1998;12(3):169–173.
- Tiwari BP, Basu S. Estimation of sacroiliac joint index in normal subjects of various age groups: comparative evaluation of four different methods of quantification in skeletal scintigraphy. *Nucl Med Rev Cent East Eur.* 2013;16(1):26–30.
- Chang ST, Ku CH, Shiou CC, et al. Evidence- based correlation between anti- streptolysin O serum titer and sacroiliac joint disorder. *J Rheumatol.* 2007;34(8):1746–1752.
- Lin WY, Wang SJ. Influence of age and gender on quantitative sacroiliac joint scintigraphy. *J Nucl Med.* 1998;39(7):1269–1272.
- Lee K, Kim H, Kim YI, et al. Preliminary study for quantitative assessment of sacroiliitis activity using bone SPECT/CT: comparison of diagnostic performance of quantitative parameters. *Nucl Med Mol Imaging.* 2022;56(6):282–290.
- Schörner W, Haubold U. Methodological problems of sacroiliac joint scintigraphy (author's transl). *Nuklearmedizin.* 1981;20(5):241–246.
- Domeij NB, Kjallman, Nylen O, et al. The reliability of quantitative bone scanning in sacroiliitis. *Scand J Rheumatol.* 1980;9(2):77–79.
- Pfannenstiel P, Semmler U, Adam A, et al. Comparative study of quantitating 99m Tc-EHDP uptake in sacroiliac scintigraphy. *Eur J Nucl Med.* 1980;5(1):49–55.
- Chase WF, Houk RW, Winn RE, et al. The clinical usefulness of radionuclide scintigraphy in suspected sacroiliitis: a prospective study. *Br J Rheumatol.* 1983;22(2):67–72.
- Lowe J, Schachner E, Hirschberg E, et al. Significance of bone scintigraphy in symptomatic spondylolysis. *Spine (Phila Pa 1976).* 1984;9(6):653–655.
- Fam AG, Rubenstein JD, Chang HC, et al. Computed tomography in the diagnosis of early ankylosing spondylitis. *Arthritis Rheum.* 1985;28(8):930–937.
- Collie D, Smith GW, Merrick MV, et al. 99mTc-MDP scintigraphy in ankylosing spondylitis. *Clin Radiol.* 1993;48(6):392–397.
- Koç ZP, Cengiz Ak, Aydin F, et al. Sacroiliac indices increase the specificity of bone scintigraphy in the diagnosis of sacroiliitis. *Mol Imaging Radionucl Ther.* 2015;24(1):8–14.
- Liu TJ, Chnag CC, Chen LC, et al. Relationship of HS CRP and sacroiliac joint inflammation in undifferentiated spondyloarthritis. *Open Med (Wars).* 2018;13(1):113–118.
- Ran J, Morelli JN, Xie R, et al. Role for imaging in spondyloarthritis. *Quar J Nucl Med Mol Imaging.* 2017;61(3):271–282.
- Zhang P, Ku KH, Guo RM, et al. A novel diagnostic method (spectral computed tomography of sacroiliac joints) for axial spondyloarthritis. *J Formos Med Assoc.* 2016;115(8):658–664.

36. Ornila E, Sancho L, Beorlegui C, et al. Diagnostic value of quantitative SPECT/CT in assessing active sacroiliitis in patients with axial spondylarthritis and/or inflammatory low back pain. *An Sist Sanit Navar*. 2022;45(1):e0953.
37. Song I, Fernandez JC, Rudwaleit M, et al. The diagnostic value of scintigraphy in assessing sacroiliitis in ankylosing spondylitis: a systematic literature research. *Ann Rheum Dis*. 2008;67(11):1535–1540.
38. Parperis K, Psarellis S, Nikiphorou E, et al. Osteitis condensans ilii: current knowledge and diagnostic approach. *Rheumatol Int*. 2020;40(7):1013–1019.
39. Lokhande SD, Dhaniwala N. Osteitis Condensans Ilii: A Case Report. *Cureus*. 2023;15(10):e47504.
40. Jenks K, Meikle G, Gray A, et al. Osteitis condensans ilii: a significant association with sacroiliac joint tenderness in women. *Int J Rheum Dis*. 2009;12(1):39–43.
41. Lemmens AJ et al. Radiological and scintigraphic findings in patients with a clinical history of chronic inflammatory back pain. *Skeletal Radiol*. 1985;14(4):243–248.
42. Mitra R. Osteitis condensans ilii. *Rheumatol Int*. 2010;30(3):293.
43. Gemmel F, Coningh AV, Collins J, et al. SPECT/CT of osteitis condensans ilii: one-stop shop imaging. *Clin Nucl Med*. 2011;36(1):59–61.
44. Borlandelli E, Ciaffi J, Festuccia G, et al. Osteitis condensans ilii: prevalence and characteristics of a neglected mimic of sacroiliitis. *Clin Rheumatol*. 2022;41(2):483–490.
45. Chang ST. Relief of sciatica after sacroiliac joint injection in a female with osteitis condensans ilii. *Asia Life Sci*. 2016;25(1):515–519.
46. Mackie S, Keat A. Poststreptococcal reactive arthritis: what is it and how do we know? *Rheumatology (Oxford)*. 2004;43(8):949–954.
47. Sarakbi HA, Hammoudeh M, Kanjar I, et al. Poststreptococcal reactive arthritis and the association with tendonitis, tenosynovitis, and enthesitis. *J Clin Rheumatol*. 2010;16(1):3–6.
48. Uziel Y, Perl L, Barash J, et al. Post-streptococcal reactive arthritis in children: a distinct entity from acute rheumatic fever. *Pediatr Rheumatol Online*. 2011;9(1):32.
49. Visser H, Speyer I, Breedveld FC, et al. The diagnostic value of streptococcal serology in early arthritis: a prospective cohort study. *Rheumatology (Oxford)*. 2000;39(12):1351–1356.
50. Ayoub EM, Nelson B, Shulman ST, et al. Group A streptococcal antibodies in subjects with or without rheumatic fever in areas with high or low incidences of rheumatic fever. *Clin Diagn Lab Immunol*. 2003;10(5):886–890.
51. Kotby AA, Habeeb NM, Elarab SE, et al. Antistreptolysin O titer in health and disease: levels and significance. *Pediatr Rep*. 2012;4(1):25–29.
52. Martino D, Giovannoni G. Autoaggressive immune-mediated movement disorders. *Adv Neurol*. 2005;96:320–335.
53. Chang CC, Chu HY, Chiang SL, et al. Impairment of static upright posture in subjects with undifferentiated arthritis in sacroiliac joint in conjunction with elevation of streptococcal serology. *J Back Musculoskelet Rehabil*. 2009;22(1):33–41.
54. Lu SC, Chenm LC, Chiang SL, et al. Orthostatic postural deficit in subjects with streptococcal serology-related unclassified arthritis of the lumbopelvis. *Tw J Phys Med Rehabil*. 2010;38(1):1–9. (In Chinese)
55. Chang CC. Improvement of sacroiliac joint stress bottom-up after convalesce of foot periostitis: a randomized controlled trial. *Asia Life Sci*. 2016;25(1):137–149.
56. Su HY, Hu AN, Hsu WC, et al. Effects of low power laser on pain and balance dysfunction caused by periostitis of lower limb: a case series. *Tw J Phys Med Rehabil*. 2013;41(1):51–57. (In Chinese).
57. Chang CC, Ku CH, Hsu WC, et al. Five-day, low-level laser therapy for sports-related lower extremity periostitis in adult men: a randomized, controlled trial. *Lasers Med Sci*. 2014;29(4):1485–1494.
58. Chen CL, Chuang HY, Chnag CC, et al. Randomized controlled trial of laser therapy versus conventional therapy in the treatment of medial tibial stress syndrome. *Int J Orthop Rehabil*. 2016;3(2):43–50.