

屏東榮民總醫院

子宮頸癌診療原則

2024年 第一版 2024/02/07

婦癌醫療團隊擬訂

注意事項

這個診療原則主要作為醫師和其他保健專家診療癌症病人參考之用。假如你是一個癌症病人，直接引用這個診療原則並不恰當，只有你的醫師才能決定給你最恰當的治療。

修訂指引

- 本共識依下列參考資料修改版本
 - NCCN Clinical Practical Guidelines in Oncology™ Cervical Cancer (V1 2024)⁽¹⁾
 - 婦癌研究委員會(2011)，子宮頸癌篩檢臨床指引與子宮頸癌臨床指引：國家衛生研究院⁽²⁻³⁾
 - 其他相關子宮頸癌臨床指引⁽⁴⁻¹⁰⁾

會議討論

上次會議：-

本共識與上一版的差異 (與高榮婦產科子宮頸癌指引相比)

新版

1. 捨棄沿用多年的指引，因近年NCCN guideline針對各分期以及LVSI狀態已有更詳細的治療差異。
2. 將哨兵淋巴結顯影定位及切除納入指引中。

2018 FIGO Staging

Box 1

Stage I:

The carcinoma is strictly confined to the cervix (extension to the corpus should be disregarded).

- **IA** Invasive carcinoma that can be diagnosed only by microscopy with maximum depth of invasion ≤ 5 mm^a
 - **IA1** Measured stromal invasion ≤ 3 mm in depth
 - **IA2** Measured stromal invasion >3 mm and ≤ 5 mm in depth
- **IB** Invasive carcinoma with measured deepest invasion >5 mm (greater than stage IA); lesion limited to the cervix uteri with size measured by maximum tumor diameter^b
 - **IB1** Invasive carcinoma >5 mm depth of stromal invasion and ≤ 2 cm in greatest dimension
 - **IB2** Invasive carcinoma >2 cm and ≤ 4 cm in greatest dimension
 - **IB3** Invasive carcinoma >4 cm in greatest dimension

Stage II:

The cervical carcinoma invades beyond the uterus, but has not extended onto the lower third of the vagina or to the pelvic wall

- **IIA** Involvement limited to the upper two-thirds of the vagina without parametrial invasion
 - **IIA1** Invasive carcinoma ≤ 4 cm in greatest dimension
 - **IIA2** Invasive carcinoma >4 cm in greatest dimension
- **IIB** With parametrial invasion but not up to the pelvic wall

Stage III:

The carcinoma involves the lower third of the vagina and/or extends to the pelvic wall and/or causes hydronephrosis or non-functioning kidney and/or involves pelvic and/or paraaortic lymph nodes

- **IIIA** Carcinoma involves lower third of the vagina, with no extension to the pelvic wall
- **IIIB** Extension to the pelvic wall and/or hydronephrosis or non-functioning kidney (unless known to be due to another cause)
- **IIIC** Involvement of pelvic and/or paraaortic lymph nodes (**including micrometastases**)^c, irrespective of tumor size and extent (with r and p notations).^d
 - **IIIC1** Pelvic lymph node metastasis only
 - **IIIC2** Paraaortic lymph node metastasis

Stage IV:

The carcinoma has extended beyond the true pelvis or has involved (biopsy proven) the mucosa of the bladder or rectum. A bullous edema, as such, does not permit a case to be allotted to stage IV

- **IVA** Spread of the growth to adjacent organs
- **IVB** Spread to distant organs

• ^aImaging and pathology can be used, when available, to supplement clinical findings with respect to tumor size and extent, in all stages.
Pathological findings supercede imaging and clinical findings.

• ^bThe involvement of vascular/lymphatic spaces should not change the staging. The lateral extent of the lesion is no longer considered.

• ^cIsolated tumor cells do not change the stage but their presence should be recorded

• ^dAdding notation of r (imaging) and p (pathology), to indicate the findings that are used to allocate the case to stage IIIC. For example, if imaging indicates pelvic lymph node metastasis, the stage allocation would be Stage IIIC1r; if confirmed by pathological findings, it would be Stage IIIC1p. The type of imaging modality or pathology technique used should always be documented. When in doubt, the lower staging should be assigned.

AJCC Cancer Staging System – Cervical Cancer Version 9

T Category	FIGO Stage	T Criteria
TX		Primary tumor cannot be assessed
T0		No evidence of primary tumor
T1	I	Carcinoma is strictly confined to the cervix (extension to the corpus should be disregarded).
T1a	IA	Invasive carcinoma that can be diagnosed only by microscopy with maximum depth of invasion ≤ 5 mm
T1a1	IA1	Measured stromal invasion ≤ 3 mm in depth
T1a2	IA2	Measured stromal invasion > 3 mm and ≤ 5 mm in depth
T1b	IB	Invasive carcinoma with measured deepest invasion > 5 mm (greater than stage IA); lesion limited to the cervix uteri with size measured by maximum tumor diameter Note: The involvement of vascular/lymphatic spaces should not change the staging. The lateral extent of the lesion is no longer considered.
T1b1	IB1	Invasive carcinoma > 5 mm depth of stromal invasion and ≤ 2 cm in greatest dimension
T1b2	IB2	Invasive carcinoma > 2 cm and ≤ 4 cm in greatest dimension
T1b3	IB3	Invasive carcinoma > 4 cm in greatest dimension
T2	II	Carcinoma invades beyond the uterus, but has not extended onto the lower third of the vagina or to the pelvic wall
T2a	IIA	Involvement limited to the upper two-thirds of the vagina without parametrial invasion
T2a1	IIA1	Invasive carcinoma ≤ 4 cm in greatest dimension
T2a2	IIA2	Invasive carcinoma > 4 cm in greatest dimension
T2b	IIB	With parametrial invasion but not up to the pelvic wall
T3	III	Carcinoma involves the lower third of the vagina and/or extends to the pelvic wall and/or causes hydronephrosis or nonfunctioning kidney Note: The pelvic wall is defined as the muscle, fascia, neurovascular structures, and skeletal portions of the bony pelvis. Cases with no cancer-free space between the tumor and pelvic wall by rectal examination are FIGO III.
T3a	IIIA	Carcinoma involves lower third of the vagina, with no extension to the pelvic wall
T3b	IIIB	Extension to the pelvic wall and/or hydronephrosis or nonfunctioning kidney (unless known to be due to another cause)
T4	IVA	Carcinoma has involved (biopsy-proven) the mucosa of the bladder or rectum, or has spread to adjacent organs. (Bullous edema, as such, does not permit a case to be assigned to stage IVA.)

AJCC Cancer Staging System – Cervical Cancer Version 9

N Category	FIGO Stage	N Criteria
NX		Regional lymph nodes cannot be assessed
N0		No regional lymph node metastasis
N0(i+)		Isolated tumor cells in regional lymph node(s) ≤ 0.2 mm, or single cells or clusters of cells ≤ 200 cells in a single lymph node cross section
N1	IIIC1	Regional lymph node metastasis to pelvic lymph nodes only
N1mi	IIIC1	Regional lymph node metastasis (>0.2 mm but ≤ 2.0 mm in diameter) to pelvic lymph nodes
N1a	IIIC1	Regional lymph node metastasis (>2.0 mm in diameter) to pelvic lymph nodes
N2	IIIC2	Regional lymph node metastasis to para-aortic lymph nodes, with or without positive pelvic lymph nodes
N2mi	IIIC2	Regional lymph node metastasis (>0.2 mm but ≤ 2.0 mm in diameter) to para-aortic lymph nodes, with or without positive pelvic lymph nodes
N2a	IIIC2	Regional lymph node metastasis (>2.0 mm in diameter) to para-aortic lymph nodes, with or without positive pelvic lymph nodes

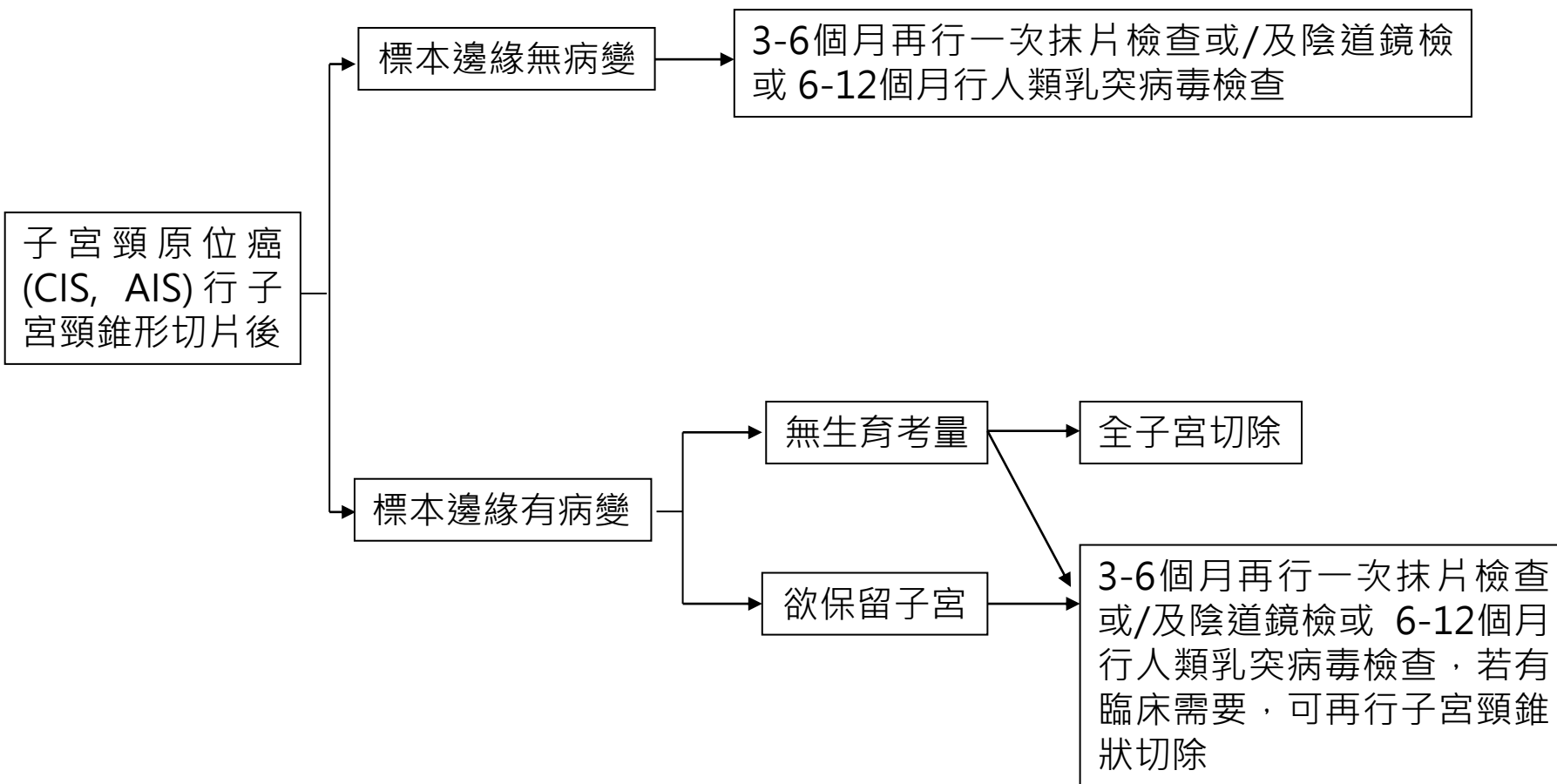
Note: Suffix (f) is added to the N category when metastasis is identified only by FNA or core biopsy. Suffix (sn) is added to the N category when metastasis is identified only by sentinel lymph node biopsy.

M Category	FIGO Stage	M Criteria
M0		No distant metastasis
cM1	IVB	Distant metastasis (includes metastasis to inguinal lymph nodes, intraperitoneal disease, lung, liver, or bone) (excludes metastasis to pelvic or para-aortic lymph nodes, or vagina)
pM1	IVB	Microscopic confirmation of distant metastasis (includes metastasis to inguinal lymph nodes, intraperitoneal disease, lung, liver, or bone) (excludes metastasis to pelvic or para-aortic lymph nodes, or vagina)

AJCC Cancer Staging System – Cervical Cancer Version 9

When T is...	And N is...	And M is...	Then the stage group is...
T1	N0	M0	I
T1a	N0	M0	IA
T1a1	N0	M0	IA1
T1a2	N0	M0	IA2
T1b	N0	M0	IB
T1b1	N0	M0	IB1
T1b2	N0	M0	IB2
T1b3	N0	M0	IB3
T2	N0	M0	II
T2a	N0	M0	IIA
T2a1	N0	M0	IIA1
T2a2	N0	M0	IIA2
T2b	N0	M0	IIB
T3	N0	M0	III
T3a	N0	M0	IIIA
T3b	N0	M0	IIIB
TX, T0, T1-3	N1	M0	IIIC1
TX, T0, T1-3	N2	M0	IIIC2
T4	Any N	M0	IVA
Any T	Any N	M1	IVB

原位癌行子宮頸錐狀切片

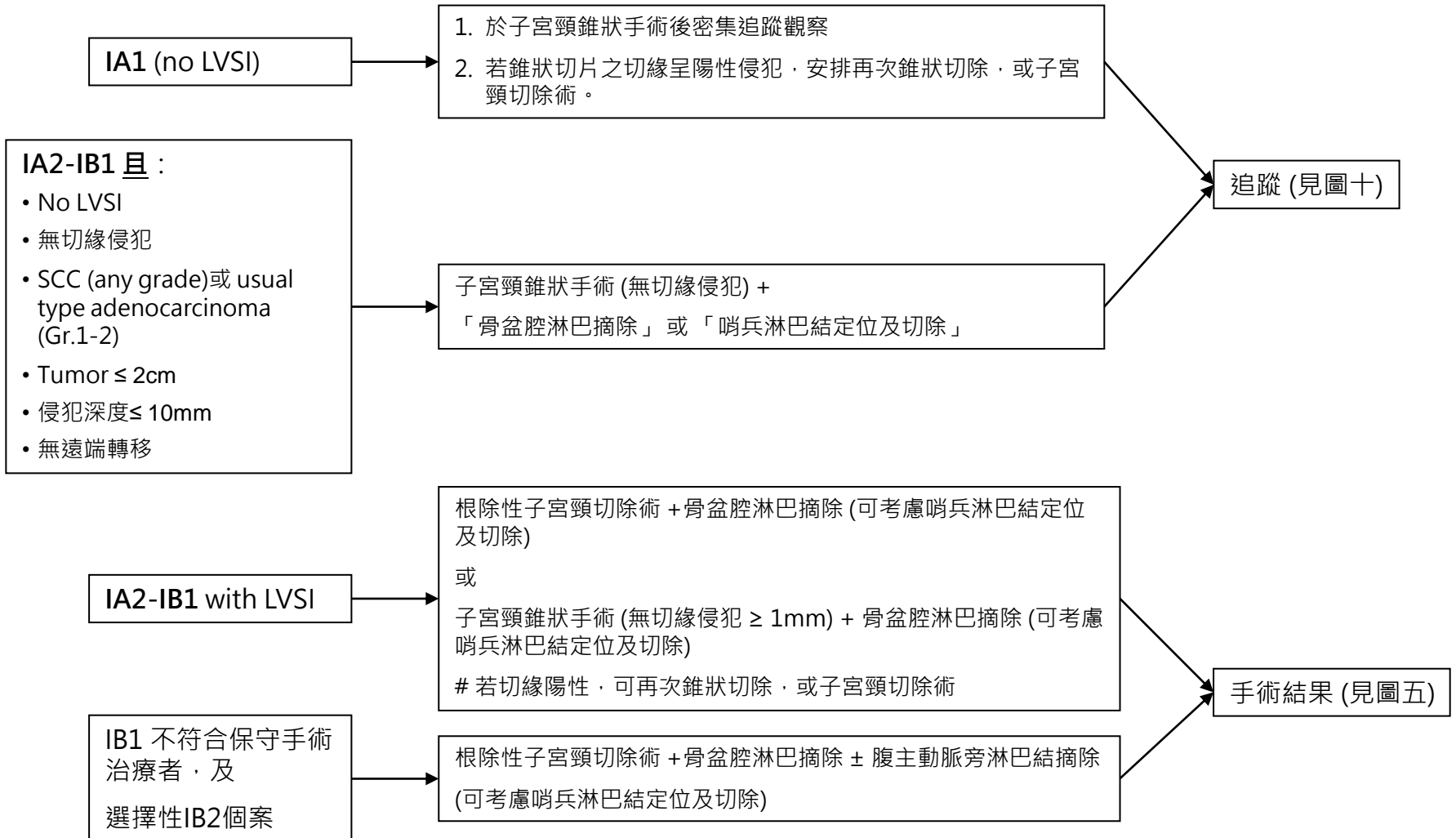


屏東榮總婦癌團隊 子宮頸癌臨床治療指引 (欲保存生育能力)

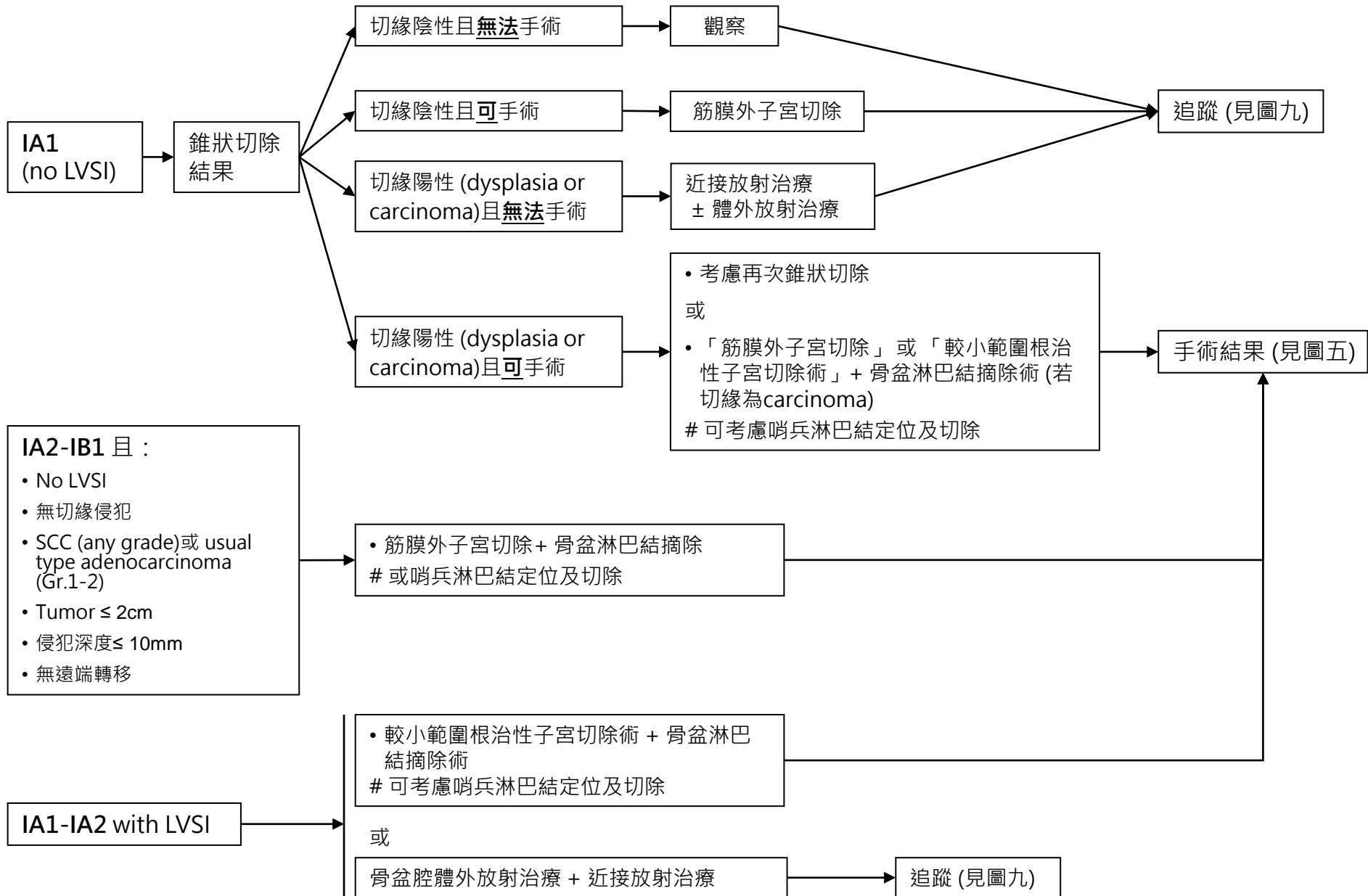
子宮頸癌治療流程 (以下分期為FIGO 2018)

治療前檢查：1. 病史及理學檢查*；2. 全血球計數；3. 子宮頸切片之組織病理檢查；4. 子宮頸錐狀手術+子宮頸管搔刮術(當子宮頸切片之組織病理檢查結果為微侵襲癌者)；5. 胸部X光*；6. 分期為IA者，可考慮骨盆核磁共振；分期高於IA者，安排腹部或骨盆電腦斷層*或核磁共振*(52)；7. 常規生化檢驗；8. 血清腫瘤標記檢驗(鱗狀細胞癌者:SCC、CEA；腺癌者:CEA、CA-125、CA-199)

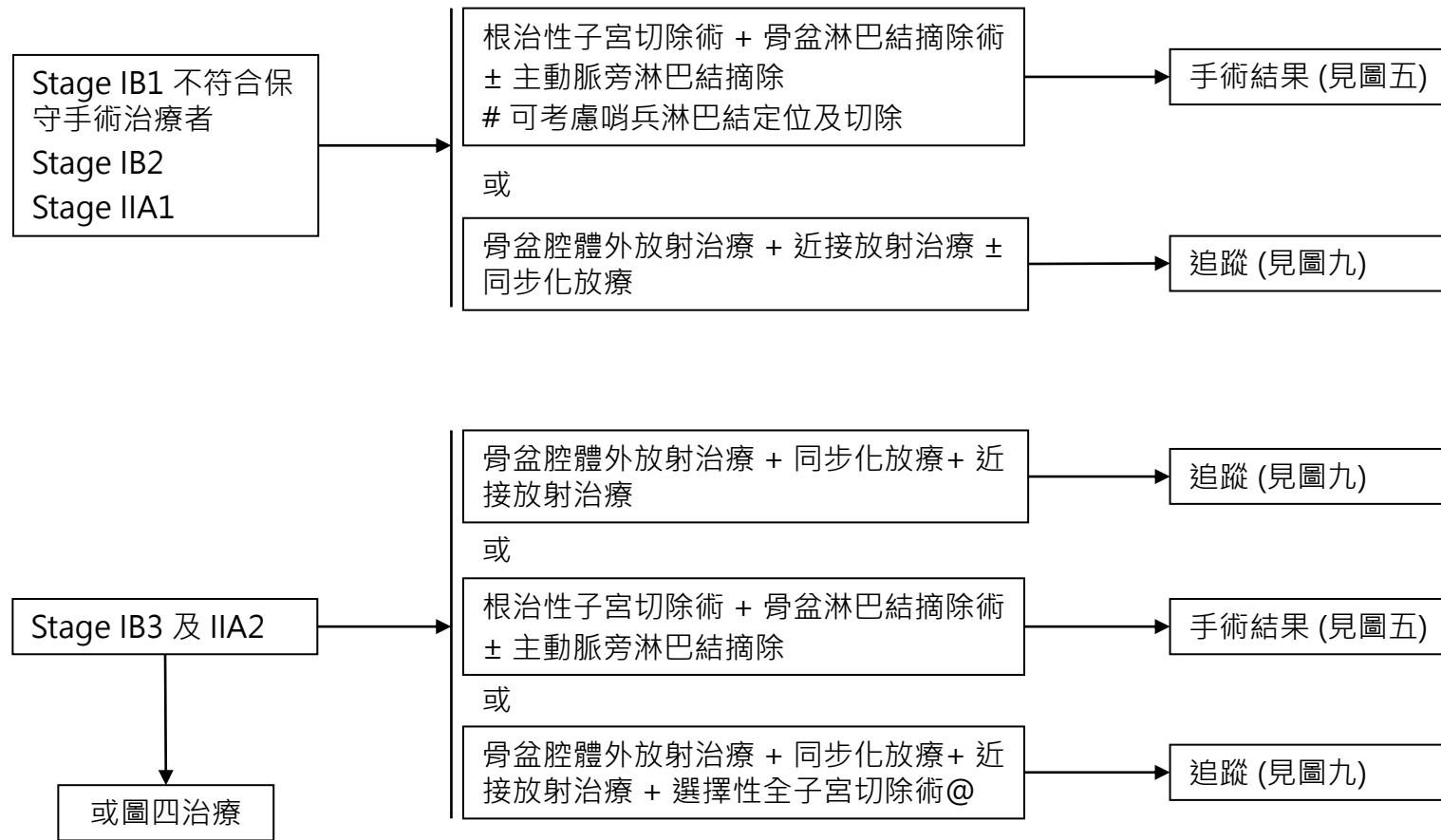
選擇性檢查：#分期為IB2或以上者，膀胱或直腸鏡檢；#葡萄糖正子攝影 *與期別相關之主要檢查(必要項目)



屏東榮總婦癌團隊 子宮頸癌臨床治療指引 (不保存生育能力)

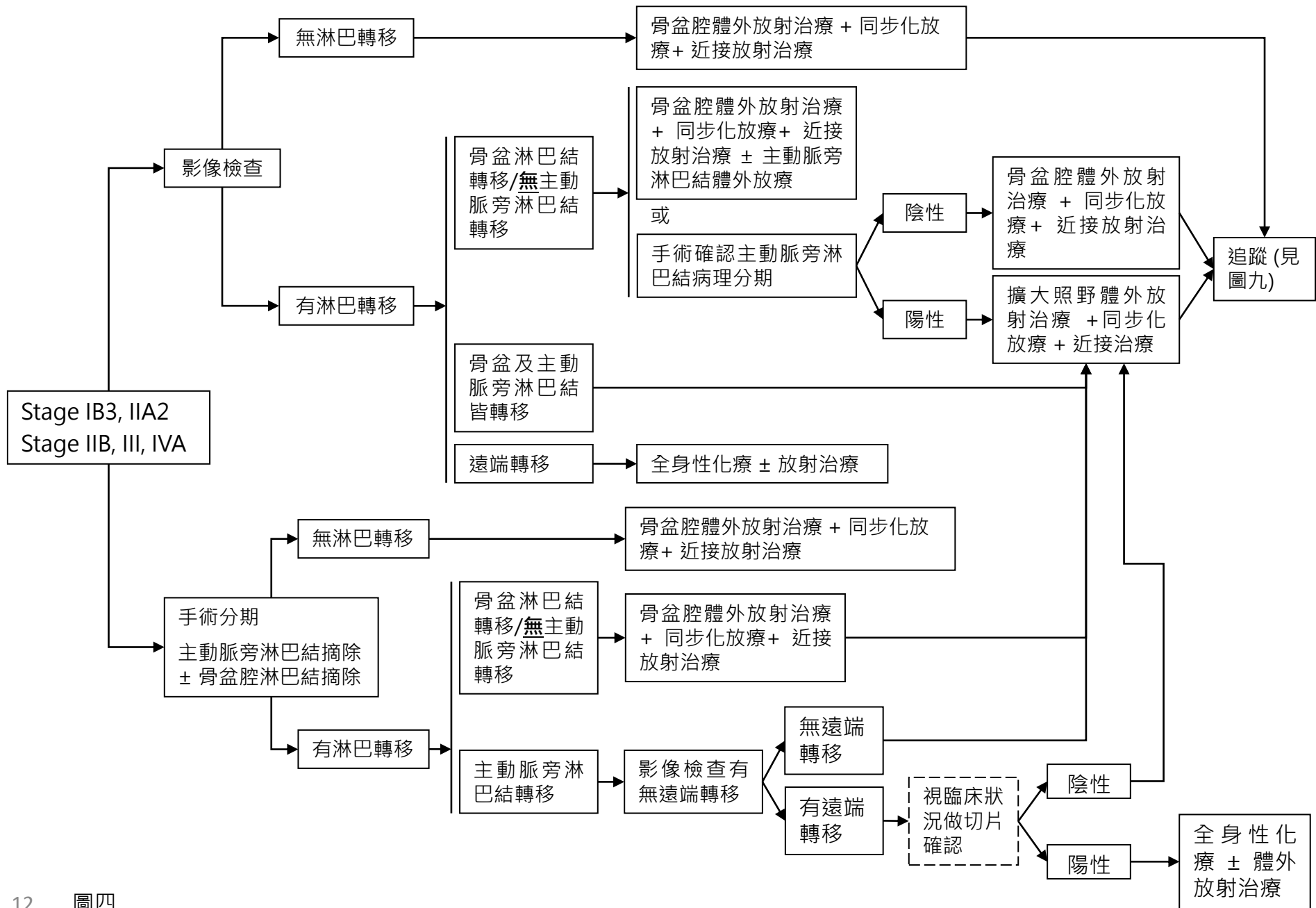


屏東榮總婦癌團隊 子宮頸癌臨床治療指引 (不保存生育能力)



@: 僅適用於腫瘤對RT及CCRT後反應不佳的患者

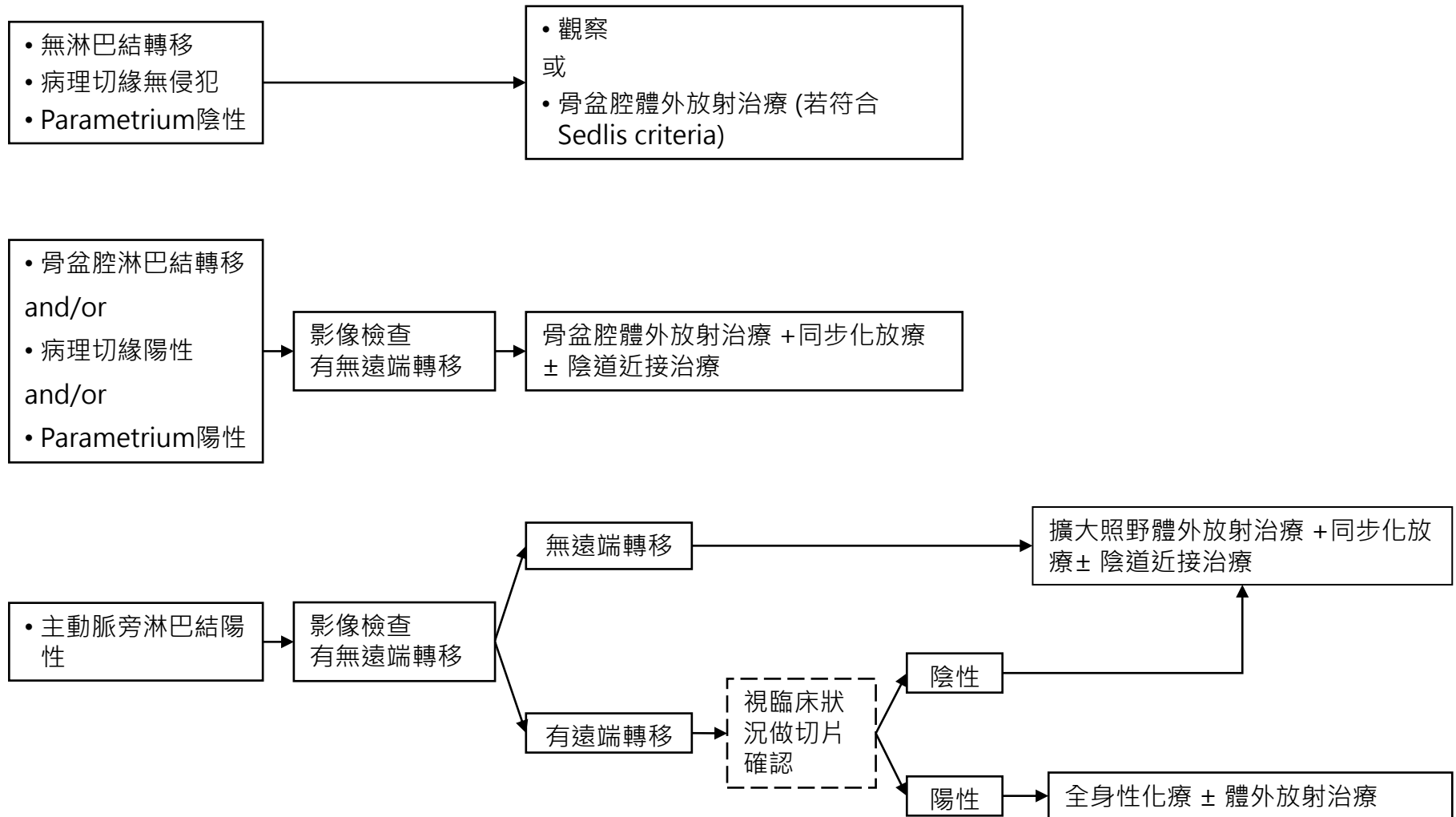
屏東榮總婦癌團隊 子宮頸癌臨床治療指引 (不保存生育能力)



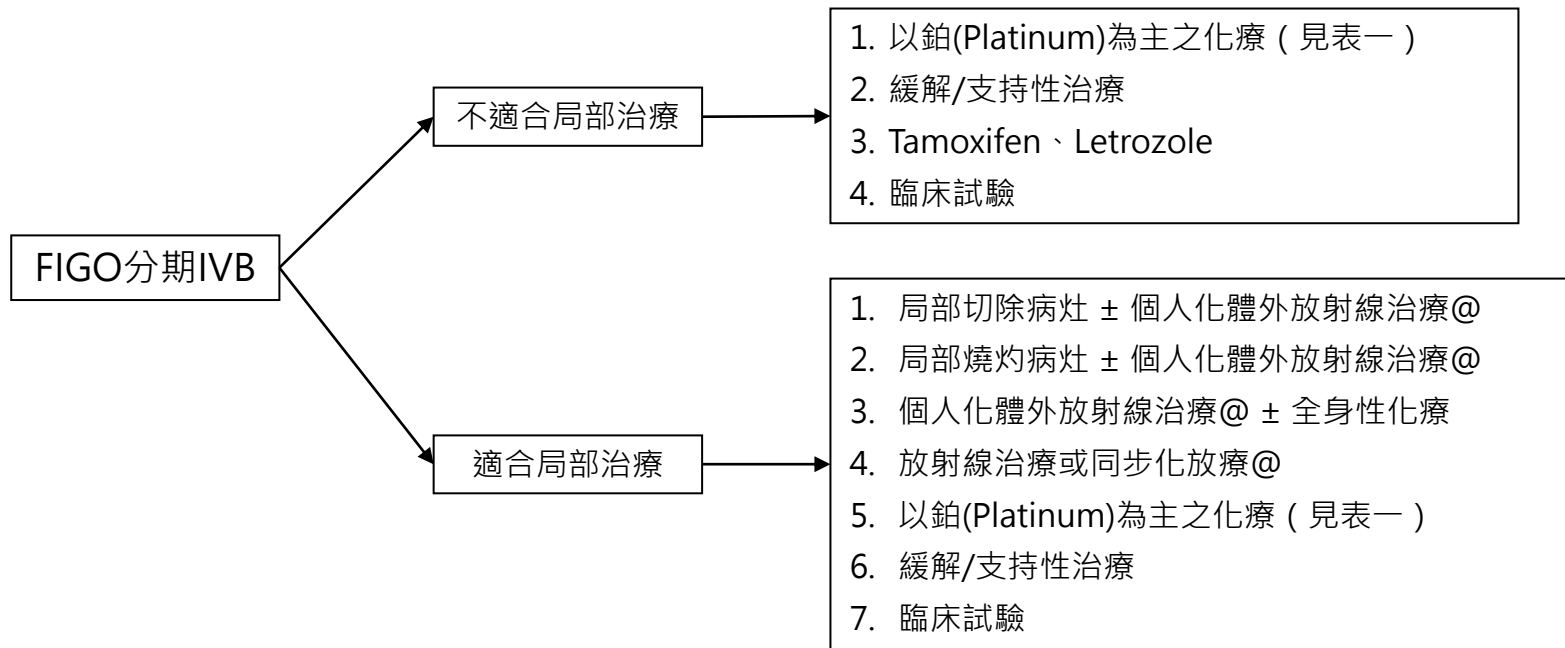
屏東榮總婦癌團隊 子宮頸癌臨床治療指引

手術結果

輔助治療

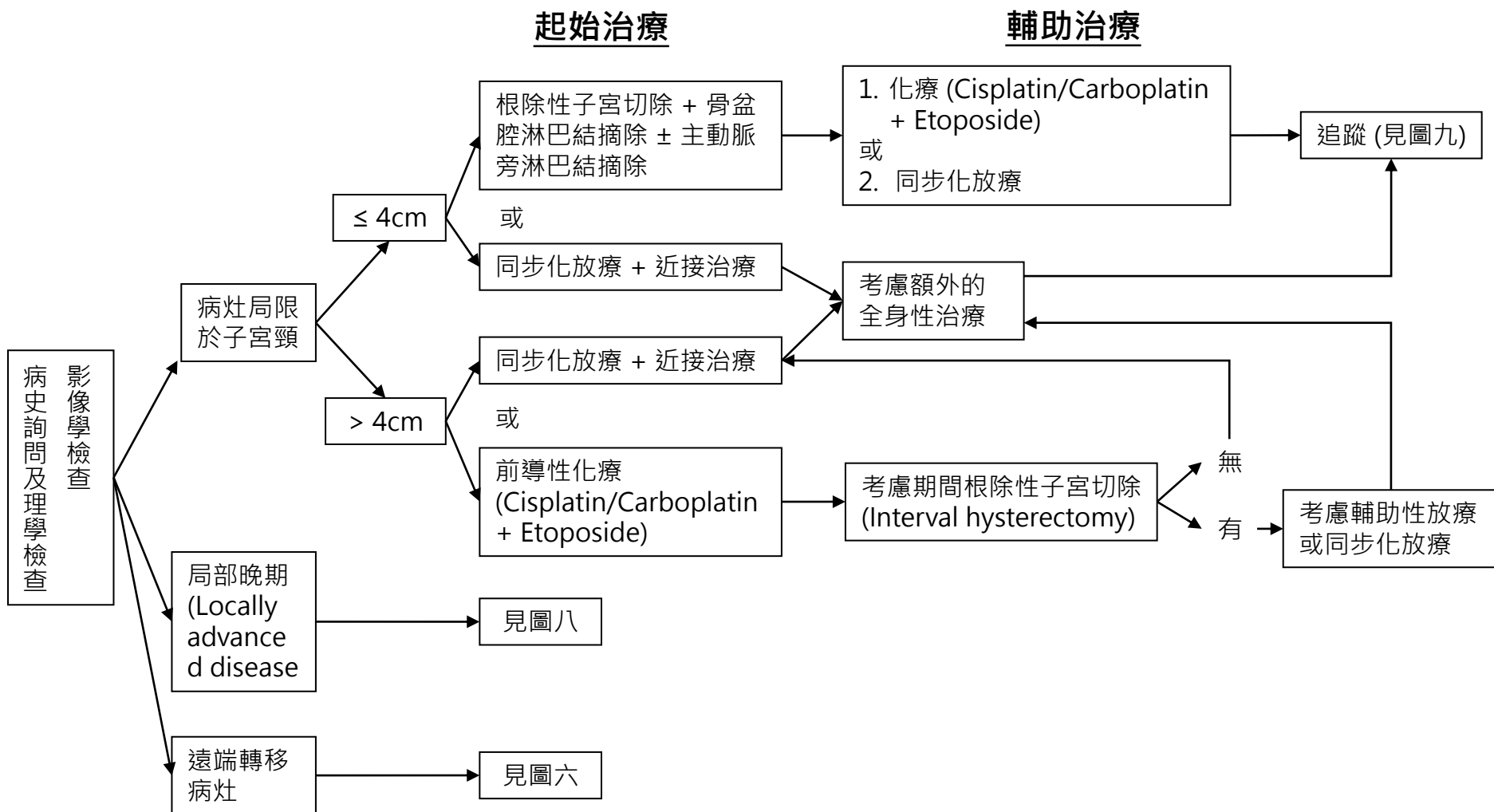


FIGO分期IVB或遠端轉移子宮頸癌治療流程

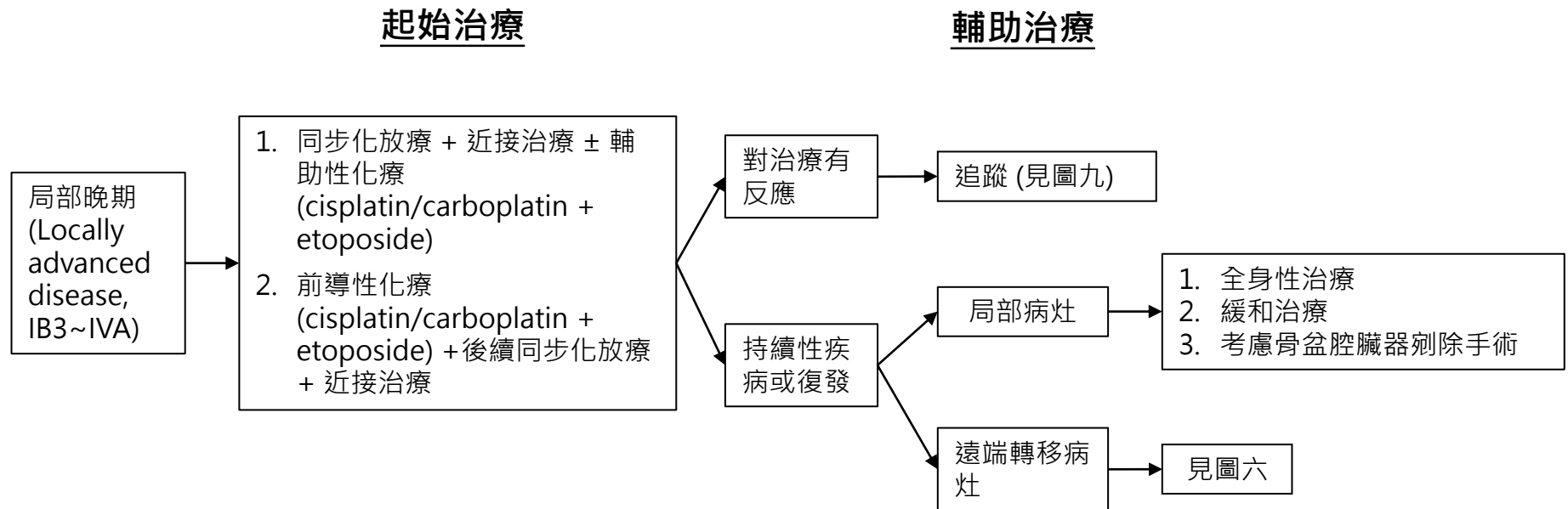


@ : 放射治療或同步化放療請見放射腫瘤部治療指引

小細胞神經內分泌癌之治療流程



局部晚期(Locally advanced, IB3~IVA)小細胞神經內分泌癌之治療流程



子宮頸癌治療後追蹤及復發的處置

定期追蹤方法

1. 理學檢查
2. 抹片檢查：治療後兩年內每三個月一次，第三年每四~六個月一次，第四至五年每六個月一次，以後每年一次
3. 腫瘤標記(鱗狀細胞癌者:SCC, CEA；腺癌者:CEA, CA-125, CA-199)
4. 全血(CBC)及腎功能(BUN、Cr)檢驗，有必要時可每六個月檢驗一次
5. 胸部X光檢查每年一次及電腦斷層檢查，有必要時可每年安排檢查一次

懷疑持續性
或
復發性疾病

進一步檢查

1. 骨盆及腹部電腦斷層檢查
2. 胸部X光檢查(若為陰性，仍高度懷疑胸部轉移則考慮胸部電腦斷層檢查)
3. 若有病灶，技術可行下，考慮直接切片或超音波或電腦斷層導引下切片
4. 安排正子掃描 (31-35)
5. 有必要時可以施行手術探查
6. 考慮廣泛型癌症基因檢測 (comprehensive genomic profiling, CGP)
7. 若無法取得病理組織，考慮檢測血漿循環腫瘤DNA (plasma ctDNA) 之廣泛型癌症基因檢測 (CGP)

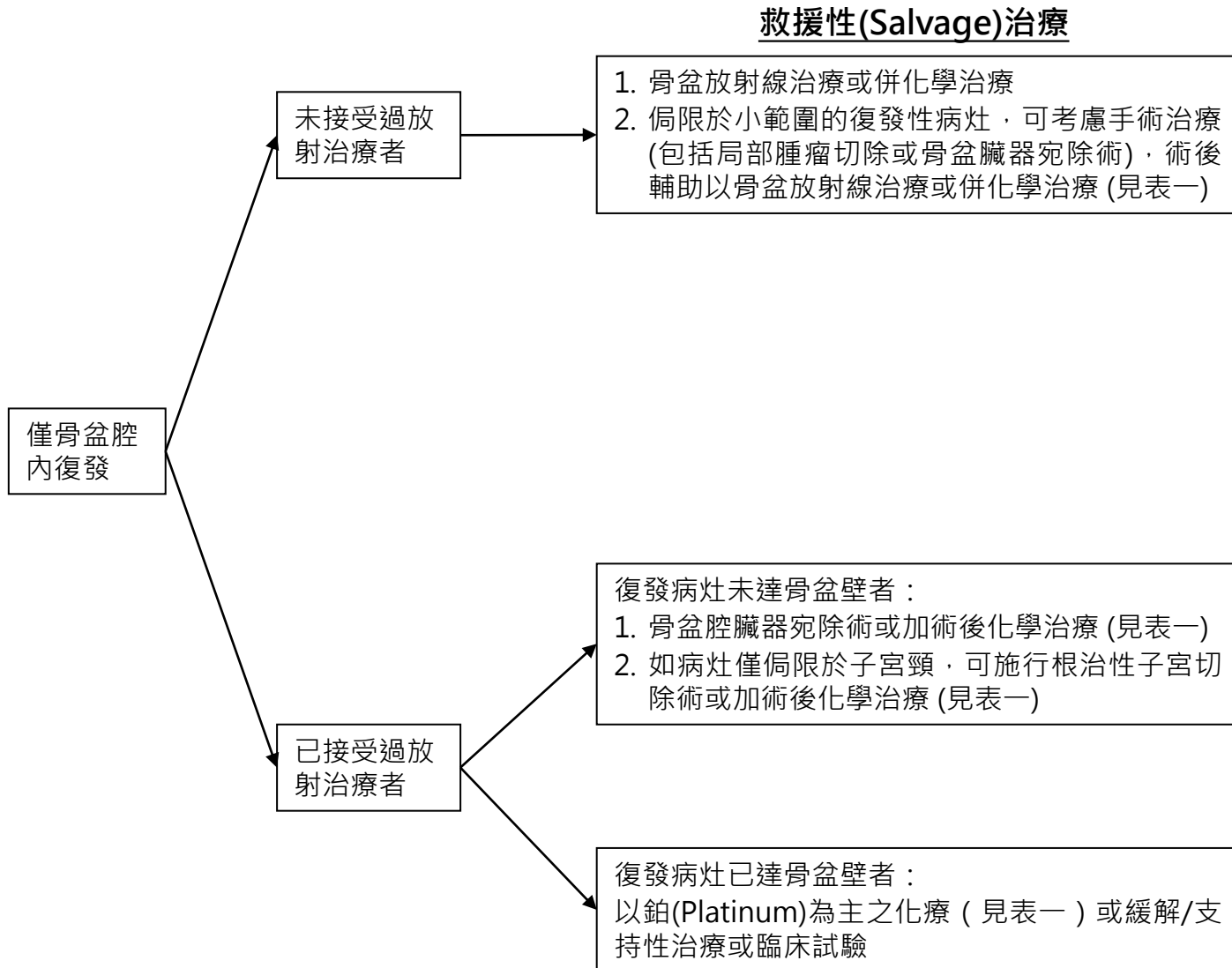
僅骨盆腔
內復發

見圖十

骨盆腔外
復發

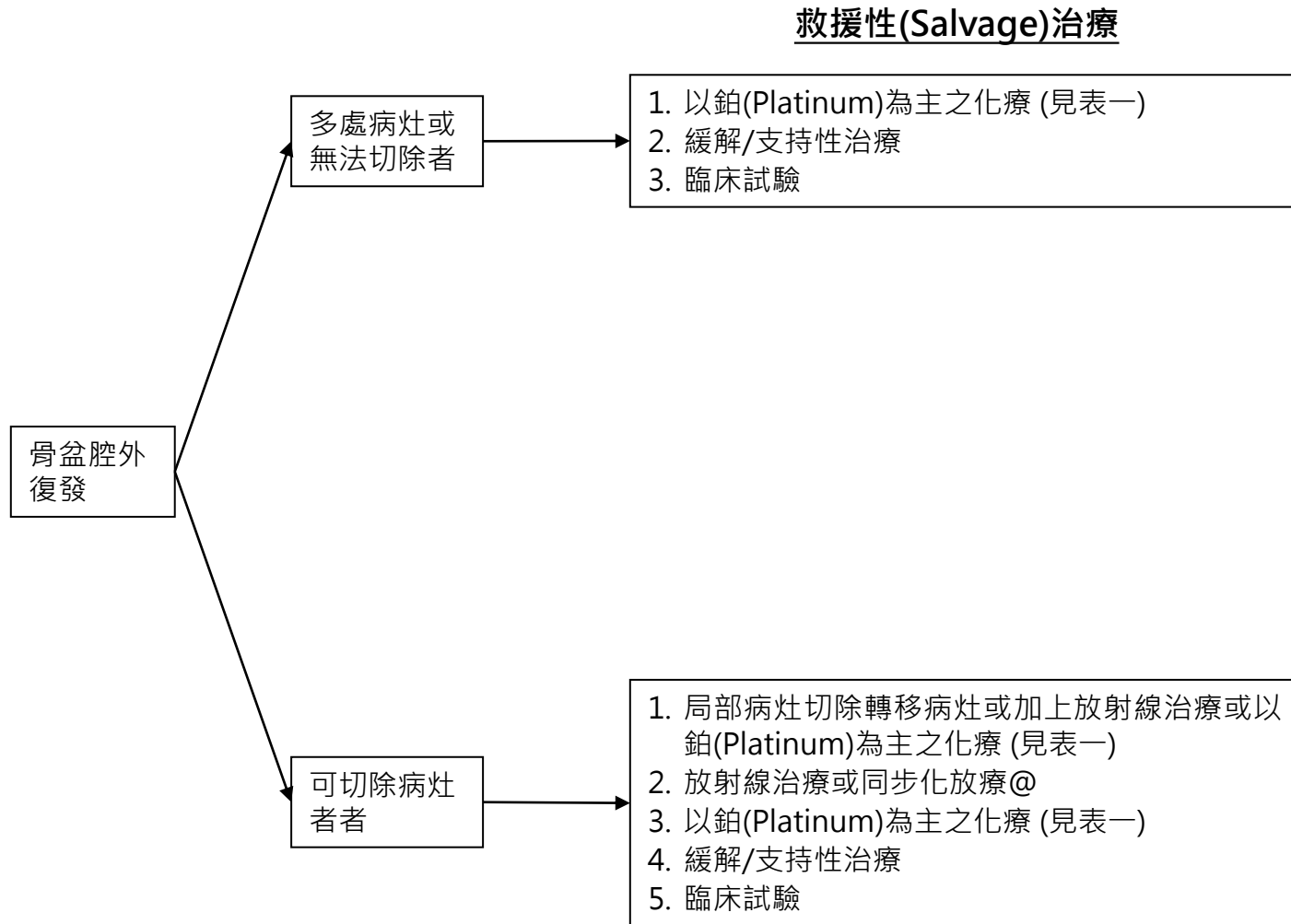
見圖十一

子宮頸癌治療後追蹤及復發的處置



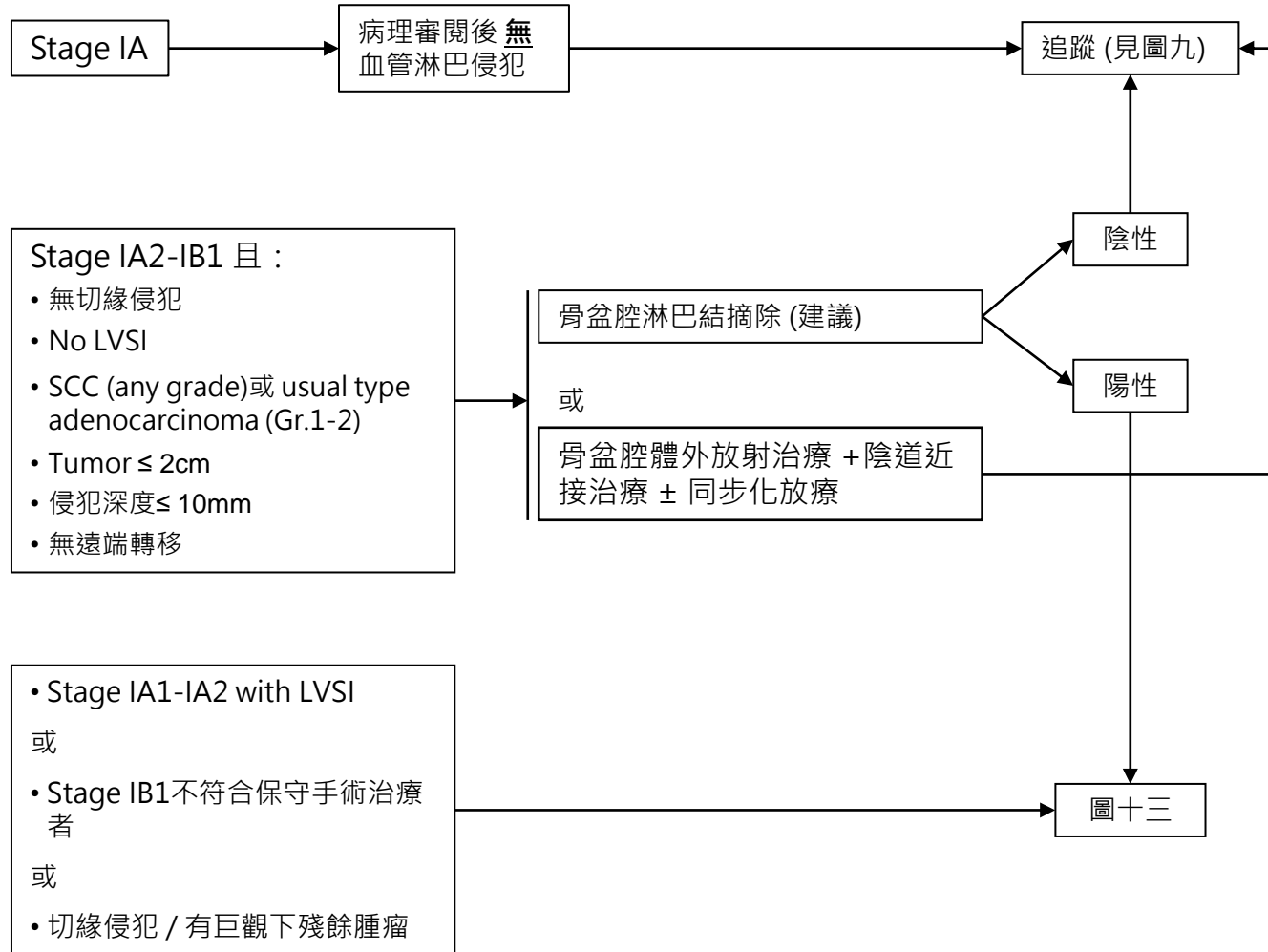
@：放射治療或同步化放療請見放射腫瘤部治療指引

子宮頸癌治療後追蹤及復發的處置

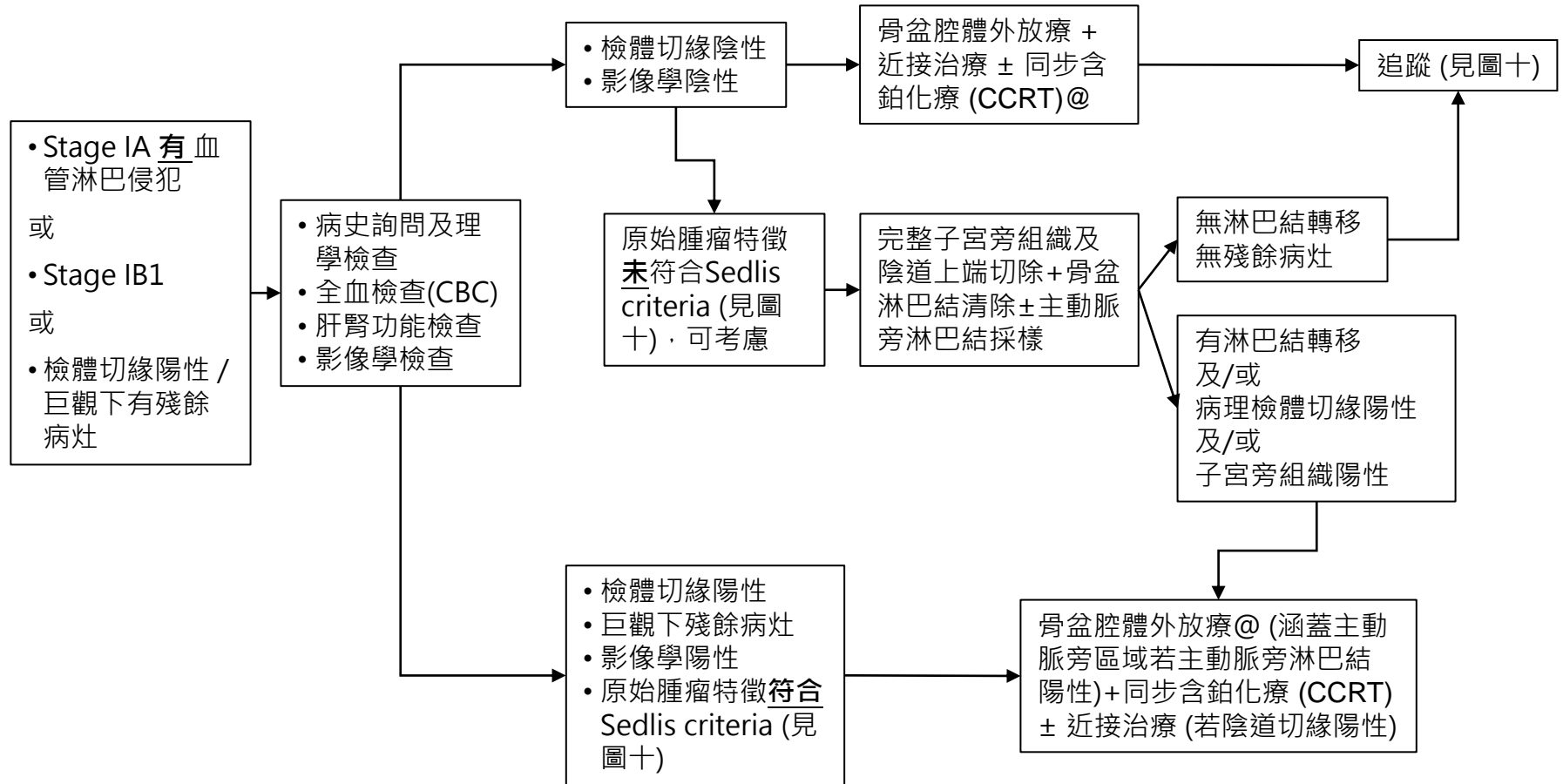


@ : 放射治療或同步化放療請見放射腫瘤部治療指引

單純子宮全切除後意外發現侵襲性癌症



單純子宮全切除後意外發現侵襲性癌症



@: 放射治療或同步化放療請見放射腫瘤部治療指引

**SEDLIS CRITERIA FOR EXTERNAL PELVIC RADIATION AFTER RADICAL HYSTERECTOMY
IN NODE-NEGATIVE, MARGIN-NEGATIVE, PARAMETRIA-NEGATIVE CASES^{a-c,1,2}**

LVSI	Stromal Invasion	Tumor Size (cm) (determined by clinical palpation)
+	Deep 1/3	Any
+	Middle 1/3	≥2
+	Superficial 1/3	≥5
-	Middle or deep 1/3	≥4

LVSI: Lymphovascular space invasion

術前新輔助化學治療：以 platinum-based 為原則，可使用以下的選擇

1. IP (Ifosfamide 4 gm/m² + cisplatin 50mg/m² or carboplatin AUC=5 every 21 days x 3~6 cycles)(48,49)
2. Irinotecan 60mg/m² + cisplatin 50mg/m² or carboplatin AUC=5 every 28 days x 3~6 cycles (optional)(43,47)
3. (IB2-IIIB) Weekly Taxol + Carboplatin(AUC=2) (D1,D8,D15)x 9 cycles(58)

手術後輔助化學治療：以 platinum-based 為原則，可使用以下的選擇

1. IP (Ifosfamide 4 gm/m² + cisplatin 50mg/m² or carboplatin AUC=5 every 21 days x 6 cycles) (38,45,49)

神經內分泌癌手術後輔助化學治療或化放療以 platinum-based 為原則可使用以下的選擇

1. Etoposide + Platinum (Etoposide 100mg/m² + Cisplatin 50mg/m² or Carboplatin AUC =5, every 21 days x 4~6 cycles)

第IV期B·持續性疾病 (persistent disease)復發或轉移性疾病 (recurrent/metastatic disease)之全身性化學治療或免疫療法為原則，可使用以下的選擇

1. Paclitaxel 175mg/m² + cisplatin 50mg/m² or carboplatin AUC=5 every 21 days x 6 cycles)(optional)(GOG 169, GOG 204, level Ib) (51) ± Bevacizumab 7.5~15 mg/kg (GOG 240) (55)
2. Pembrolizumab + Paclitaxel 175mg/m² + cisplatin 50mg/m² or carboplatin AUC=5 every 21 days x 6 cycles)(optional) ± Bevacizumab 7.5~15 mg/kg for PD-L1 (+) tumors (Keynote-826) (65)
3. Topotecan 0.75mg/m² x 3 days + cisplatin 50mg/m² or carboplatin AUC=5 every 21 days x 6 cycles(GOG 179, level Ib) (42) ± Bevacizumab 7.5~15 mg/kg
4. Paclitaxel 175mg/m² (D1)+ topotecan 0.75mg/m² (D1-3) ± Bevacizumab 7.5~15 mg/kg(D1) every 21~28 days (63)
5. IP (ifosfamide 4gm/m²+ cisplatin 50mg/m² or carboplatin AUC=5 every 21 days x 6 cycles)(GOG 110, level Ib)
6. Irinotecan/platinum (Irinotecan 60mg/m² + cisplatin 50mg/m² or carboplatin AUC=5 every 28 days x 6 cycles) (optional) (43,47)
7. Keytruda(Pembrolizumab) for PD-L1(+) or MSI-H/dMMR tumors ((59, 60, 64 (KEYNOTE-028,158))
8. Nivolumab for PD-L1 (+) tumors (66)
9. Irinotecan 125mg/ m² (D1, D8, D15, D22 then rest for D29 and D36, every 6 weeks)
10. Tamoxifen 10mg QD (61,62)
11. Clinical trials

1. CCRT – Cisplatin (40mg/m²)
2. CCRT – Carboplatin (100mg/m²) or AUC =2
3. CCRT – Weekly cisplatin (40mg/m²) + gemcitabine (120mg/m²)
4. P (Carboplatin, AUC =5) C (Cyclophosphamide, 500mg/m²) + VP-16 (100mg/m²) 【CCR <60ml/min】
5. P (Cisplatin, 50mg/m²) C + VP-16 (100mg/m²) 【CCR >60ml/min】
6. **1st Line:** I (Ifosfamide) + Mesna (4gm/m²) + P (Carboplatin, AUC =5) 【CCR <60ml/min】
7. **1st Line:** IP (Cisplatin, 50mg/m²) 【CCR>60ml/min】
8. **2nd Line:** Taxol (175 mg/m², palsef)(D1) + Topotecan (0.75mg/m²)(D1-3)
9. **2nd Line:** Irinotecan (Payself) (60mg/m²) + Carboplatin (AUC =5) (D1)
2nd Line: Irinotecan (Payself) (60mg/m²) + Cisplatin (50mg/m²) (D1)
2nd Line: Irinotecan (Payself) (60mg/m²) (D8 or D15)

10. **2nd Line:** Taxol (Payself) (175mg/m²) + Carboplatin (AUC =5)
【CCR<60ml/min】
11. **2nd Line:** Taxol (Payself) (175mg/m²) + Cisplatin (50mg/m²)
【CCR>60ml/min】
12. **2nd Line:** Topotecan (0.75mg/m²) + Carboplatin (AUC=5) 【CCR <60ml/min】
13. **2nd Line:** Topotecan (0.75mg/m²) + Cisplatin (50mg/m²) 【CCR >60ml/min】
14. Weekly Taxol (80mg/m²) + Cisplatin (20mg/m²) (D1 or D8 or D15)
15. Weekly Taxol (80mg/m²) + Carboplatin (AUC =2) (D1 or D8 or D15)
16. Avastin (Payself) (7.5~15mg/kg)
17. Tamoxifen 10mg QD
18. Pembrolizumab (Keytruda)
19. Nivolumab
20. Irinotecan 125mg/ m² (D1, D8, D15, D22 then rest for D29 and D36, every 6 weeks)

References

1. NCCN Clinical Practice Guideline in Oncology™ – Cervical Cancer (V1. 2024)
2. TGOG子宮頸癌篩檢指引 2007年版, 國家衛生研究院
3. TGOG子宮頸癌臨床指引 2010年版, 國家衛生研究院 (2010/08/14 TAGO meeting in Taichung)
4. Jemal A, Siegel R, Ward E, et al. Cancer Statistics, 2006. CA Cancer J Clin 2006;56:106-130.
5. Edwards BK, Brown ML, Wingo PA, et al. Annual report to the nation on the status of cancer, 1975-2002, featuring populationbased trends in cancer treatment. J Natl Cancer Inst 2005;97:1407-1427.
6. Parkin DM, Bray F, Ferlay J. Global cancer statistics, 2002. CA Cancer J Clin 2005;55:74-108.
7. American College of Obstetricians and Gynecologists. ACOG practice bulletin. Diagnosis and treatment of cervical carcinomas. Number 35, May 2002. Int J Gynaecol Obstet 2002;78:79-91.
8. Chi DS. Laparoscopy in gynecologic malignancies. Oncology 1999;13:773-782.
9. Benedet JL, Bender H, Jones H 3rd, et al. FIGO staging classifications and clinical practice guidelines in the management of gynecologic cancers. FIGO Committee on Gynecologic Oncology. Int J Gynaecol Obstet 2000;70:209-262.
10. Haie-Meder C, Fervers B, Fondrinier E, et al. SOR guidelines for concomitant chemoradiotherapy for patients with uterine cervical cancers: evidence update bulletin 2004. Ann Oncol 2005;16:1100-1108.
11. Koliopoulos G, Sotiriadis A, Kyrgiou M, et al. Conservative surgical methods for FIGO stage IA2 squamous cervical carcinoma and their role in preserving women's fertility. Gynecol Oncol 2004;93:469-473.
12. Bernardini M, Barrett J, Seaward G, et al. Pregnancy outcomes in patients after radical trachelectomy. Am J Obstet Gynecol 2003;189:1378-1382. **(Trachelectomy 保留生育力 case series)**
13. Boss EA, van Golde RJ, Beerendonk CC, et al. Pregnancy after radical trachelectomy: A real option? Gynecol Oncol 2005;99:S152-6. Epub 2005 Sep 2. **(Trachelectomy 保留生育力 review)**
14. WT Creasman, RJ Zaino, FJ Major, PJ DiSaia, KD Hatch and HD Homesley, Early invasive carcinoma of the cervix (3 to 5 mm invasion): risk factors and prognosis: a Gynecologic Oncology Group study, Am J Obstet Gynecol **178** (1998), pp. 62–65. **(Cervical cancer stage IA2)**
15. WB Jones, GO Mercer, JL Lewis, SC Rubin and WJ Hoskins, Early invasive carcinoma of the cervix, Gynecol Oncol **51** (1993), pp. 26–32. **(Cervical cancer stage IA2)**
16. Landoni F, Maneo A, Colombo A, et al. Randomized study of radical surgery vs. radiotherapy for stage Ib-IIa cervical cancer. Lancet 1997;350:535-540. **(RH vs R/T)**
17. Keys HM, Bundy BN, Stehman FB, et al. Cisplatin, radiation, and adjuvant hysterectomy compared with radiation and adjuvant hysterectomy for bulky stage IB cervical carcinoma. N Engl J Med 1999;340:1154-1161. **(CCRT + Hysterectomy vs R/T + hysterectomy, IB2)**

References

18. Rose PG, M.D., Bundy BN, Watkins EB, et al. Concurrent Cisplatin-Based Radiotherapy and Chemotherapy for Locally Advanced Cervical Cancer. N Engl J Med 1999; 340:1144-1153. **(Cisplatin based CCRT for locally advanced Cx Ca)**
19. Morris M, Eifel PJ, Lu J, et al. Pelvic radiation with concurrent chemotherapy compared with pelvic and para-aortic radiation for high-risk cervical cancer. N Engl J Med 1999;340:1137-1143. **(Primary CCRT for locally advanced)**
20. Frederick B. Stehman, Shamshad Ali, Henry M. Keys et al, Radiation therapy with or without weekly cisplatin for bulky stage 1B cervical carcinoma: follow-up of a Gynecologic Oncology Group trial. American Journal of Obstetrics and Gynecology, Volume 197, Issue 5, November 2007, Pages 503.e1-503.e6 **(CCRT + hysterectomy vs RT +hysterectomy)**
21. Henry M. Keys, Brian N. Bundy, Frederick B. Stehman et al, Radiation therapy with and without extrafascial hysterectomy for bulky stage IB cervical carcinoma: a randomized trial of the Gynecologic Oncology Group. Gynecologic Oncology, Volume 89, Issue 3, June 2003, Pages 343-353. **(R/T + hysterectomy vs RT alone)**
22. Pierluigi Benedetti-Panici, Stefano Greggi, Alessandro Colombo et al. Neoadjuvant Chemotherapy and Radical Surgery Versus Exclusive Radiotherapy in Locally Advanced Squamous Cell Cervical Cancer: Results From the Italian Multicenter Randomized Study. JCO Jan 1 2002: 179-188. **(Neoadjuvant C/T + RH vs Pelvic RT in Locally advanced)**
23. Ting-Chang Chang, Chyong-Huey Lai, Ji-Hong Hong et al. Randomized trial of neoadjuvant cisplatin, vincristine, bleomycin, and radical hysterectomy versus radiation therapy for bulky stage IB and IIA cervical cancer. Journal of Clinical Oncology, Vol 18, Issue 8 (April), 2000: 1740-1747 **(Neoadjuvant C/T + RH vs Pelvic RT in Locally advanced)**
24. Sardi J, Sananes C, Giaroli A et al. Results of a prospective randomized trial with neoadjuvant chemotherapy in stage IB, bulky, squamous carcinoma of the cervix. Gynecol Oncol. 1993 May;49(2):156-65. **(Neoadjuvant C/T + RH)**
25. Juan E. Sardi, Adolfo Giaroli, Carlos Sananes et al. Long-Term Follow-up of the First Randomized Trial Using Neoadjuvant Chemotherapy in Stage Ib Squamous Carcinoma of the Cervix: The Final Results. Gynecologic Oncology, Volume 67, Issue 1, October 1997, Pages 61-69. **(Neoadjuvant C/T + RH這篇文章覺得加上NACT是有比較好)**
26. Gary L. Eddy, Brian N. Bundy, William T. Creasman et al. Treatment of (“bulky”) stage IB cervical cancer with or without neoadjuvant vincristine and cisplatin prior to radical hysterectomy and pelvic/para-aortic lymphadenectomy: A phase III trial of the gynecologic oncology group. Gynecologic Oncology, Volume 106, Issue 2, August 2007, Pages 362-369 **(Neoadjuvant C/T + RH vs RH 這篇文章覺得加上NACT沒有比較好)**

References

27. Cosin JA, Fowler JM, Chen MD et al. Pretreatment surgical staging of patients with cervical carcinoma: the case for lymph node debulking. *Cancer*. 1998 Jun 1;82(11):2241-8. **(先拿LN做Surgical staging對於locally advanced Cx Ca 的預後 有幫助的文章, n = 266)**
28. Lai CH, Huang KG, Hong JH, et al. Randomized trial of surgical staging (extraperitoneal or laparoscopic) versus clinical staging in locally advanced cervical cancer. *Gynecol Oncol*. 2003 Apr;89(1):160-7. **(先拿LN做Surgical staging對於locally advanced Cx Ca 的預後 沒有幫助的文章, n = 61, RCT)**
29. Peters WA 3rd, Liu PY, Barrett RJ 2nd, et al. Concurrent chemotherapy and pelvic radiation therapy compared with pelvic radiation therapy alone as adjuvant therapy after radical surgery in high-risk early-stage cancer of the cervix. *J Clin Oncol* 2000;18:1606-1613. **(RH 手術後加做CCRT的文章)**
30. Sedlis A, Bundy BN, Rotman MZ et al. A randomized trial of pelvic radiation therapy versus no further therapy in selected patients with stage IB carcinoma of the cervix after radical hysterectomy and pelvic lymphadenectomy: A Gynecologic Oncology Group Study. *Gynecol Oncol*. 1999 May;73(2):177-83 **(RH 手術後加做CCRT的文章)**
31. Perry W. Grigsby. 4th International Cervical Cancer Conference: update on PET and cervical cancer. *Gynecologic Oncology*, Volume 99, Issue 3, Supplement 1, December 2005, Pages S173-S175 **(PET對於子宮頸癌診斷的幫忙)**
32. Rose PG, Adler LP, Rodriguez M et al. Positron emission tomography for evaluating para-aortic nodal metastasis in locally advanced cervical cancer before surgical staging: a surgicopathologic study. *J Clin Oncol*. 1999 Jan;17(1):41-5 **(PET對於Para-aortic LN mets的術前診斷的幫忙)**
33. Chou HH, Chang TC, Yen TC et al. Low value of [18F]-fluoro-2-deoxy-D-glucose positron emission tomography in primary staging of early-stage cervical cancer before radical hysterectomy. *J Clin Oncol*. 2006 Jan 1;24(1):123-8 **(PET對於子宮頸癌術前診斷 沒有幫忙)**
34. Boughanim M, Leboulleux S, Rey A et al. Histologic results of para-aortic lymphadenectomy in patients treated for stage IB2/II cervical cancer with negative [18F]fluorodeoxyglucose positron emission tomography scans in the para-aortic area. *J Clin Oncol*. 2008 May 20;26(15):2558-61 **(PET對於Para-aortic LN mets的術前診斷到底有沒有幫忙)**
35. Chao A, Ho KC, Wang CC et al. Positron emission tomography in evaluating the feasibility of curative intent in cervical cancer patients with limited distant lymph node metastases. *Gynecol Oncol*. 2008 May 20. [Epub ahead of print] **(PET對於LN mets的術前診斷以及預後到底有沒有幫忙)**
36. Mayr NA, Taoka T, Yuh WT et al. Method and timing of tumor volume measurement for outcome prediction in cervical cancer using magnetic resonance imaging. *Int J Radiat Oncol Biol Phys*. 2002 Jan 1;52(1):14-22. **(MRI對於子宮頸癌診斷的幫忙)**

References

37. Ohara K, Tsunoda H, Satoh T et al. Use of the small pelvic field instead of the classic whole pelvic field in postoperative radiotherapy for cervical cancer: reduction of adverse events. *Int J Radiat Oncol Biol Phys.* 2004 Sep 1;60(1):258-64 (縮小放射線照射範圍 · 相較於全骨盆照射 · 是否可減低副作用)
38. Nobuhiro Takeshima, Kenji Umayahara, Kiyoshi Fujiwara et al. Treatment results of adjuvant chemotherapy after radical hysterectomy for intermediate- and high-risk stage IB–IIA cervical cancer. *Gynecologic Oncology*, Volume 103, Issue 2, November 2006, Pages 618-622 (術後化學治療對於子宮頸癌的高危險族群是否有幫助)
39. **GOG 110** : Omura GA, Blessing JA, Vaccarella L, et al: Randomized trial of cisplatin versus cisplatin plus mitolactol versus cisplatin plus ifosfamide in advanced squamous carcinoma of the cervix: A Gynecologic Oncology Group study. *J Clin Oncol* 15:165-171, 1997
40. **GOG 149** : Buxton E, Meanwell C, Hilton C, et al: Combination bleomycin, ifosfamide, and cisplatin chemotherapy in cervical cancer. *J Natl Cancer Inst* 81:359-361, 1989
41. **GOG 169** : Moore DH, Blessing JA, McQuellon RP, et al: Phase III study of cisplatin with or without paclitaxel in Stage IVB, recurrent or persistent squamous cell carcinoma of the cervix: A Gynecologic Oncology Group study. *J Clin Oncol* 22:3113-3119, 2004
42. **GOG 179** : Fiorica J, Holloway R, Ndubisi B, et al: Phase II trial of topotecan and cisplatin in persistent or recurrent squamous and nonsquamous carcinomas of the cervix. *Gynecol Oncol* 85:89-94, 2002
43. T Sugiyama, T Nishida, S Kumagai, et al. Combination therapy with irinotecan and cisplatin as neoadjuvant chemotherapy in locally advanced cervical cancer. *Br J Cancer.* 1999;81(1): 95–98.
44. Lee KB, Lee JM, Ki KD et al. Comparison of adjuvant chemotherapy and radiation in patients with intermediate risk factors after radical surgery in FIGO stage IB-IIA cervical cancer. *Int J Gynecol Cancer.* 2008 Sep-Oct;18(5):1027-31.
45. Rosa DD, Medeiros LR, Edelweiss MI, et al. Adjuvant platinum-based chemotherapy for early stage cervical cancer. *Cochrane Database Syst Rev.* 2009 Jul 8;(3):CD005342
46. Ryzewska L, Tierney J, Vale CL et al. Neoadjuvant chemotherapy plus surgery versus surgery for cervical cancer. *Cochrane Database Syst Rev.* 2010 Jan 20;(1):CD007406.
47. Matsumura M, Takeshima N, Ota T et al. Neoadjuvant chemotherapy followed by radical hysterectomy plus postoperative chemotherapy but no radiotherapy for Stage IB2-IIB cervical cancer-Irinotecan and platinum chemotherapy. *Gynecol Oncol.* 2010 Aug 13. [Epub ahead of print]

References

48. Buda A, Dell'Anna T, Signorelli M, et al. Role of ifosfamide in cervical cancer: an overview, *Oncology*. 2003;65 Suppl 2:63-6.
49. Kumar JV, Doval DC, Rao R, Rawal S. et al. A retrospective study of patients with locally advanced cancer of the cervix treated with neoadjuvant chemotherapy followed by radical surgery. *Int J Gynecol Cancer*. 2009 Apr;19(3):417-22.
50. Alexander Sedlis, Brian N. Bundy, Marvin Z. Rotman, et al A Randomized Trial of Pelvic Radiation Therapy versus No Further Therapy in Selected Patients with Stage IB Carcinoma of the Cervix after Radical Hysterectomy and Pelvic Lymphadenectomy: A Gynecologic Oncology Group Study. *Gynecologic Oncology* 73; 177–183, 1999
51. Bradley J. Monk, Michael W. Sill, D. Scott McMeekin , et al Phase III Trial of Four Cisplatin-Containing Doublet Combinations in Stage IVB, Recurrent, or Persistent Cervical Carcinoma: A Gynecologic Oncology Group Study. *J Clin Oncol* 27:4649-4655, 2009
52. Haie-Meder C, Morice P, Castiglione M; **ESMO Guidelines Working Group**. **Cervical cancer: ESMO Clinical Practice Guidelines for diagnosis, treatment and follow-up**. *Ann Oncol*. 2010 May;21 Suppl 5:v37-40. No abstract available.
53. McCann GA, Boutsicaris CE, Preston MM, et al Neuroendocrine carcinoma of the uterine cervix: the role of multimodality therapy in early-stage disease. *Gynecologic Oncology* 129(1):135-9, 2013
54. Cohen JG, Kapp DS, Shin JY , et al Small cell carcinoma of the cervix: treatment and survival outcomes of 188 patients. *Am J Obstet Gynecol*. 203(4):347.e1-6, 2010
55. Tewari KS, Sill MW, Long HJ 3rd, et al. Improved survival with bevacizumab in advanced cervical cancer. *N Engl J Med*. 2014;370(8):734–743. •• Pivotal phase III trial that demonstrated an improvement in OS by adding bevacizumab to chemotherapy in patients with persistent, recurrent, and metastatic cervical cancer, with subsequent FDA approval for these patients.
56. Delgado G1, Bundy B, Zaino R, Sevin BU, Creasman WT, Major F. Prospective surgical-pathological study of disease-free interval in patients with stage IB squamous cell carcinoma of the cervix: a Gynecologic Oncology Group study. *Gynecol Oncol*. 1990 Sep;38(3):352-7.
57. Rotman M1, Sedlis A, Piedmonte MR, Bundy B, Lentz SS, Muderspach LI, Zaino RJ. A phase III randomized trial of postoperative pelvic irradiation in Stage IB cervical carcinoma with poor prognostic features: follow-up of a gynecologic oncology group study. *Int J Radiat Oncol Biol Phys*. 2006 May 1;65(1):169-76.
58. Vera Loizzi, Vittoria Del Vecchio, Francesco M. Crupano, Valentina Minicucci, Valeria V. Fumarulo, Leonardo Resta, Antonella Vimercati, Stefano Bettocchi, Ettore Cicinelli & Gennaro Cormio. A phase II study: dose-dense carboplatin and paclitaxel as neoadjuvant chemotherapy in locally advanced cervical cancer. *Journal of Chemotherapy* 2018 VOL. 30 NO. 4

References

59. Frenel JS, Le Tourneau C, O'Neil B, Ott PA, Piha-Paul SA, Gomez-Roca C, van Brummelen EMJ, Rugo HS, Thomas S, Saraf S, Rangwala R, Varga A. Safety and Efficacy of Pembrolizumab in Advanced, Programmed Death Ligand 1-Positive Cervical Cancer: Results From the Phase Ib KEYNOTE-028 Trial. *J Clin Oncol*. 2017 Dec 20;35(36):4035-4041.
60. Hyun Cheol Chung, Jan H. M. Schellens, Jean-Pierre Delord, Ruth Perets, Antoine Italiano, Ronnie Shapira-Frommer, et al. Pembrolizumab treatment of advanced cervical cancer: Updated results from the phase 2 KEYNOTE-158 study. *J Clin Oncol*. 2018(36)
61. Chia-Jung Hsieh, Mun-Kun Hong, Pau-Chung Chen, Jen-Hung Wang and Tang-Yuan Chu. Antiestrogen use reduces risk of cervical neoplasia in breast cancer patients:a population-based study. *Oncotarget*,2017,VOL. 8, (No.17), pp:29361-29369.
62. Gabriella Ferrandina, Franco O. Ranelletti, Luigi M. Larocca, Nicola Maggiano, Erika Fruscella, Francesco Legge, Giuseppe Santeusano, Alessandro Bombonati, Salvatore Mancuso, and Giovanni Scambia. Tamoxifen Modulates the Expression of Ki67, Apoptosis, and Microvessel Density in Cervical Cancer. *Clinical Cancer Research*. Vol. 7, 2656-2661, September 2001.
63. Frumovitz M, Munsell MF, Burzawa JK, Byers LA, Ramalingam P, Brown J, Coleman RL. Combination therapy with topotecan, paclitaxel, and bevacizumab improves progression-free survival in recurrent small cell neuroendocrine carcinoma of the cervix. *Gynecol Oncol*. 2017 Jan;144(1):46-50.
64. Marabelle, Aurelien; Le, Dung T.; Ascierto, Paolo A.; Di Giacomo, Anna Maria; De Jesus-Acosta, Ana; Delord, Jean-Pierre; Geva, Ravit; Gottfried, Maya; Penel, Nicolas; Hansen, Aaron R.; Piha-Paul, Sarina A.; Doi, Toshihiko; Gao, Bo; Chung, Hyun Cheol; Lopez-Martin, Jose; Bang, Yung-Jue; Frommer, Ronnie Shapira; Shah, Manisha; Gori, Razi; Joe, Andrew K.; Pruitt, Scott K.; Diaz Jr, Luis A. Efficacy of Pembrolizumab in Patients With Noncolorectal High Microsatellite Instability/ Mismatch Repair–Deficient Cancer: Results From the Phase II KEYNOTE-158 Study. *J Clin Oncol*. 2020 Jan 1;38(1):1-10
65. Colombo N, Dubot C, Lorusso D, Caceres MV, Hasegawa K, Shapira-Frommer R, Tewari KS, Salman P, Hoyos Usta E, Yañez E, Gümüş M, Olivera Hurtado de Mendoza M, Samouëlian V, Castonguay V, Arkhipov A, Toker S, Li K, Keefe SM, Monk BJ; KEYNOTE-826 Investigators. Pembrolizumab for Persistent, Recurrent, or Metastatic Cervical Cancer. *N Engl J Med*. 2021 Nov 11;385(20):1856-1867.
66. Naumann, R. W., Hollebecque, A., Meyer, T., Devlin, M. J., Oaknin, A., Kerger, J., López-Picazo, J. M., Machiels, J. P., Delord, J. P., Evans, T., Boni, V., Calvo, E., Topalian, S. L., Chen, T., Soumaoro, I., Li, B., Gu, J., Zwirter, R., & Moore, K. N. (2019). Safety and Efficacy of Nivolumab Monotherapy in Recurrent or Metastatic Cervical, Vaginal, or Vulvar Carcinoma: Results From the Phase I/II CheckMate 358 Trial. *Journal of clinical oncology : official journal of the American Society of Clinical Oncology*, 37(31), 2825–2834.

References

67. Verschraegen, C. F., Levy, T., Kudelka, A. P., Llerena, E., Ende, K., Freedman, R. S., Edwards, C. L., Hord, M., Steger, M., Kaplan, A. L., Kieback, D., Fishman, A., & Kavanagh, J. J. (1997). Phase II study of irinotecan in prior chemotherapy-treated squamous cell carcinoma of the cervix. *Journal of clinical oncology : official journal of the American Society of Clinical Oncology*, 15(2), 625–631.